Settings

1 2 3 4 5 6 7 8 9 10 11 12 13 14 15 16 17 18 19 20 21 22 23 24 25 26 27 28 29 30

Item 1 of 40
Question Id: 15028

Mark | Previous | Next | Full Screen | Tutorial | Lab Values | Notes | Calculator | Reverse Color | Text Zoom | Settings

A 7-year-old boy is brought to the office for evaluation of a neck mass. A week ago, the patient was taken to an urgent care clinic for nasal congestion and sore throat. The symptoms resolved after a few days, but his parents noticed a persistent neck swelling. The patient has no prior medical conditions, and his immunizations are up to date. On physical examination, he appears well and is well nourished. Neck examination shows a mildly tender, 2-cm, midline mass that moves up when the patient swallows. Which of the following is the most likely cause of this patient's lesion?

- A. Abnormal migration of neural crest cells
- B. Cervical implantation of thymic tissue
- C. Dilation of cervical lymphatic channels
- D. Incomplete obliteration of a duct
- E. Persistence of second branchial arch structures
- F. Trapping of skin structures along embryonic fusion lines

Submit

Block Time Remaining: 00:00:03
TUTOR

0 | Feedback | Suspend | End Block

A 7-year-old boy is brought to the office for evaluation of a neck mass. A week ago, the patient was taken to an urgent care clinic for nasal congestion and sore throat. The symptoms resolved after a few days, but his parents noticed a persistent neck swelling. The patient has no prior medical conditions, and his immunizations are up to date. On physical examination, he appears well and is well nourished. Neck examination shows a mildly tender, 2-cm, midline mass that moves up when the patient swallows. Which of the following is the most likely cause of this patient's lesion?

- A. Abnormal migration of neural crest cells (7%)
- B. Cervical implantation of thymic tissue (8%)
- C. Dilation of cervical lymphatic channels (4%)
- ✓ D. Incomplete obliteration of a duct (70%)
- E. Persistence of second branchial arch structures (7%)
- F. Trapping of skin structures along embryonic fusion lines (0%)

Omitted
Correct answer
D

70%
Answered correctly

04 secs
Time Spent

05/06/2020
Last Updated

Explanation

Thyroglossal duct cyst

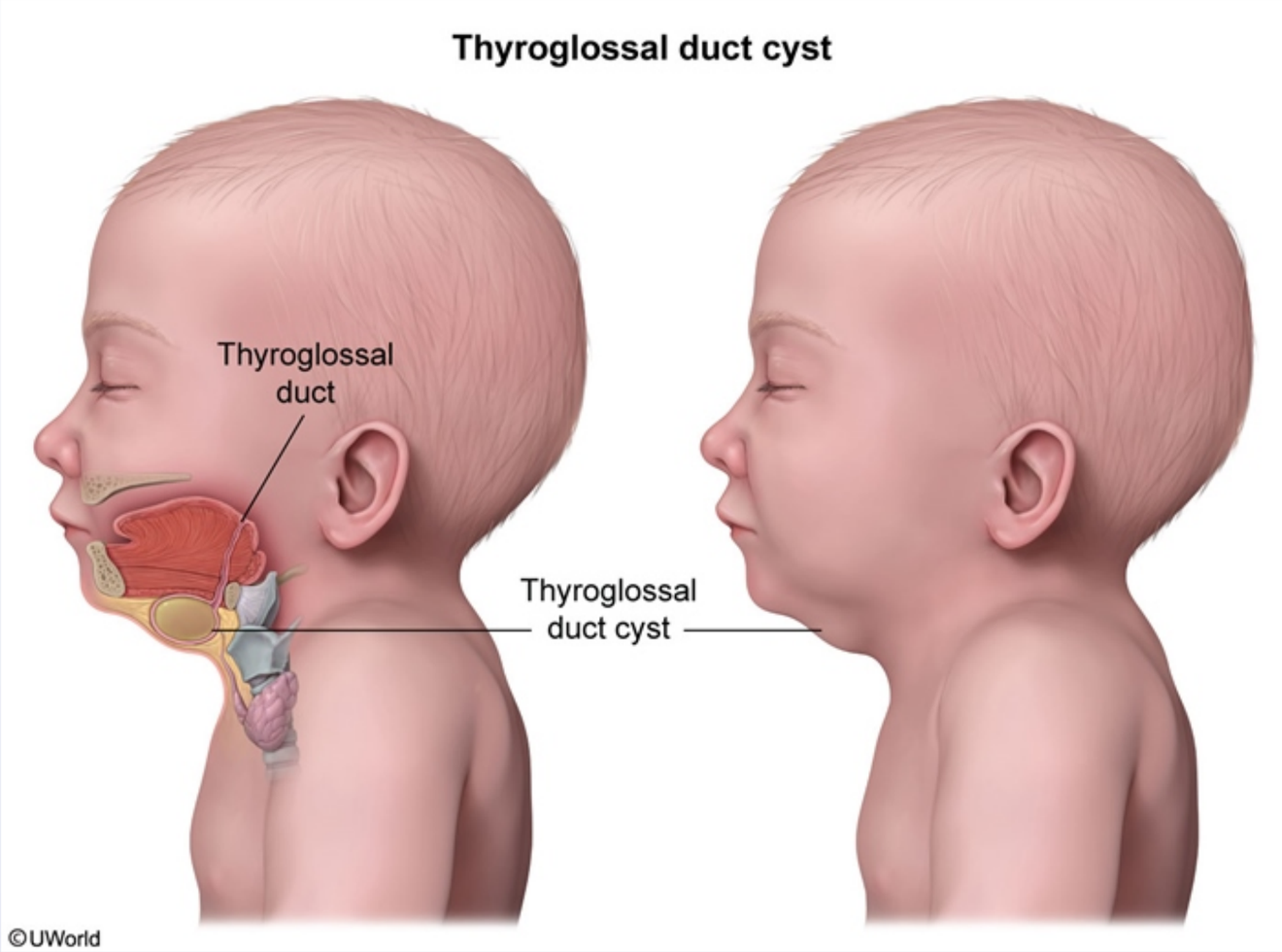

This patient has a **thyroglossal duct cyst** (TDC), which presents as a **midline mass** that characteristically **moves superiorly** with protrusion of the tongue or swallowing. A TDC is often detected when it becomes secondarily infected after an upper respiratory tract infection, leading to

This patient has a **thyroglossal duct cyst** (TDC), which presents as a **midline mass** that characteristically **moves superiorly** with protrusion of the tongue or swallowing. A TDC is often detected when it becomes secondarily infected after an upper respiratory tract infection, leading to erythema and tenderness. It may also be noted incidentally during evaluation of throat or neck symptoms.

The **thyroid gland** is formed as an outpouching from the pharyngeal epithelium at the base of the tongue. It then descends to the base of the anterior neck via the thyroglossal duct, which extends from the foramen cecum on the dorsal surface of the tongue to the superior border of the thyroid isthmus. If the duct fails to atrophy normally, a TDC can develop from the epithelial remnants within the duct. Because the tract connects to the base of the tongue, protrusion or swallowing causes the TDC to move superiorly. Ectopic thyroid tissue may also form and can reside anywhere along the thyroglossal duct's path.

(Choice A) A paraganglioma is a neuroendocrine tumor that arises from extraadrenal, autonomic paraganglia (eg, carotid body paraganglia) due to the abnormal migration of neural crest cells. Carotid body paragangliomas typically present as lateral neck masses.

(Choice B) Cervical implantation of thymic tissue can result in ectopic thymic cysts, which are rare lesions that may develop along the descent of the thymus (angle of the jaw to the mediastinum). They are typically unilateral (left more often than right) rather than midline.

(Choice C) A cystic hygroma results from abnormal lymphatic development, leading to dilated lymphatic vessels. It presents at birth as a soft mass at the posterior base or lateral aspect of the neck. It would not typically be at the midline or rise with swallowing.

(Choice E) A branchial cleft cyst is an embryologic remnant of branchial arch structures that presents as a lateral (rather than midline) neck mass. A sinus tract or fistula may also be present.

(Choice F) Trapping of skin structures (eg, hair follicles, sebaceous glands) along embryonic fusion lines results in the formation of a dermoid cyst within the subcutaneous tissue. It presents as a midline neck mass but, in contrast to this patient's neck mass, does not move with tongue protrusion or swallowing.

Educational objective:
Thyroglossal duct cysts form from epithelial remnants of the thyroglossal duct along the path of thyroid descent. They present as midline masses that rise with swallowing or tongue protrusion.

(Choice A) A paraganglioma is a neuroendocrine tumor that arises from extraadrenal, autonomic paraganglia (eg, carotid body paraganglia) due to the abnormal migration of neural crest cells. Carotid body paragangliomas typically present as lateral neck masses.

(Choice B) Cervical implantation of thymic tissue can result in ectopic thymic cysts, which are rare lesions that may develop along the descent of the thymus (angle of the jaw to the mediastinum). They are typically unilateral (left more often than right) rather than midline.

(Choice C) A cystic hygroma results from abnormal lymphatic development, leading to dilated lymphatic vessels. It presents at birth as a soft mass at the posterior base or lateral aspect of the neck. It would not typically be at the midline or rise with swallowing.

(Choice E) A branchial cleft cyst is an embryologic remnant of branchial arch structures that presents as a lateral (rather than midline) neck mass. A sinus tract or fistula may also be present.

(Choice F) Trapping of skin structures (eg, hair follicles, sebaceous glands) along embryonic fusion lines results in the formation of a dermoid cyst within the subcutaneous tissue. It presents as a midline neck mass but, in contrast to this patient's neck mass, does not move with tongue protrusion or swallowing.

Educational objective:
Thyroglossal duct cysts form from epithelial remnants of the thyroglossal duct along the path of thyroid descent. They present as midline masses that rise with swallowing or tongue protrusion.

References

- Thyroglossal duct cysts: anatomy, embryology and treatment.
- Congenital cystic lesions of the head and neck.
- Congenital cystic neck masses: embryology and imaging appearances, with clinicopathological correlation.

Embryology	Ear, Nose & Throat (ENT)	Thyroglossal duct cyst
Subject	System	Topic

Copyright © UWorld. All rights reserved.

Settings

1 2 3 4 5 6 7 8 9 10 11 12 13 14 15 16 17 18 19 20 21 22 23 24 25 26 27 28 29 30

Item 1 of 40
Question Id: 15028

Mark | Previous | Next | Full Screen | Tutorial | Lab Values | Notes | Calculator | Reverse Color | Text Zoom | Settings

Exhibit Display

Thyroid migration

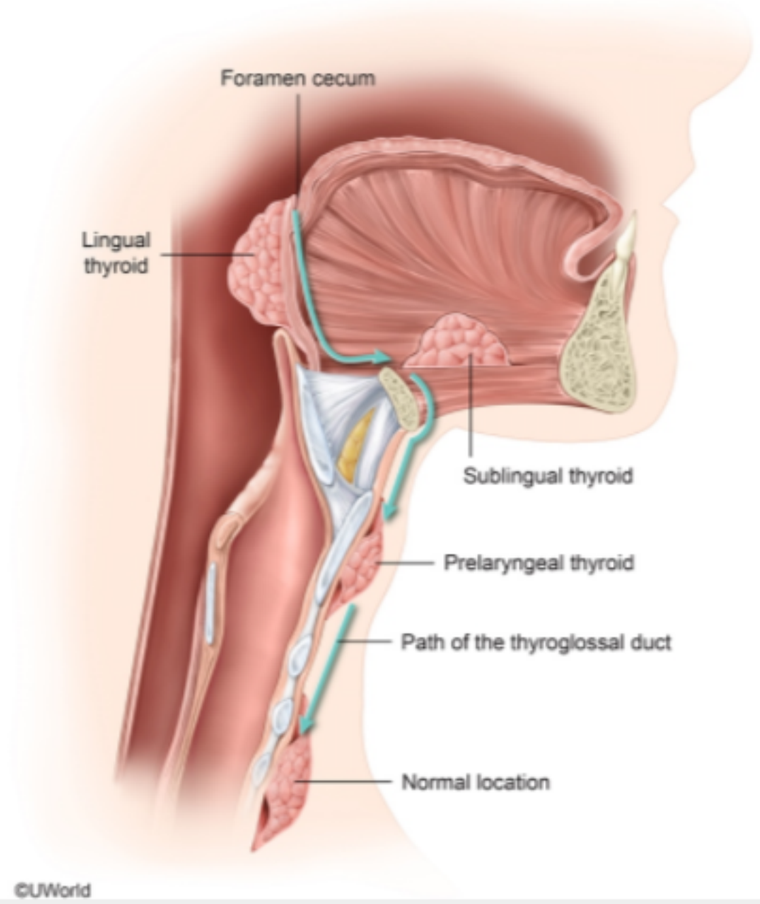

Zoom In | Zoom Out | Reset | Add To Flash Card

(Choice C) A cystic hygroma results from abnormal lymphatic development, leading to dilated lymphatic vessels. It presents at birth as a soft

Block Time Remaining: 00:00:04
TUTOR

0 | Feedback | Suspend | End Block

(Choice A) A paraganglioma is a neuroendocrine tumor that arises from extraadrenal, autonomic paraganglia (eg, carotid body paraganglia) due

Exhibit Display

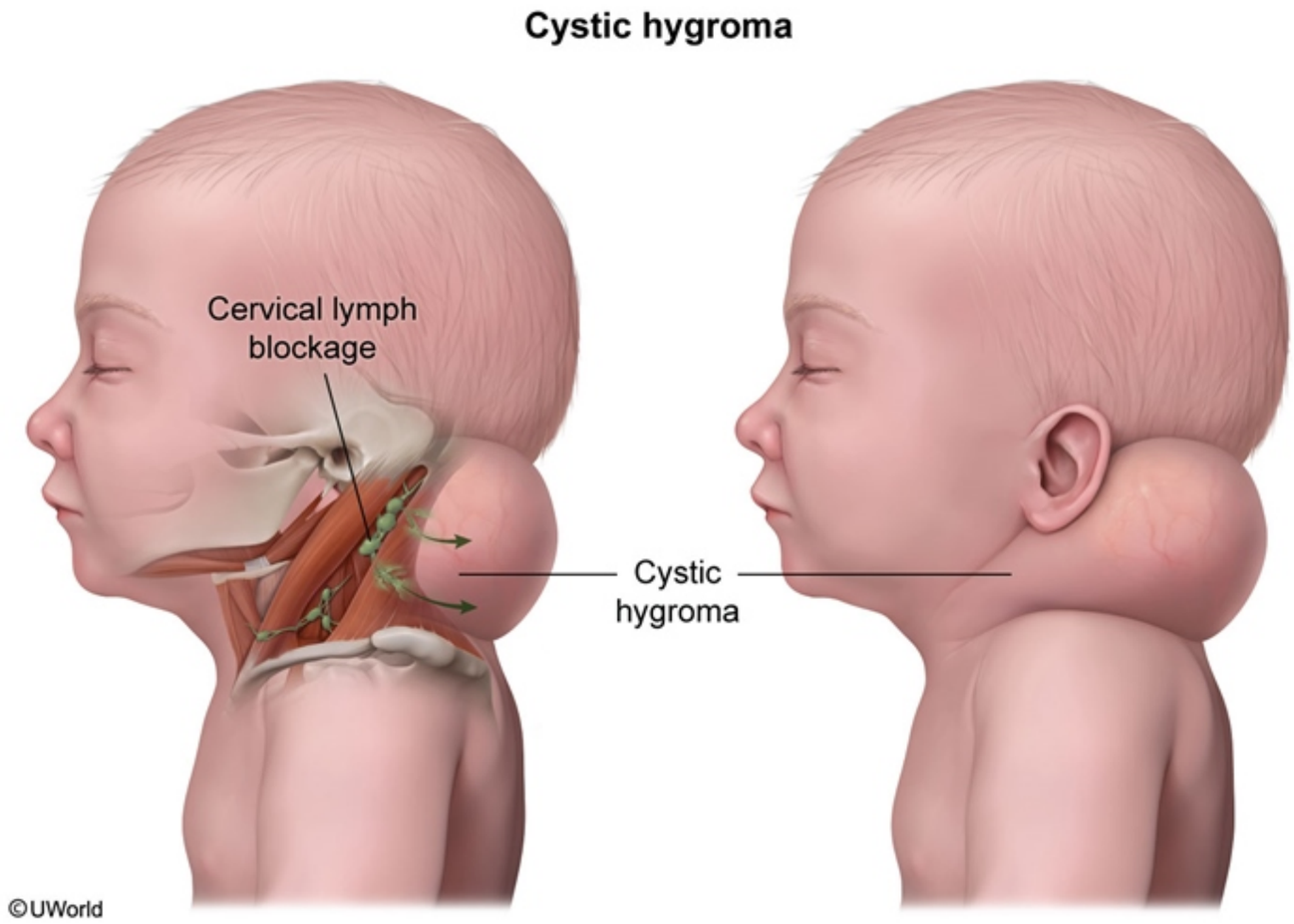

Zoom In | Zoom Out | Reset | Add To Flash Card

(Choice A) A paraganglioma is a neuroendocrine tumor that arises from extraadrenal, autonomic paraganglia (eg, carotid body paraganglia) due

Exhibit Display

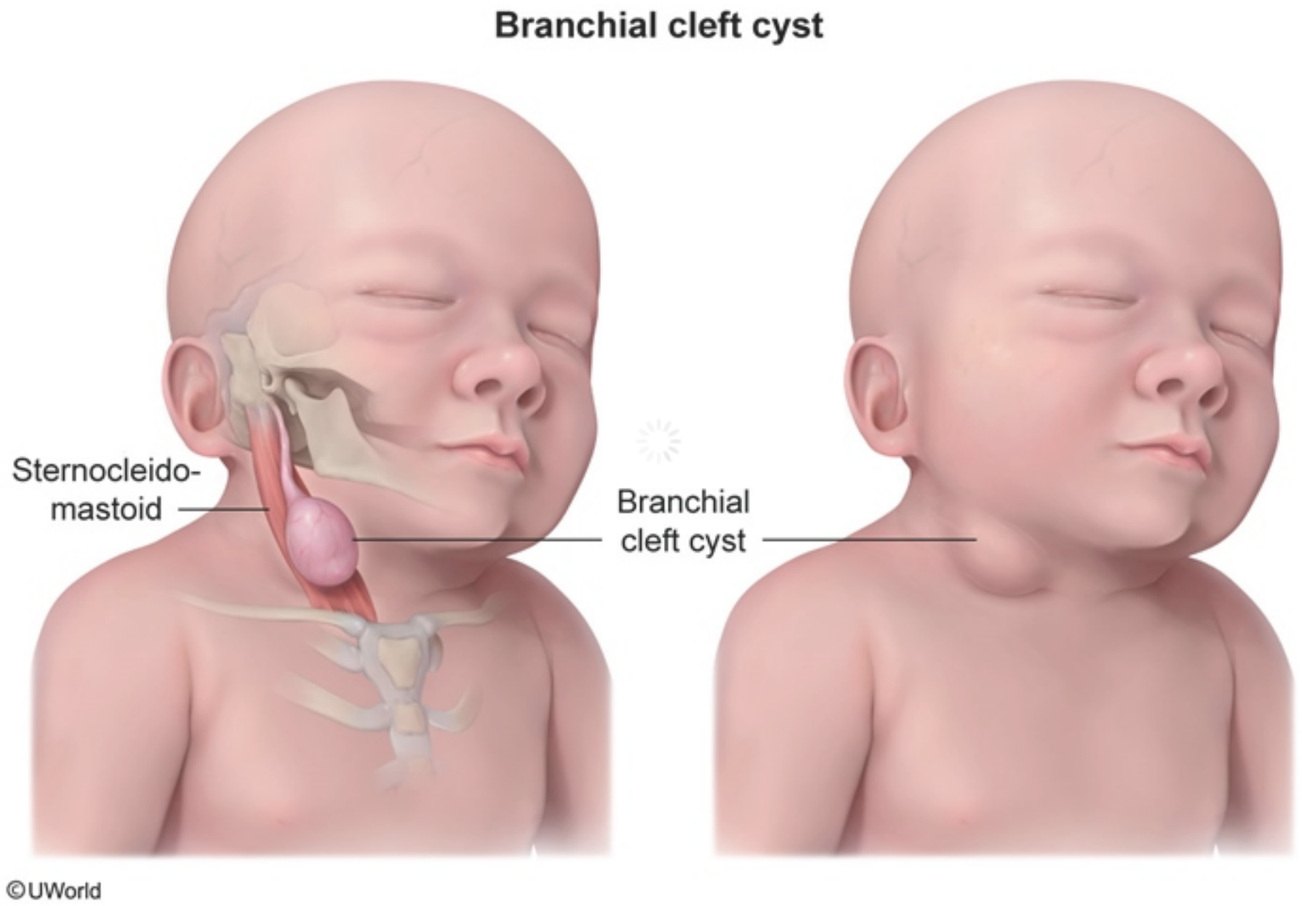

Zoom In Zoom Out Reset Add To Flash Card

Settings

1 2 3 4 5 6 7 8 9 10 11 12 13 14 15 16 17 18 19 20 21 22 23 24 25 26 27 28 29 30

Item 1 of 40
Question Id: 15028

Mark | Previous | Next | Full Screen | Tutorial | Lab Values | Notes | Calculator | Reverse Color | Text Zoom | Settings

(Choice A) A paraganglioma is a neuroendocrine tumor that arises from extraadrenal, autonomic paraganglia (eg, carotid body paraganglia) due

Exhibit Display

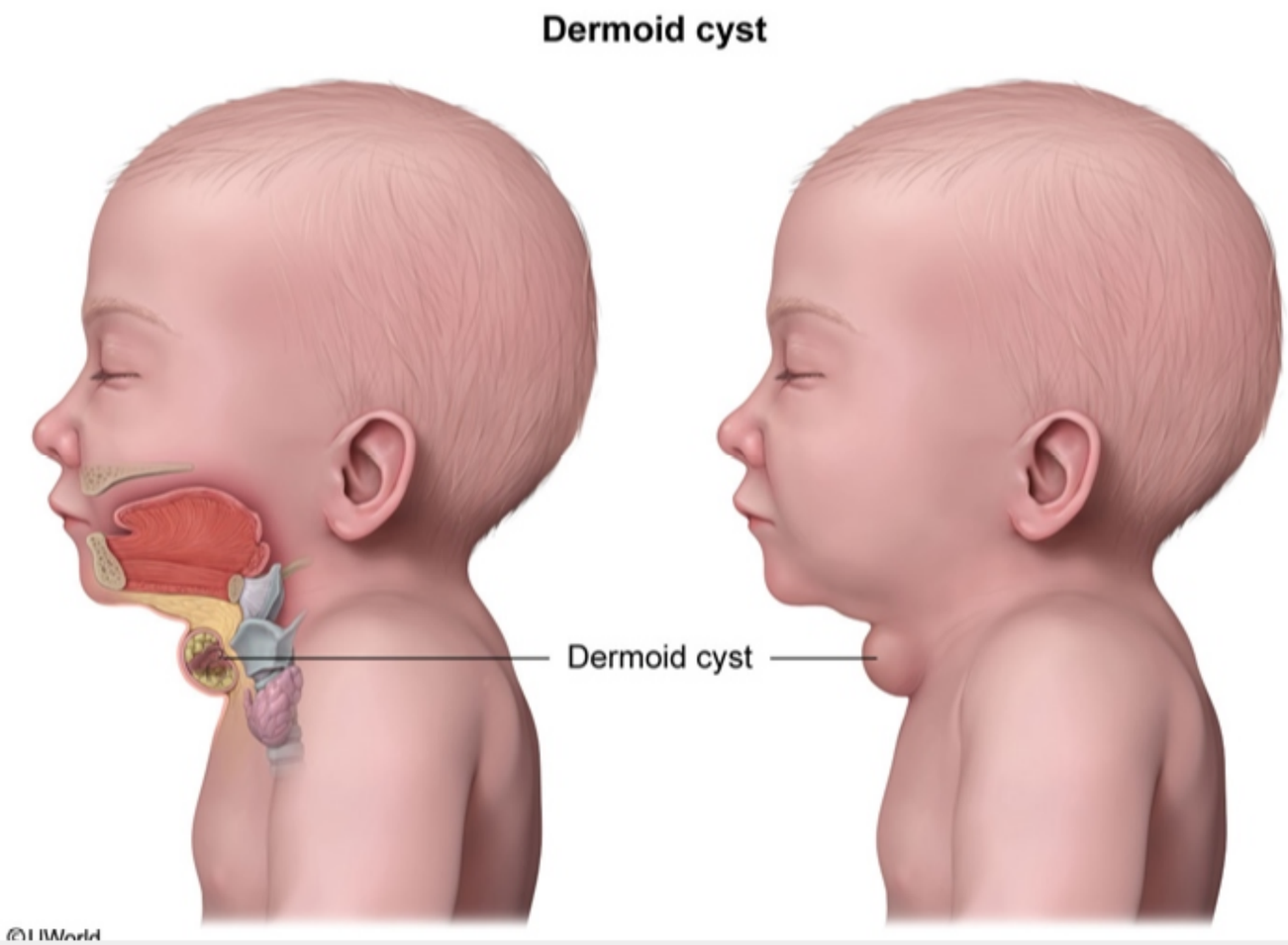

Zoom In | Zoom Out | Reset | Add To Flash Card

Block Time Remaining: 00:00:04
TUTOR

0 | Feedback | Suspend | End Block

A 4-hour-old girl with a cleft lip is breastfeeding without difficulty. The infant was born vaginally after an uncomplicated pregnancy and delivery. Routine antenatal sonography at 20 weeks gestation showed no abnormalities. Physical examination shows an intact palate and a unilateral cleft lip on the left side. No other abnormalities are seen. This child's cleft lip resulted from failure of which of the following intrauterine processes?

A. Fusion of the 2 medial nasal prominences

B. Fusion of the maxillary prominence and intermaxillary segment

C. Fusion of the palatal processes

D. Hyperplasia of the frontonasal prominence

E. Hypoplasia of the mandibular prominence

Submit

A 4-hour-old girl with a cleft lip is breastfeeding without difficulty. The infant was born vaginally after an uncomplicated pregnancy and delivery. Routine antenatal sonography at 20 weeks gestation showed no abnormalities. Physical examination shows an intact palate and a unilateral cleft lip on the left side. No other abnormalities are seen. This child's cleft lip resulted from failure of which of the following intrauterine processes?

- A. Fusion of the 2 medial nasal prominences (33%)
- ✓ B. Fusion of the maxillary prominence and intermaxillary segment (59%)
- C. Fusion of the palatal processes (5%)
- D. Hyperplasia of the frontonasal prominence (1%)
- E. Hypoplasia of the mandibular prominence (1%)

Omitted
Correct answer
B

59%
Answered correctly

02 secs
Time Spent

04/04/2020
Last Updated

Explanation



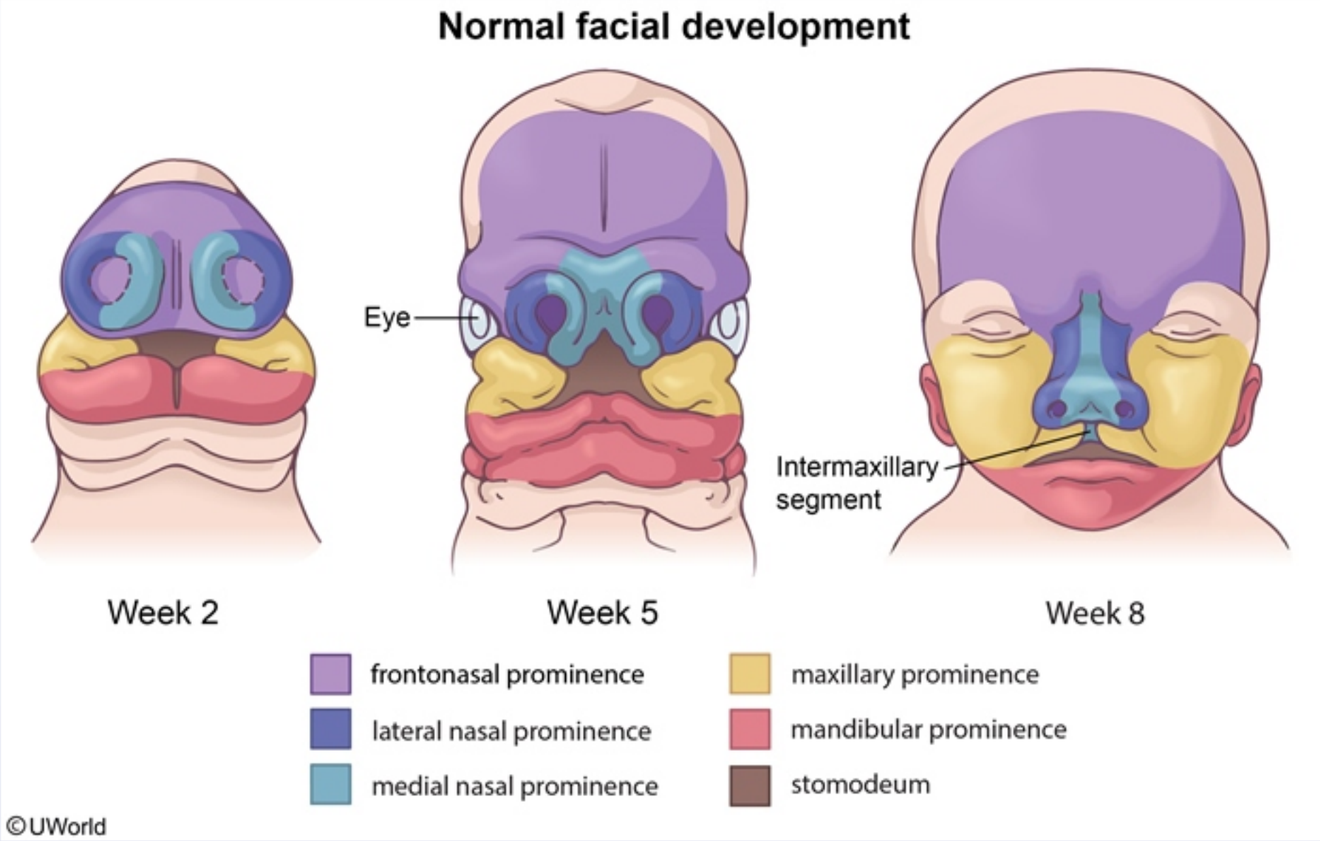

The lip and palate form during the **fifth-sixth week** of embryonic development through a series of fusions:

1. The first pharyngeal arch splits into the upper maxillary prominence and the lower mandibular prominence.
2. Fusion of the 2 medial nasal prominences forms the midline **intermaxillary segment**. The intermaxillary segment will become the philtrum of the upper lip, the 4 medial maxillary teeth, and the primary palate.
3. The left and right maxillary prominences then fuse with the midline intermaxillary segment to form the **upper lip** and **primary palate**. If one

The lip and palate form during the **fifth-sixth week** of embryonic development through a series of fusions:

1. The first pharyngeal arch splits into the upper maxillary prominence and the lower mandibular prominence.
2. Fusion of the 2 medial nasal prominences forms the midline **intermaxillary segment**. The intermaxillary segment will become the philtrum of the upper lip, the 4 medial maxillary teeth, and the primary palate.
3. The left and right maxillary prominences then fuse with the midline intermaxillary segment to form the **upper lip** and **primary palate**. If one of the maxillary prominences fails to fuse with the intermaxillary segment, a unilateral cleft lip results. If both maxillary prominences fail to fuse with the intermaxillary segment, bilateral cleft lip results.

(Choice A) Failure of the medial nasal prominence to fuse and form the intermaxillary segment is associated with severe midline defects, such as holoprosencephaly.

(Choice C) During the seventh-eighth week of embryonic development, the maxillary prominences give rise to palatine shelves. The thin sheets of tissue that comprise the palatine shelves grow medially and fuse into the **secondary palate**. Fusion of the secondary palate with the posterior aspect of the primary palate forms the complete palate. Failure of any of these processes can lead to **cleft palate**. The presence of a cleft lip increases the risk of cleft palate, but either can occur in isolation.

(Choice D) The orbits normally arise from the sides of the face and rotate medially. However, excessive tissue from the frontal nasal prominence could result in orbital hypertelorism (wide-set eyes) in addition to a broad forehead and wide nasal bridge.

(Choice E) Micrognathia is characterized by hypoplasia of the mandibular prominence. In Pierre-Robin sequence, the severe micrognathia results in posterior displacement of the tongue (glossoptosis) and prevents fusion of the secondary palate (cleft palate).

Educational objective:
Cleft lip results when the maxillary prominence fails to fuse with the intermaxillary segment during the fifth-sixth week of embryonic development. Cleft palate occurs when the palatine shelves fail to fuse with one another or with the primary palate. Cleft lip and palate can occur together or in isolation.

References

- Cleft lip and palate: understanding genetic and environmental influences.

fuse with the intermaxillary segment, bilateral cleft lip results.

(Choice A) Failure of the medial nasal prominence to fuse and form the intermaxillary segment is associated with severe midline defects, such as holoprosencephaly.

(Choice C) During the seventh-eighth week of embryonic development, the maxillary prominences give rise to palatine shelves. The thin sheets of tissue that comprise the palatine shelves grow medially and fuse into the **secondary palate**. Fusion of the secondary palate with the posterior aspect of the primary palate forms the complete palate. Failure of any of these processes can lead to **cleft palate**. The presence of a cleft lip increases the risk of cleft palate, but either can occur in isolation.

(Choice D) The orbits normally arise from the sides of the face and rotate medially. However, excessive tissue from the frontal nasal prominence could result in orbital hypertelorism (wide-set eyes) in addition to a broad forehead and wide nasal bridge.

(Choice E) Micrognathia is characterized by hypoplasia of the mandibular prominence. In Pierre-Robin sequence, the severe micrognathia results in posterior displacement of the tongue (glossoptosis) and prevents fusion of the secondary palate (cleft palate).

Educational objective:
Cleft lip results when the maxillary prominence fails to fuse with the intermaxillary segment during the fifth-sixth week of embryonic development. Cleft palate occurs when the palatine shelves fail to fuse with one another or with the primary palate. Cleft lip and palate can occur together or in isolation.

References

- Cleft lip and palate: understanding genetic and environmental influences.
- Cleft lip and palate: an evidence-based review.

Embryology	Ear, Nose & Throat (ENT)	Cleft lip and cleft palate
Subject	System	Topic

Copyright © UWorld. All rights reserved.

Exhibit Display

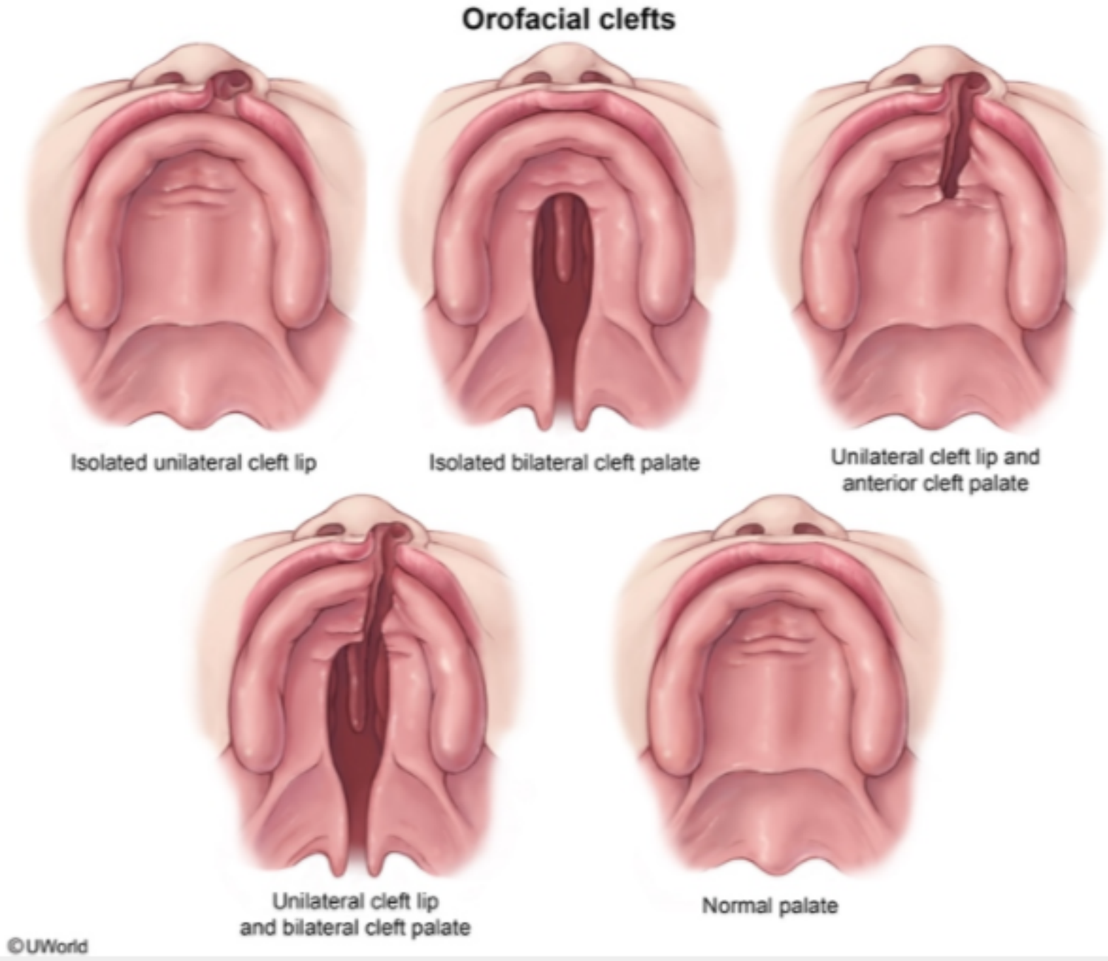

Zoom In | Zoom Out | Reset | Add To New Card | Existing Card

results in posterior displacement of the tongue (glossoptosis) and prevents fusion of the secondary palate (cleft palate).

Exhibit Display

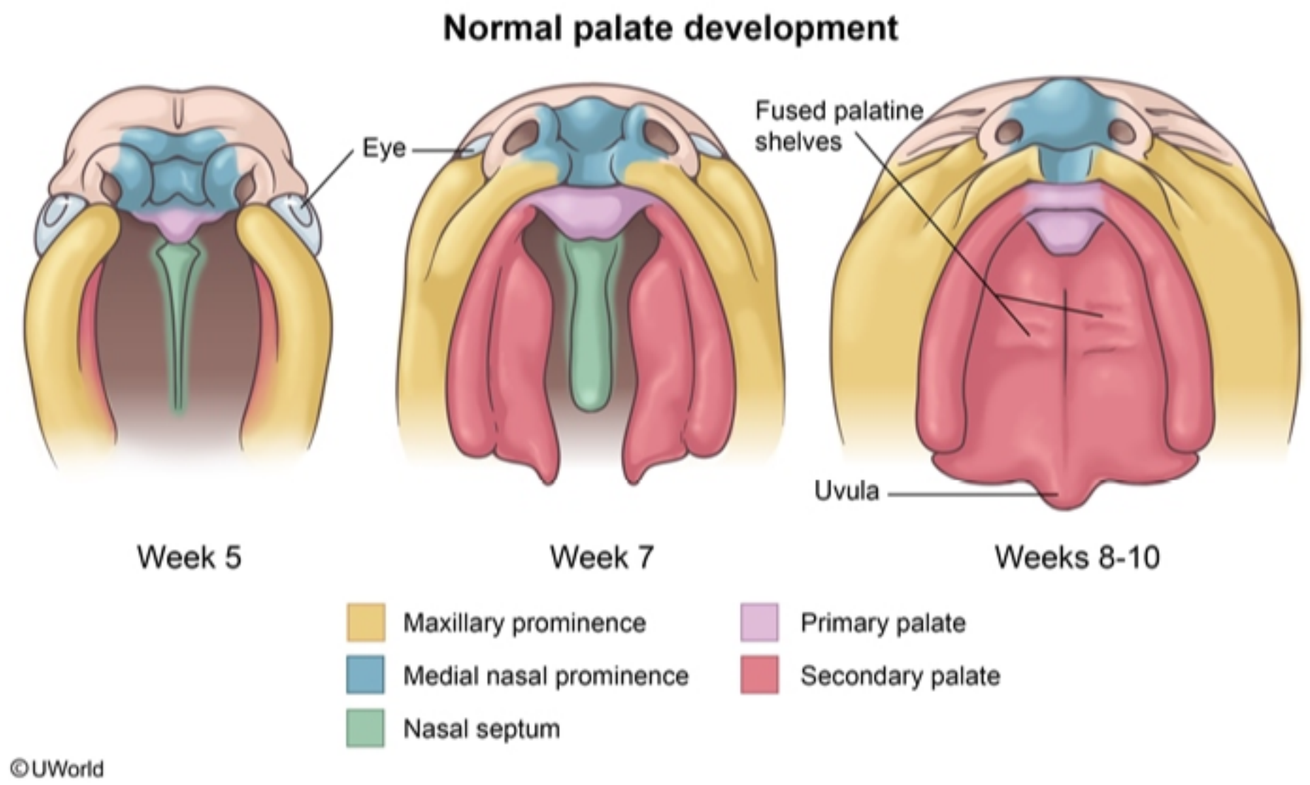

Zoom In | Zoom Out | Reset | Add To New Card | Existing Card

results in posterior displacement of the tongue (glossoptosis) and prevents fusion of the secondary palate (cleft palate).

Exhibit Display

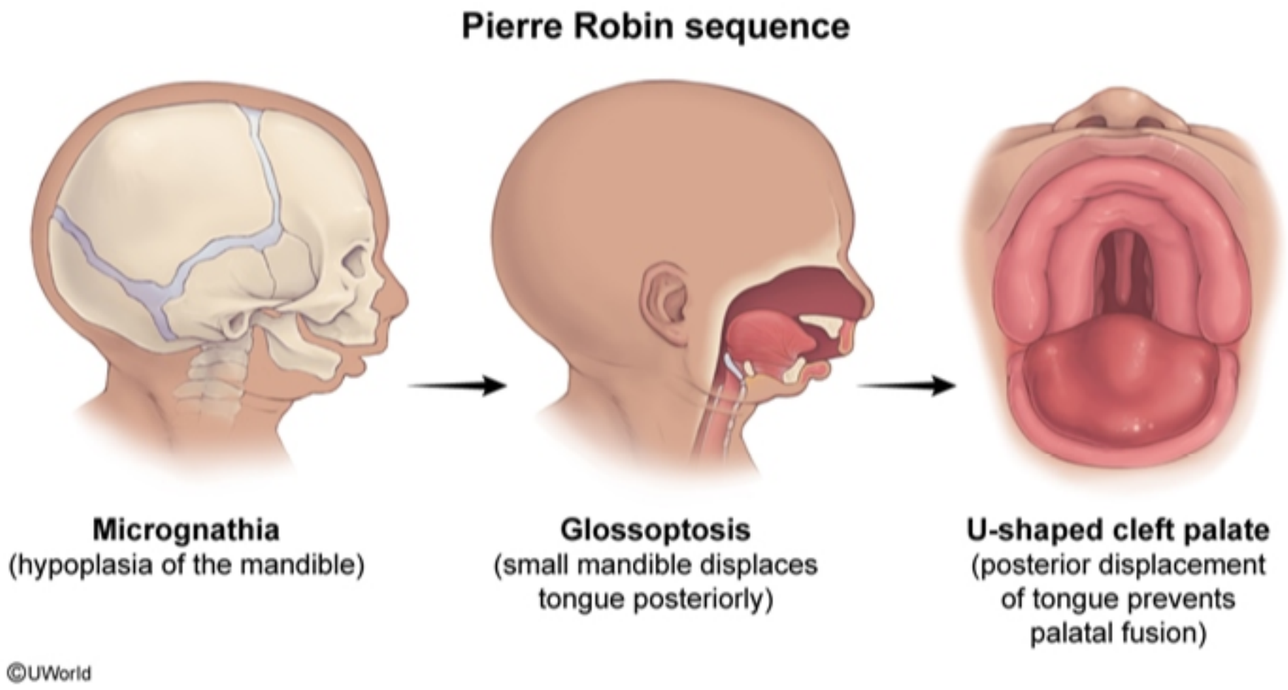

Zoom In | Zoom Out | Reset | Add To New Card | Existing Card

A 24-year-old woman comes to the office for a routine antenatal ultrasound. She is 19 weeks pregnant by her last menstrual period. This is the patient's third pregnancy, and there have been no complications. Her family history is unremarkable, and both of her children are healthy. The ultrasound reveals a male fetus with bilaterally enlarged fetal kidneys with diffuse small cysts. The amniotic fluid volume is very low. No other anomalies are seen. Which of the following will most likely be present in the newborn after delivery?

A. Bladder distension

B. Cerebral aneurysm

C. Hypertension

D. Respiratory distress

E. Vertebral anomalies

Submit

A 24-year-old woman comes to the office for a routine antenatal ultrasound. She is 19 weeks pregnant by her last menstrual period. This is the patient's third pregnancy, and there have been no complications. Her family history is unremarkable, and both of her children are healthy. The ultrasound reveals a male fetus with bilaterally enlarged fetal kidneys with diffuse small cysts. The amniotic fluid volume is very low. No other anomalies are seen. Which of the following will most likely be present in the newborn after delivery?

- A. Bladder distension (3%)
- B. Cerebral aneurysm (8%)
- C. Hypertension (11%)
- ✓ D. Respiratory distress (72%)
- E. Vertebral anomalies (4%)

Omitted
Correct answer
D

72%
Answered correctly

02 secs
Time Spent

07/05/2020
Last Updated

Explanation

Autosomal recessive polycystic kidney disease	
Genetics	• Caused by mutation in *PKHD1* gene • Codes for fibrocystin (present in kidney & liver)

Autosomal recessive polycystic kidney disease	
Genetics	• Caused by mutation in *PKHD1* gene • Codes for fibrocystin (present in kidney & liver) • Autosomal recessive inheritance
Clinical findings	• Renal insufficiency • Nephromegaly • Hypertension
Diagnosis	• Bilateral enlarged, echogenic kidneys on ultrasound

©UWorld

Bilaterally enlarged, cystic fetal kidneys and oligohydramnios are findings consistent with **autosomal recessive polycystic kidney disease** (ARPKD). ARPKD is caused by a mutation in *PKHD1*, the gene for fibrocystin. Fibrocystin is found in the epithelial cells of both the renal tubule and the bile ducts; deficiency leads to the characteristic polycystic dilation of both structures. Mutations can be inherited in an **autosomal recessive** pattern or can be spontaneous mutations.

Age at presentation is determined by the severity of ARPKD. In its most severe form, ARPKD can be detected on prenatal ultrasound. **Oligohydramnios** is usually present because amniotic fluid is composed of **fetal urine** and renal filtration is severely impaired in ARPKD. The reduced amniotic fluid volume leads to characteristic findings (Potter sequence: **flattened facies, limb deformities, pulmonary hypoplasia**) due to the resultant compression of the fetus. Less severe phenotypes more often present with hepatic complications (eg, hepatomegaly, portal hypertension) and hypertension during childhood or early adulthood. Patients with ARPKD – especially when it presents in infancy – often need **dialysis** or renal **transplant**.

(Choice A) Bladder distension is caused by urethral obstruction as found in posterior urethral valves. Cysts are not seen in children with posterior urethral valves.

Bilaterally enlarged, cystic fetal kidneys and oligohydramnios are findings consistent with **autosomal recessive polycystic kidney disease** (ARPKD). ARPKD is caused by a mutation in *PKHD1*, the gene for fibrocystin. Fibrocystin is found in the epithelial cells of both the renal tubule and the bile ducts; deficiency leads to the characteristic polycystic dilation of both structures. Mutations can be inherited in an **autosomal recessive** pattern or can be spontaneous mutations.

Age at presentation is determined by the severity of ARPKD. In its most severe form, ARPKD can be detected on prenatal ultrasound. **Oligohydramnios** is usually present because amniotic fluid is composed of **fetal urine** and renal filtration is severely impaired in ARPKD. The reduced amniotic fluid volume leads to characteristic findings (Potter sequence: **flattened facies, limb deformities, pulmonary hypoplasia**) due to the resultant compression of the fetus. Less severe phenotypes more often present with hepatic complications (eg, hepatomegaly, portal hypertension) and hypertension during childhood or early adulthood. Patients with ARPKD – especially when it presents in infancy – often need **dialysis** or renal **transplant**.

(Choice A) Bladder distension is caused by urethral obstruction as found in posterior urethral valves. Cysts are not seen in children with posterior urethral valves.

(Choice B) Cerebral aneurysms are a common complication of autosomal dominant polycystic kidney disease, occurring in almost 25% of patients; cerebral aneurysms are not associated with ARPKD.

(Choice C) Hypertension is a common finding in ARPKD. However, hypertension usually is not present at birth but instead develops over the first few months in children with ARPKD who survive the neonatal period.

(Choice E) Vertebral anomalies in association with renal anomalies are suggestive of VACTERL association (vertebral, anal atresia, cardiac defects, tracheoesophageal fistula, renal defects, and limb defects). Common renal anomalies in VACTERL include atresia, dysplasia, and/or duplications but do not include ARPKD.

Educational objective:
In its most severe phenotype, autosomal recessive polycystic kidney disease can be detected on prenatal sonogram along with oligohydramnios. Potter sequence (flattened facies, limb deformities, pulmonary hypoplasia) is caused by oligohydramnios and is associated with high mortality.

References

Oligohydramnios is usually present because amniotic fluid is composed of **fetal urine** and renal filtration is severely impaired in ARPKD. The reduced amniotic fluid volume leads to characteristic findings (Potter sequence: **flattened facies, limb deformities, pulmonary hypoplasia**) due to the resultant compression of the fetus. Less severe phenotypes more often present with hepatic complications (eg, hepatomegaly, portal hypertension) and hypertension during childhood or early adulthood. Patients with ARPKD – especially when it presents in infancy – often need **dialysis** or renal **transplant**.

(Choice A) Bladder distension is caused by urethral obstruction as found in posterior urethral valves. Cysts are not seen in children with posterior urethral valves.

(Choice B) Cerebral aneurysms are a common complication of autosomal dominant polycystic kidney disease, occurring in almost 25% of patients; cerebral aneurysms are not associated with ARPKD.

(Choice C) Hypertension is a common finding in ARPKD. However, hypertension usually is not present at birth but instead develops over the first few months in children with ARPKD who survive the neonatal period.

(Choice E) Vertebral anomalies in association with renal anomalies are suggestive of VACTERL association (vertebral, anal atresia, cardiac defects, tracheoesophageal fistula, renal defects, and limb defects). Common renal anomalies in VACTERL include atresia, dysplasia, and/or duplications but do not include ARPKD.

Educational objective:
In its most severe phenotype, autosomal recessive polycystic kidney disease can be detected on prenatal sonogram along with oligohydramnios. Potter sequence (flattened facies, limb deformities, pulmonary hypoplasia) is caused by oligohydramnios and is associated with high mortality.

References

- Neonatal polycystic kidney disease.

Embryology	Renal, Urinary Systems & Electrolytes	Polycystic kidney disease
Subject	System	Topic

Copyright © UWorld. All rights reserved.

Oligohydramnios is usually present because amniotic fluid is composed of **fetal urine** and renal filtration is severely impaired in ARPKD. The

Exhibit Display

Posterior urethral valves

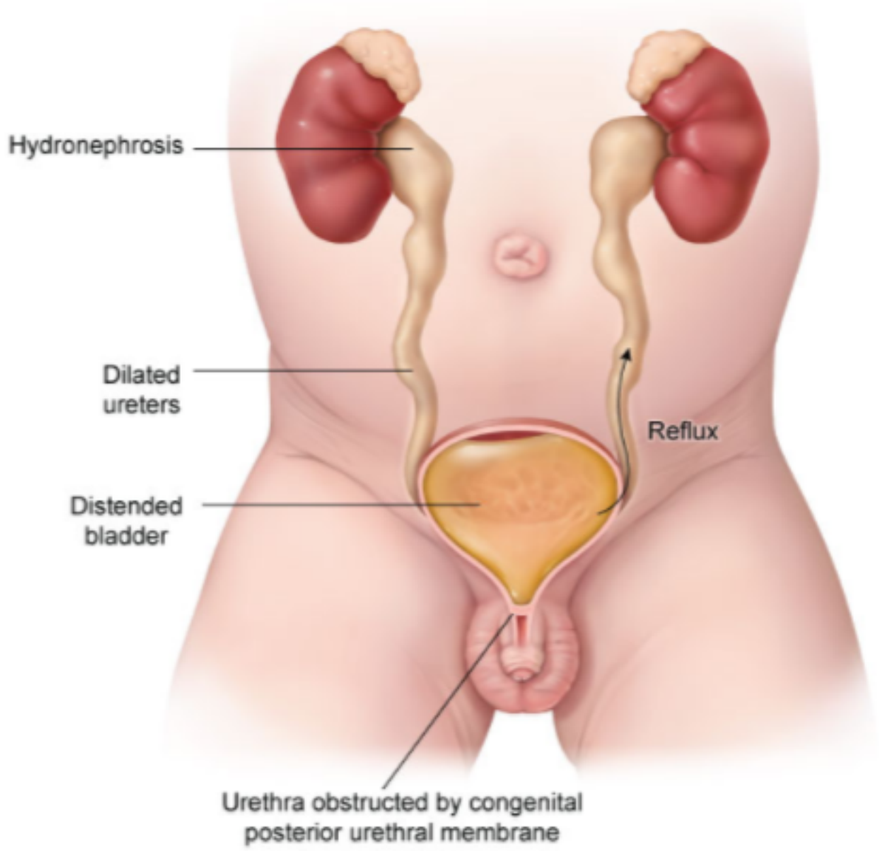

©UWorld

Zoom In Zoom Out Reset Add To New Card | Existing Card

Researchers working at a national foundation for prematurity and birth defects are investigating the pathological changes that can occur during embryonic kidney development. Their research focuses on the inductive signals exchanged between the metanephric diverticulum and metanephric blastema that drive their differentiation into tissues forming the mature kidney. If a toxic insult occurs during early fetal development that selectively inhibits the renal structures formed by the metanephric blastema, which of the following adult derivatives will fail to develop?

A. Collecting ducts

B. Distal convoluted tubules

C. Major calyces

D. Minor calyces

E. Renal pelvis

Submit

Researchers working at a national foundation for prematurity and birth defects are investigating the pathological changes that can occur during embryonic kidney development. Their research focuses on the inductive signals exchanged between the metanephric diverticulum and metanephric blastema that drive their differentiation into tissues forming the mature kidney. If a toxic insult occurs during early fetal development that selectively inhibits the renal structures formed by the metanephric blastema, which of the following adult derivatives will fail to develop?

A. Collecting ducts (15%)

✓ B. Distal convoluted tubules (54%)

C. Major calyces (5%)

D. Minor calyces (2%)

E. Renal pelvis (21%)

Omitted
Correct answer
B

54%
Answered correctly

02 secs
Time Spent

04/07/2020
Last Updated

Explanation

Settings

1
2
3
4
5
6
7
8
9
10
11
12
13
14
15
16
17
18
19
20
21
22
23
24
25
26
27
28
29
30

Item 4 of 40
Question Id: 1736

Mark | Previous | Next | Full Screen | Tutorial | Lab Values | Notes | Calculator | Reverse Color | Text Zoom | Settings

Kidney development

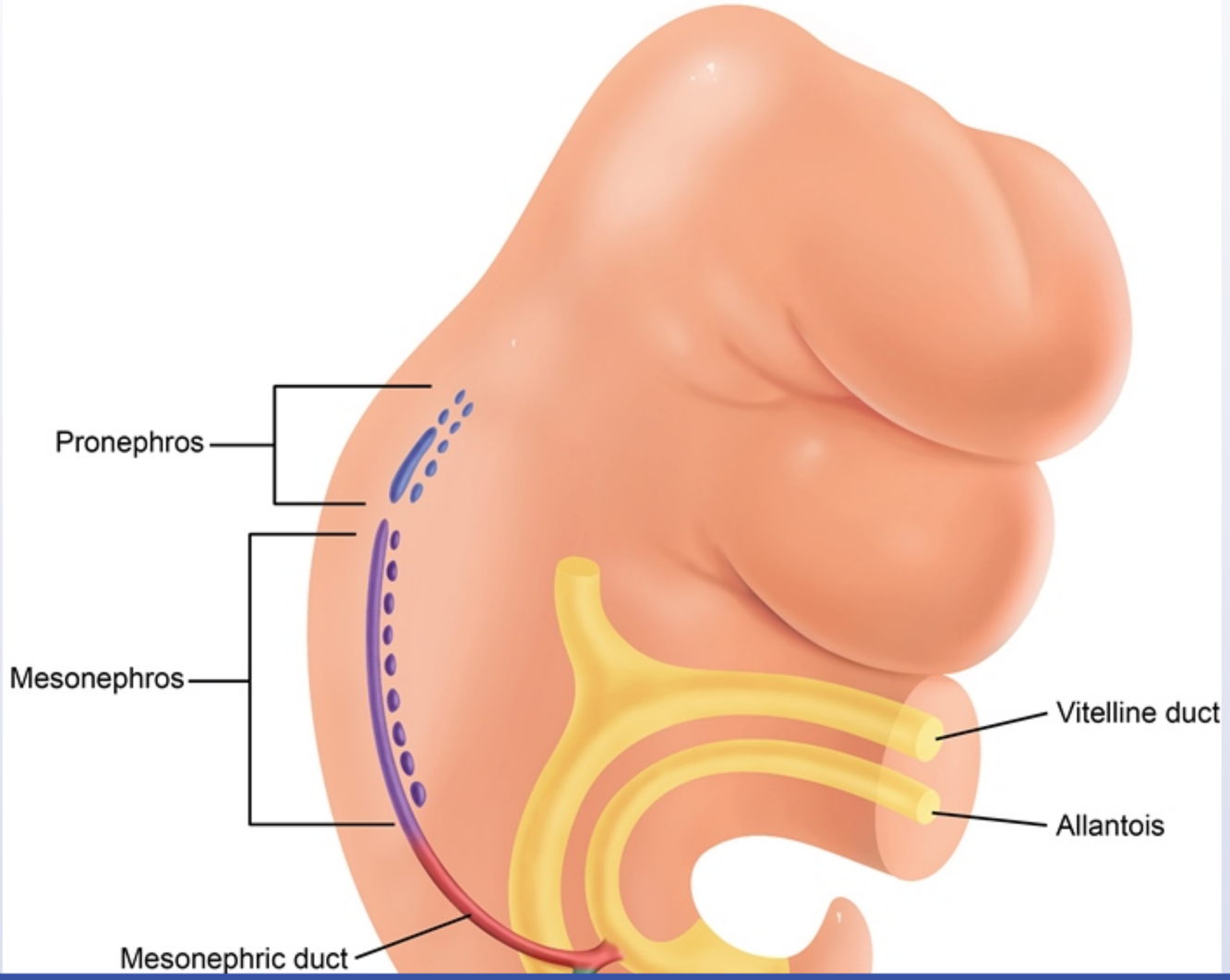

Block Time Remaining: 00:00:10
TUTOR

2 | Feedback | Suspend | End Block

Settings

1 2 3 4 5 6 7 8 9 10 11 12 13 14 15 16 17 18 19 20 21 22 23 24 25 26 27 28 29 30

Item 4 of 40
Question Id: 1736

Mark | Previous | Next | Full Screen | Tutorial | Lab Values | Notes | Calculator | Reverse Color | Text Zoom | Settings

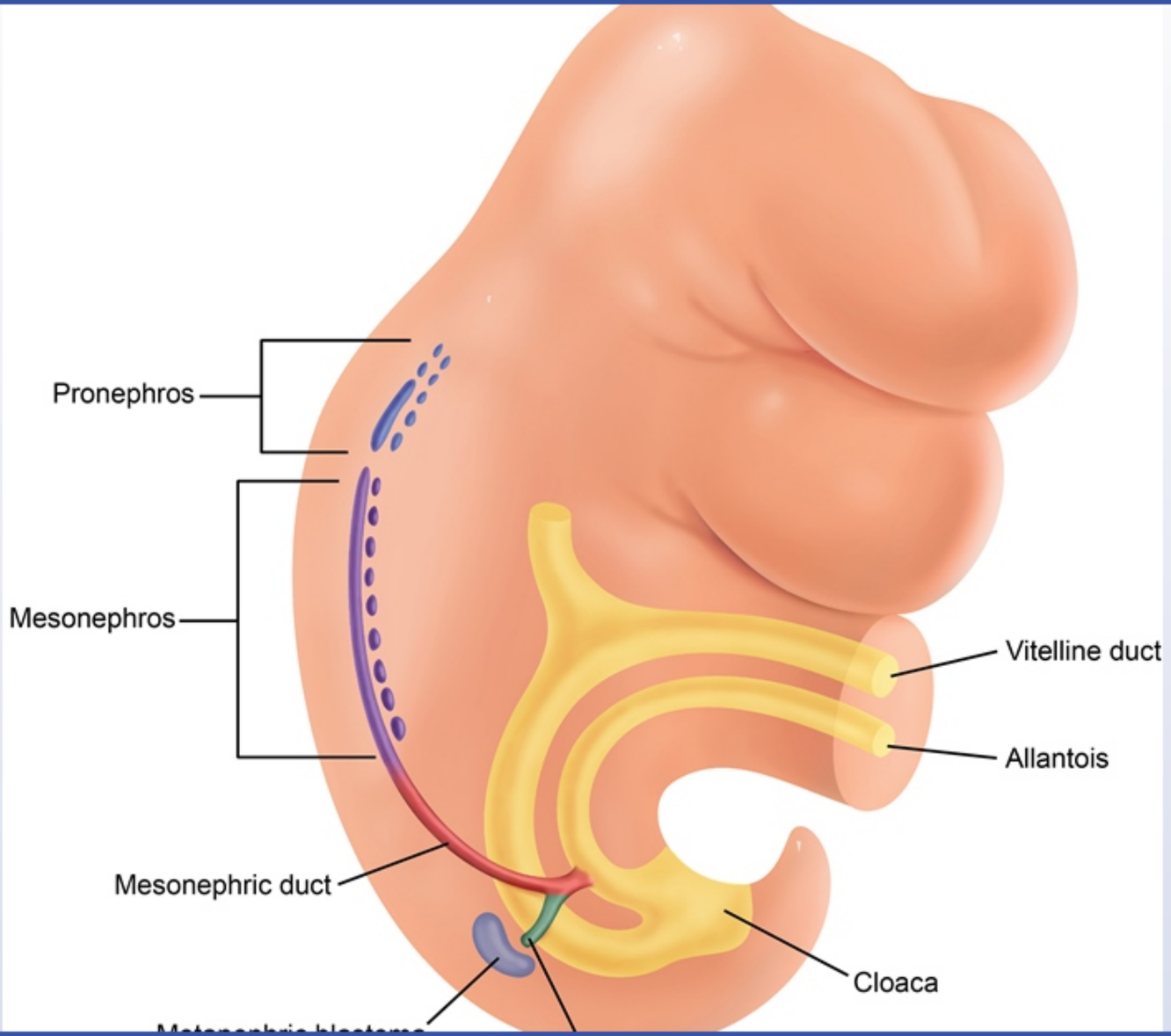

Block Time Remaining: 00:00:10
TUTOR

2 | Feedback | Suspend | End Block

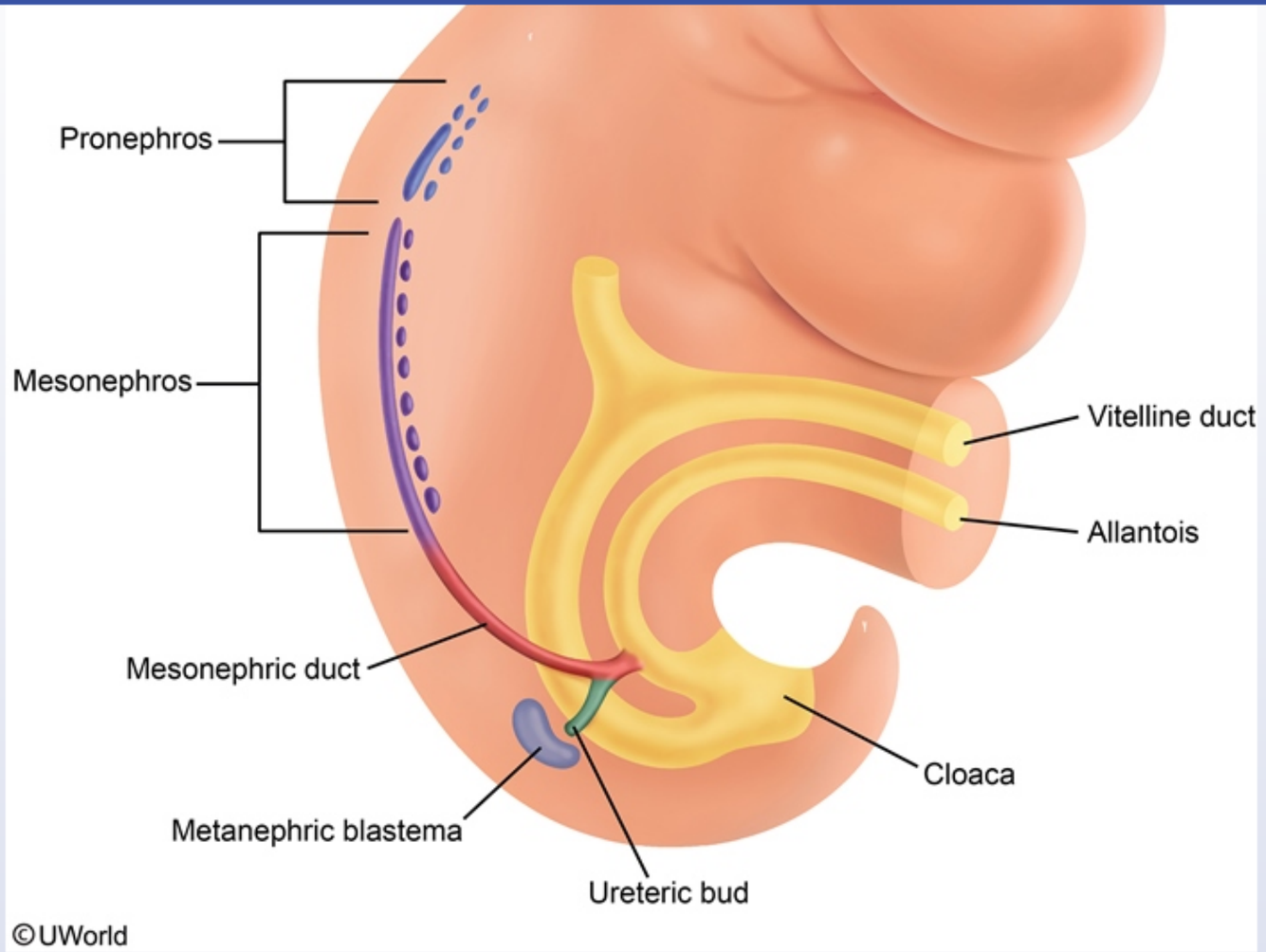

Embryonic kidney development involves the sequential formation of 3 sets of nephric systems termed the pronephros, mesonephros, and metanephros. The urinary structures formed during these stages are derived from the nephrogenic cord which develops from the urogenital ridge (intermediate mesoderm).

Ureteric bud

©UWorld

Embryonic kidney development involves the sequential formation of 3 sets of nephric systems termed the pronephros, mesonephros, and metanephros. The urinary structures formed during these stages are derived from the nephrogenic cord which develops from the urogenital ridge (intermediate mesoderm).

1. The pronephros forms first and later completely regresses.
2. The mesonephros forms next from the midportion of the nephrogenic cord.
   a. In males, it persists as the Wolffian ducts, forming the ductus deferens and epididymis.
   b. In females, the mesonephros regresses and becomes vestigial Gartner's ducts.
3. The **metanephros** forms last from the caudal end of the nephrogenic cord.
   a. It gives rise to the glomeruli, Bowman's space, proximal tubules, the loop of Henle, and **distal convoluted tubules**.

Development of the metanephros begins with formation of the metanephric diverticulum (ureteric bud) which penetrates the sacral intermediate mesoderm to induce the formation of the **metanephric blastema**. The reciprocal exchange of inductive signals between the metanephric diverticulum and metanephric blastema drives their differentiation into the structures that form the mature kidney. The ureteric bud ultimately gives rise to the collecting system of the kidney, including the collecting tubules and ducts, major and minor calyces, renal pelvis, and the ureters **(Choices A, C, D, and E)**.

Educational objective:
The metanephros (metanephric blastema) gives rise to the glomeruli, Bowman's space, proximal tubules, the loop of Henle, and distal convoluted tubules. The ureteric bud becomes the collecting system of the kidney, including the collecting tubules and ducts, major and minor calyces, renal pelvis, and the ureters.

Subject	System	Topic
Embryology	Renal, Urinary Systems & Electrolytes	Congenital anomalies of kidney and urinary tract

Copyright © UWorld. All rights reserved.

A 3-week-old boy with discharge from the umbilicus is brought to the clinic by his parents. His postnatal course was uncomplicated, with shriveling of the cord around 14 days of life. Vital signs are normal. Examination of the area reveals a small reducible umbilical hernia, minimal clear to straw-colored discharge from the umbilicus, and erythema around the area. Laboratory results are as follows:

Hemoglobin	12 g/dL
Hematocrit	36%
Leukocytes	11,000 cells/mm^3
Neutrophils	50%
Lymphocytes	45%

Which of the following is the most likely cause of this child's condition?

A. Absence of neutrophil migration

B. Duplication of the ureter

C. Incomplete closure of anterior abdominal wall

D. Persistence of allantois remnant

E. Persistence of omphalomesenteric duct

Submit

A 3-week-old boy with discharge from the umbilicus is brought to the clinic by his parents. His postnatal course was uncomplicated, with shriveling of the cord around 14 days of life. Vital signs are normal. Examination of the area reveals a small reducible umbilical hernia, minimal clear to straw-colored discharge from the umbilicus, and erythema around the area. Laboratory results are as follows:

Hemoglobin	12 g/dL
Hematocrit	36%
Leukocytes	11,000 cells/mm^3
Neutrophils	50%
Lymphocytes	45%

Which of the following is the most likely cause of this child's condition?

- A. Absence of neutrophil migration (17%)
- B. Duplication of the ureter (0%)
- C. Incomplete closure of anterior abdominal wall (8%)
- ✓ D. Persistence of allantois remnant (56%)
- E. Persistence of omphalomesenteric duct (16%)

Omitted
Correct answer
D

56%
Answered correctly

02 secs
Time Spent

04/09/2020
Last Updated

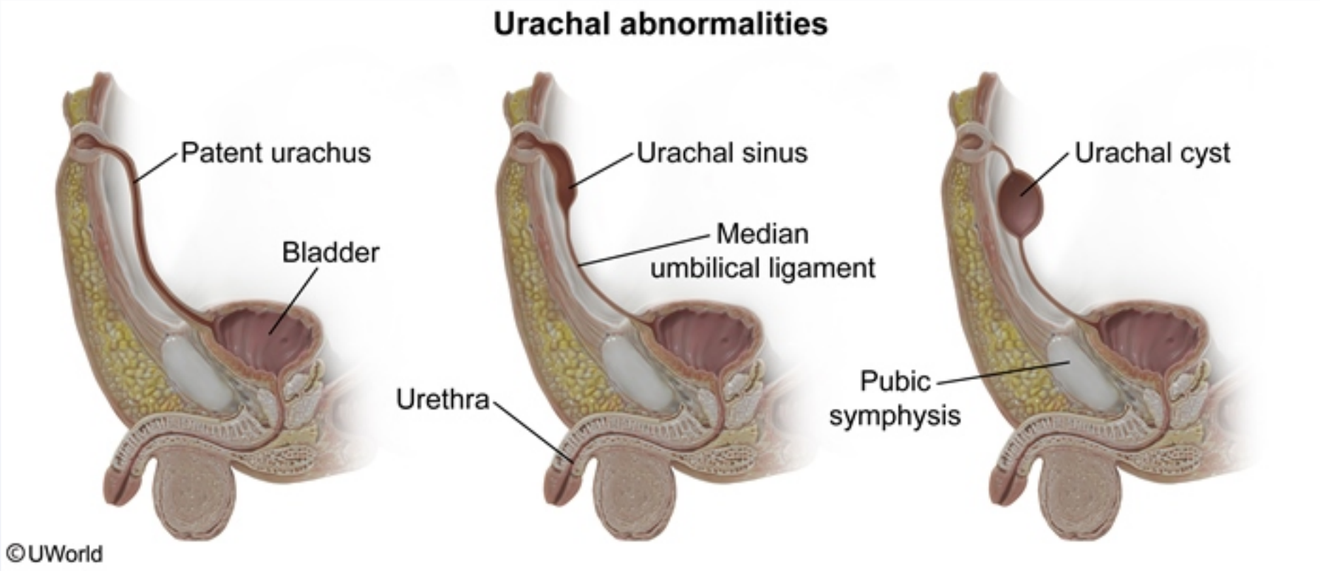

Around 3 weeks gestation, the yolk sac forms a protrusion (**allantois**) that extends into the urogenital sinus. The upper part of the urogenital sinus gives rise to the bladder. The allantois, which originally connected the urogenital sinus with the yolk sac, becomes the urachus, a duct between the bladder and the yolk sac. Failure of the urachus to obliterate before birth leads to several abnormalities:

1. Complete failure of obliteration of the urachus results in a **patent urachus** that connects the umbilicus and bladder. Patients present with straw-colored **urine discharge** from the umbilicus, which is exacerbated by crying, straining, or prone position. Local skin irritation can cause erythema.
2. Failure to close the distal part of the urachus (adjacent to the umbilicus) results in a **urachal sinus**. This presents with periumbilical tenderness and purulent umbilical discharge due to persistent and recurrent infection.
3. Failure of the central portion of the urachus to obliterate leads to a **urachal cyst**.

(Choice A) Leukocyte adhesion deficiency involves decreased expression of the neutrophil cell-surface adhesion proteins, β-2 integrins. As a result, neutrophils are less adherent to the vascular endothelium and fail to migrate toward infected sites. There is delayed separation of the

Around 3 weeks gestation, the yolk sac forms a protrusion (**allantois**) that extends into the urogenital sinus. The upper part of the urogenital sinus gives rise to the bladder. The allantois, which originally connected the urogenital sinus with the yolk sac, becomes the urachus, a duct between the bladder and the yolk sac. Failure of the urachus to obliterate before birth leads to several abnormalities:

1. Complete failure of obliteration of the urachus results in a **patent urachus** that connects the umbilicus and bladder. Patients present with straw-colored **urine discharge** from the umbilicus, which is exacerbated by crying, straining, or prone position. Local skin irritation can cause erythema.
2. Failure to close the distal part of the urachus (adjacent to the umbilicus) results in a **urachal sinus**. This presents with periumbilical tenderness and purulent umbilical discharge due to persistent and recurrent infection.
3. Failure of the central portion of the urachus to obliterate leads to a **urachal cyst**.

(Choice A) Leukocyte adhesion deficiency involves decreased expression of the neutrophil cell-surface adhesion proteins, β-2 integrins. As a result, neutrophils are less adherent to the vascular endothelium and fail to migrate toward infected sites. There is delayed separation of the umbilical cord (>1 month), omphalitis, and leukocytosis (unlike this patient, who has a normal white count and differential for his age).

(Choice B) A duplication of the renal collecting system can affect the pelvicalyceal system, the ureters, or both. The insertion of the ureter can be normal (in the trigone) or abnormal (in the urethra, vagina, or uterus). It does not involve the umbilicus.

(Choice C) Gastroschisis results from inadequate enlargement of the peritoneal cavity in utero. The viscera protrude through an abdominal wall defect adjacent to the umbilicus. Viscera are not covered by peritoneum.

(Choice E) Meckel diverticulum results from failure of obliteration of the vitelline (or omphalomesenteric duct). Toddlers may have painless gastrointestinal bleeding due to ectopic gastric mucosa.

Educational objective:
The urachus is a remnant of the allantois that connects the bladder with the yolk sac during fetal development. Failure of the urachus to obliterate at birth results in a patent urachus, which can facilitate discharge of urine from the umbilicus.

References

- Her belly button is leaking: a case of patent urachus.

cause erythema.

2. Failure to close the distal part of the urachus (adjacent to the umbilicus) results in a **urachal sinus**. This presents with periumbilical tenderness and purulent umbilical discharge due to persistent and recurrent infection.

3. Failure of the central portion of the urachus to obliterate leads to a **urachal cyst**.

(Choice A) Leukocyte adhesion deficiency involves decreased expression of the neutrophil cell-surface adhesion proteins, β-2 integrins. As a result, neutrophils are less adherent to the vascular endothelium and fail to migrate toward infected sites. There is delayed separation of the umbilical cord (>1 month), omphalitis, and leukocytosis (unlike this patient, who has a normal white count and differential for his age).

(Choice B) A duplication of the renal collecting system can affect the pelvicalyceal system, the ureters, or both. The insertion of the ureter can be normal (in the trigone) or abnormal (in the urethra, vagina, or uterus). It does not involve the umbilicus.

(Choice C) Gastroschisis results from inadequate enlargement of the peritoneal cavity in utero. The viscera protrude through an abdominal wall defect adjacent to the umbilicus. Viscera are not covered by peritoneum.

(Choice E) Meckel diverticulum results from failure of obliteration of the vitelline (or omphalomesenteric duct). Toddlers may have painless gastrointestinal bleeding due to ectopic gastric mucosa.

Educational objective:
The urachus is a remnant of the allantois that connects the bladder with the yolk sac during fetal development. Failure of the urachus to obliterate at birth results in a patent urachus, which can facilitate discharge of urine from the umbilicus.

References

- Her belly button is leaking: a case of patent urachus.

Subject	System	Topic
Embryology	Renal, Urinary Systems & Electrolytes	Congenital anomalies of kidney and urinary tract

Copyright © UWorld. All rights reserved.

1 2 3 4 5 6 7 8 9 10 11 12 13 14 15 16 17 18 19 20 21 22 23 24 25 26 27 28 29 30

cause erythema.

Exhibit Display

Gastroschisis
Eviscerated bowel with no covering membrane

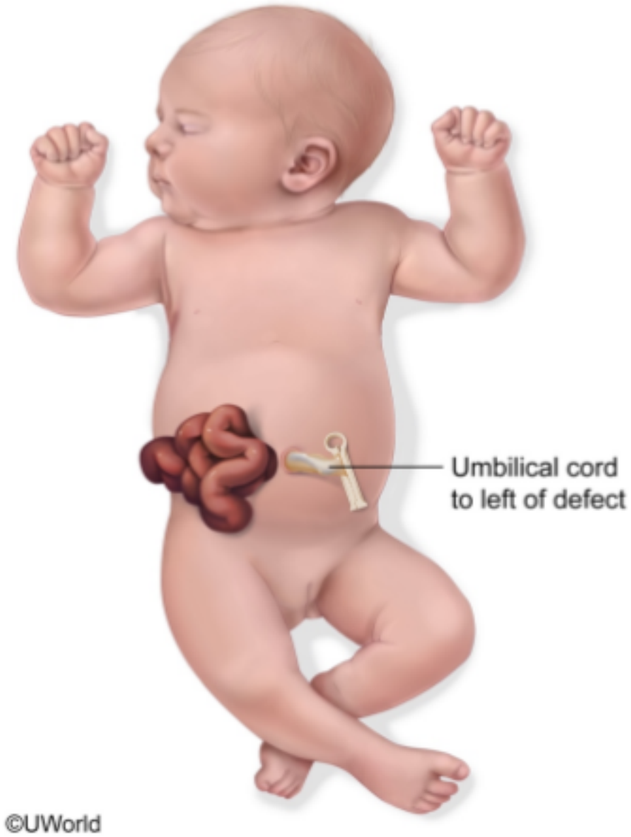

Zoom In | Zoom Out | Reset | Add To New Card | Existing Card

cause erythema.

Exhibit Display

Vitelline duct abnormalities

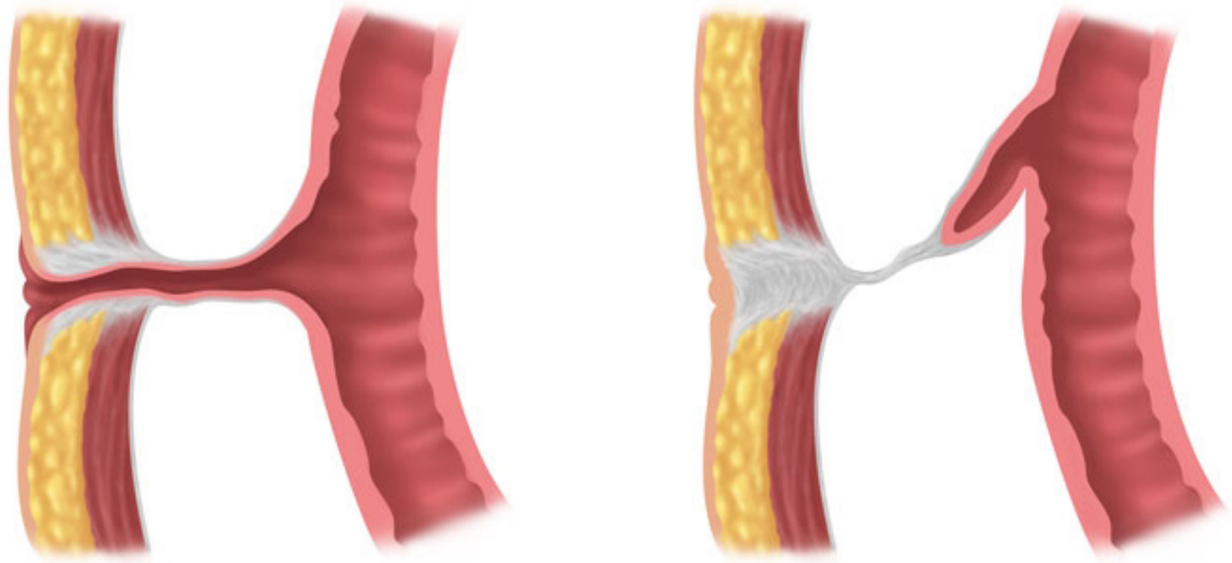

Persistent vitelline duct

Meckel diverticulum

©UWorld

Zoom In | Zoom Out | Reset | Add To New Card | Existing Card

A 41-year-old woman, gravida 0, comes to the office for evaluation of pregnancy. Menarche was at age 12, and her menses recur every 30 days and last 5 days. The patient and her husband have been trying to conceive for the past year and plan intercourse during her fertile window according to the ovulation predictor kit. She has no medical problems, takes no medications, and has no allergies. BMI is 23 kg/m^2. Vital signs and physical examination are normal. If fertilization and implantation occurred this cycle, when would the β-hCG level first be detectable in the serum?

A. 1 day after fertilization

B. 3 days after fertilization

C. 8 days after fertilization

D. 14 days after fertilization

E. On the day of fertilization

Submit

A 41-year-old woman, gravida 0, comes to the office for evaluation of pregnancy. Menarche was at age 12, and her menses recur every 30 days and last 5 days. The patient and her husband have been trying to conceive for the past year and plan intercourse during her fertile window according to the ovulation predictor kit. She has no medical problems, takes no medications, and has no allergies. BMI is 23 kg/m^2. Vital signs and physical examination are normal. If fertilization and implantation occurred this cycle, when would the β-hCG level first be detectable in the serum?

- A. 1 day after fertilization (2%)
- B. 3 days after fertilization (11%)
- ✓ C. 8 days after fertilization (70%)
- D. 14 days after fertilization (14%)
- E. On the day of fertilization (1%)

Omitted
Correct answer
C

70%
Answered correctly

02 secs
Time Spent

01/13/2020
Last Updated

Explanation

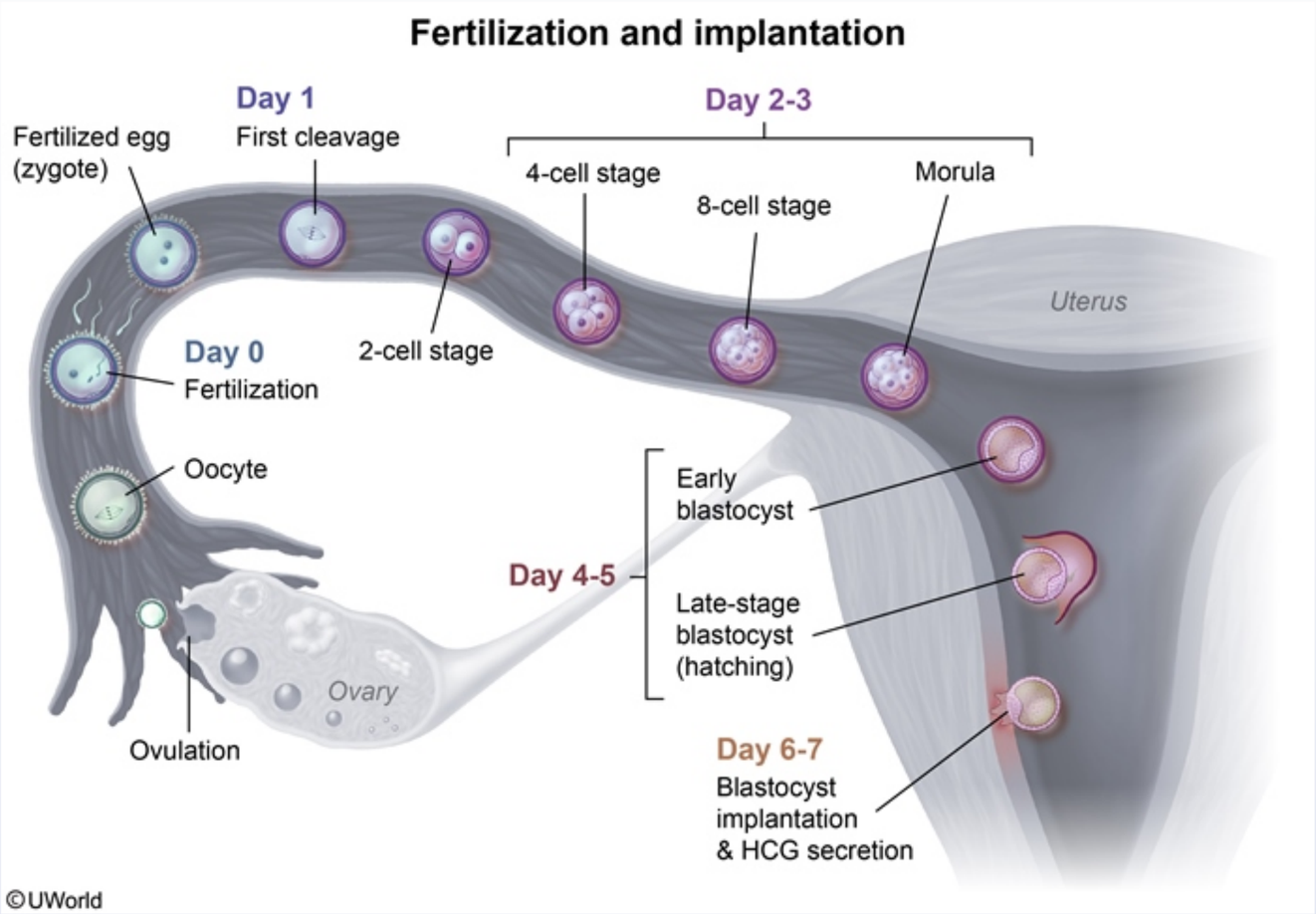

An ovulation predictor kit measures urinary LH and becomes positive 24 hours before ovulation. Once an oocyte is released from the ovary, sperm may fertilize it for up to 24 hours. After fertilization, the second meiotic division completes and a zygote forms. The zygote travels through the fallopian tube and undergoes mitotic divisions (cleavage), creating smaller cells (blastomeres) that are collectively known as a morula. The morula enters the uterus 3-4 days after fertilization and develops a blastocystic cavity, becoming a blastocyst.

The blastocyst implants 6 days after fertilization **(Choices A, B, and E)**, and the outer cell mass (trophoblast) differentiates into the cytotrophoblast

©UWorld

An ovulation predictor kit measures urinary LH and becomes positive 24 hours before ovulation. Once an oocyte is released from the ovary, sperm may fertilize it for up to 24 hours. After fertilization, the second meiotic division completes and a zygote forms. The zygote travels through the fallopian tube and undergoes mitotic divisions (cleavage), creating smaller cells (blastomeres) that are collectively known as a morula. The morula enters the uterus 3-4 days after fertilization and develops a blastocystic cavity, becoming a blastocyst.

The blastocyst implants 6 days after fertilization **(Choices A, B, and E)**, and the outer cell mass (trophoblast) differentiates into the cytotrophoblast and **syncytiotrophoblast**. The syncytiotrophoblast invades the endometrial connective tissue 6-7 days after fertilization and starts **secreting β-hCG**, which signals to the corpus luteum in the ovary to continue producing progesterone.

Accordingly, β-hCG may appear in the maternal serum 6 days after fertilization at the earliest and may require additional time to rise to a detectable level in serum (typically **8 days**). β-hCG is detectable in the maternal serum at <5 IU/L, making **serum β-hCG** testing the **most sensitive** method of detecting pregnancy.

(Choice D) A urine pregnancy test is less sensitive than a serum pregnancy test; it becomes positive when β-hCG reaches 20 IU/L, which typically occurs 14 days following fertilization.

Educational objective:
β-hCG is produced by the syncytiotrophoblast after implantation, which generally occurs 6-7 days after fertilization at the earliest. β-hCG typically is detectable in the maternal serum approximately 8 days after fertilization, whereas it is detectable in the urine 14 days after fertilization. Therefore, a serum pregnancy test will be positive before a urine pregnancy test.

References

- Human chorionic gonadotropin in pregnancy diagnostics.

Embryology	Pregnancy, Childbirth & Puerperium	Normal pregnancy
Subject	System	Topic

Copyright © UWorld. All rights reserved.

©UWorld

Exhibit Display

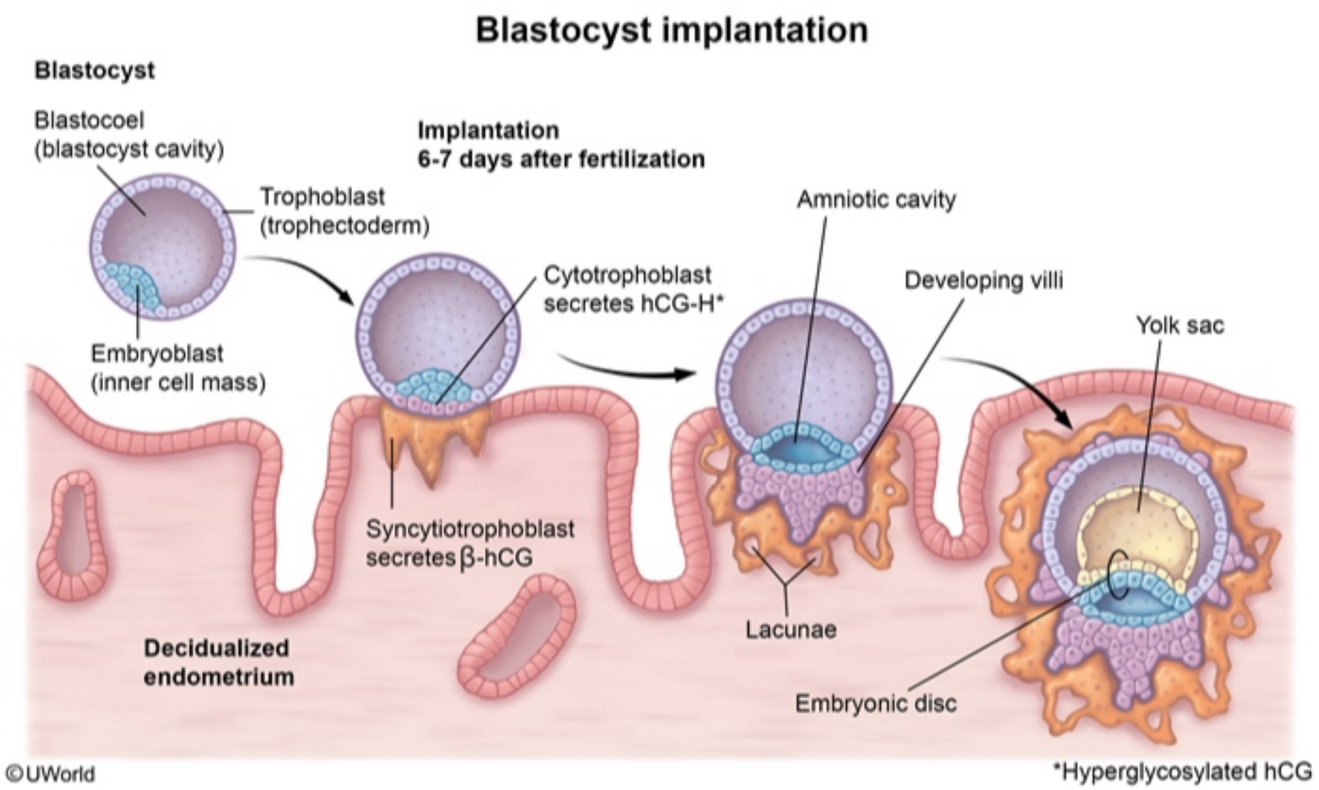

Zoom In | Zoom Out | Reset | Add To New Card | Existing Card

1 2 3 4 5 6 7 8 9 10 11 12 13 14 15 16 17 18 19 20 21 22 23 24 25 26 27 28 29 30

A boy is examined in the newborn nursery shortly after birth. He was born full term by vaginal delivery to a 40-year-old woman who did not receive prenatal care. His temperature is 36.7 C (98 F), pulse is 132/min, and respirations are 38/min. Examination shows slanted palpebral fissures, epicanthal folds, thick nuchal folds, and a single palmar crease. The patient has a large, reducible midline abdominal protrusion covered by skin that is more pronounced when he cries. The umbilical stump is at the center of the protrusion. Which of the following is the most likely cause of this patient's abdominal finding?

A. Failure of the extraembryonic gut to return to the abdominal cavity

B. Incomplete closure of the umbilical ring

C. Incomplete recanalization of the fetal intestinal tract

D. Incomplete rotation of the midgut in utero

E. Persistent processus vaginalis

Submit

A boy is examined in the newborn nursery shortly after birth. He was born full term by vaginal delivery to a 40-year-old woman who did not receive prenatal care. His temperature is 36.7 C (98 F), pulse is 132/min, and respirations are 38/min. Examination shows slanted palpebral fissures, epicanthal folds, thick nuchal folds, and a single palmar crease. The patient has a large, reducible midline abdominal protrusion covered by skin that is more pronounced when he cries. The umbilical stump is at the center of the protrusion. Which of the following is the most likely cause of this patient's abdominal finding?

- A. Failure of the extraembryonic gut to return to the abdominal cavity (35%)
- ✓ B. Incomplete closure of the umbilical ring (44%)
- C. Incomplete recanalization of the fetal intestinal tract (10%)
- D. Incomplete rotation of the midgut in utero (6%)
- E. Persistent processus vaginalis (3%)

Omitted
Correct answer
B

44%
Answered correctly

02 secs
Time Spent

05/30/2020
Last Updated

Explanation

Congenital umbilical hernia	
Pathophysiology	• Incomplete closure of abdominal muscles
	• Soft, nontender bulge at umbilicus

Explanation

Congenital umbilical hernia	
Pathophysiology	• Incomplete closure of abdominal muscles
Clinical features	• Soft, nontender bulge at umbilicus • Protrudes with increased abdominal pressure • Typically reducible
Management	• Observe for spontaneous closure • Elective surgery around age 5

This patient's examination is consistent with Down syndrome and an umbilical hernia. Normally, the umbilical ring, or the congenital fascial opening for the umbilical cord, closes and forms the linea alba, a midline band of fibrous tissue. **Umbilical hernias** are caused by an **incomplete closure of the umbilical ring**, thereby allowing protrusion of bowel through the abdominal musculature. Most umbilical hernias are **reducible**, **asymptomatic**, and **resolve spontaneously** in the first few years of life.

(Choice A) During midgut development in the first trimester, the abdominal contents undergo physiologic herniation, followed by a rotation of the midgut and physiologic reduction. Failure of this reduction can result in omphalocele or gastroschisis. Omphalocele presents as a midline herniation of abdominal contents contained within a thin, membranous sac. Gastroschisis is a full-thickness abdominal wall defect that presents as an evisceration of exposed abdominal contents at birth.

(Choice C) Midgut development in the first trimester involves a physiologic occlusion of the intestinal lumen followed by recanalization. Failure of recanalization results in duodenal atresia, which presents with vomiting, often bilious, in the first 24 hours of life. Duodenal atresia is associated with Down syndrome.

(Choice D) Malrotation results from an incomplete rotation of the midgut prior to physiologic reduction into the abdominal cavity. Malrotation alone is asymptomatic. Its main complication is ischemia and subsequent small bowel necrosis due to volvulus, which twists and constricts the blood supply. Volvulus typically presents with bilious emesis in the first month of life.

This patient's examination is consistent with Down syndrome and an umbilical hernia. Normally, the umbilical ring, or the congenital fascial opening for the umbilical cord, closes and forms the linea alba, a midline band of fibrous tissue. **Umbilical hernias** are caused by an **incomplete closure of the umbilical ring**, thereby allowing protrusion of bowel through the abdominal musculature. Most umbilical hernias are **reducible**, **asymptomatic**, and **resolve spontaneously** in the first few years of life.

(Choice A) During midgut development in the first trimester, the abdominal contents undergo physiologic herniation, followed by a rotation of the midgut and physiologic reduction. Failure of this reduction can result in omphalocele or gastroschisis. Omphalocele presents as a midline herniation of abdominal contents contained within a thin, membranous sac. Gastroschisis is a full-thickness abdominal wall defect that presents as an evisceration of exposed abdominal contents at birth.

(Choice C) Midgut development in the first trimester involves a physiologic occlusion of the intestinal lumen followed by recanalization. Failure of recanalization results in duodenal atresia, which presents with vomiting, often bilious, in the first 24 hours of life. Duodenal atresia is associated with Down syndrome.

(Choice D) Malrotation results from an incomplete rotation of the midgut prior to physiologic reduction into the abdominal cavity. Malrotation alone is asymptomatic. Its main complication is ischemia and subsequent small bowel necrosis due to volvulus, which twists and constricts the blood supply. Volvulus typically presents with bilious emesis in the first month of life.

(Choice E) Congenital inguinal hernias are formed when the processus vaginalis, an outpouching of the peritoneum, fails to obliterate, leaving a path to allow bowel contents into the inguinal canal. The hernias present as a mass in the groin and are more common in preterm male infants. Like umbilical hernias, congenital inguinal hernias are more prominent with increased abdominal pressure.

Educational objective:
Umbilical hernias are caused by a defect in the linea alba and present as protrusions at the umbilicus that are soft, reducible, and benign. They can occur in isolation or in association with other conditions, such as Down syndrome.

References

- Fetal abdominal wall defects.
- Congenital and acquired umbilical hernias: examination and treatment.

1
2
3
4
5
6
7
8
9
10
11
12
13
14
15
16
17
18
19
20
21
22
23
24
25
26
27
28
29
30

Exhibit Display

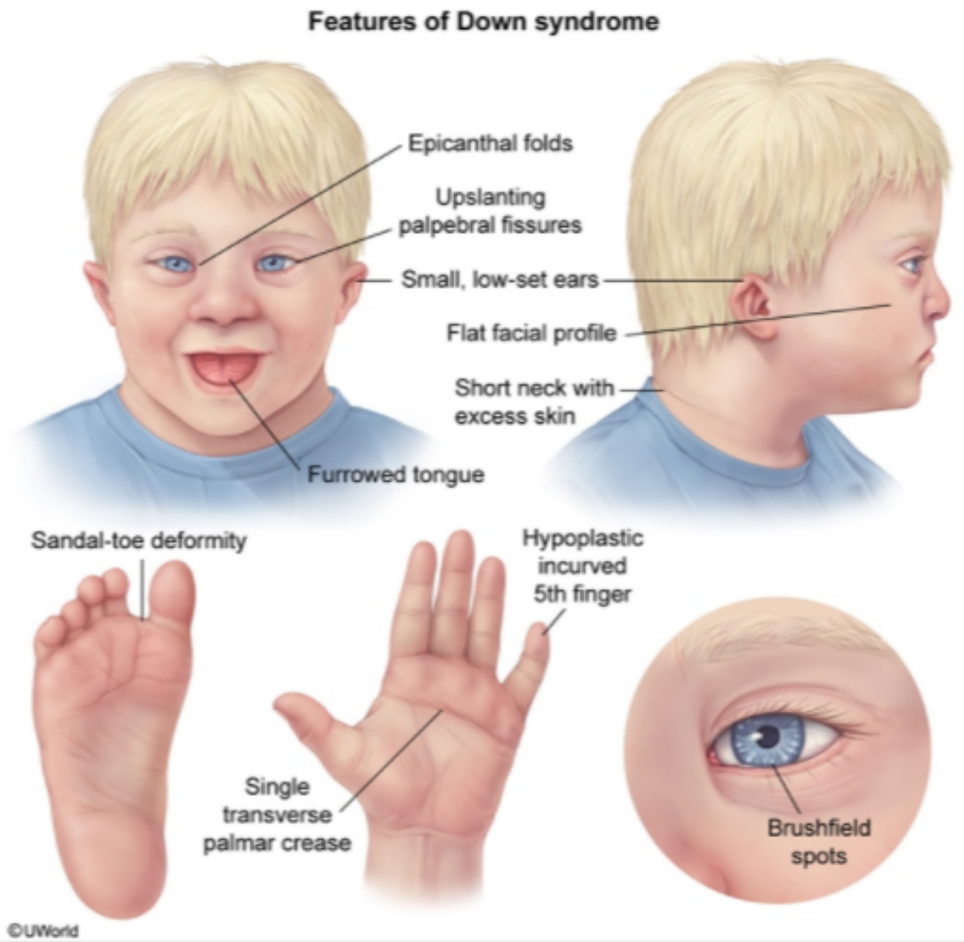

Zoom In | Zoom Out | Reset | Add To New Card | Existing Card

- Congenital and acquired umbilical hernias: examination and treatment.

This patient's examination is consistent with Down syndrome and an umbilical hernia. Normally, the umbilical ring, or the congenital fascial opening for the umbilical c ete **closure of the umbilical** , **asymptomatic**, and **resol**

(Choice A) During midgu he midgut and physiologic re herniation of abdominal co ts as an evisceration of expo

(Choice C) Midgut develo e of recanalization results in d d with Down syndrome.

(Choice D) Malrotation re alone is asymptomatic. Its e blood supply. Volvulus typ

(Choice E) Congenital in a path to allow bowel conte s. Like umbilical hernias, co

Educational objective:
Umbilical hernias are caus y can occur in isolation or in

References

- Fetal abdominal wall c
- Congenital and acquired umbilical hernias: examination and treatment.

Exhibit Display

0:00

Exhibit Display

Gastroschisis vs. omphalocele

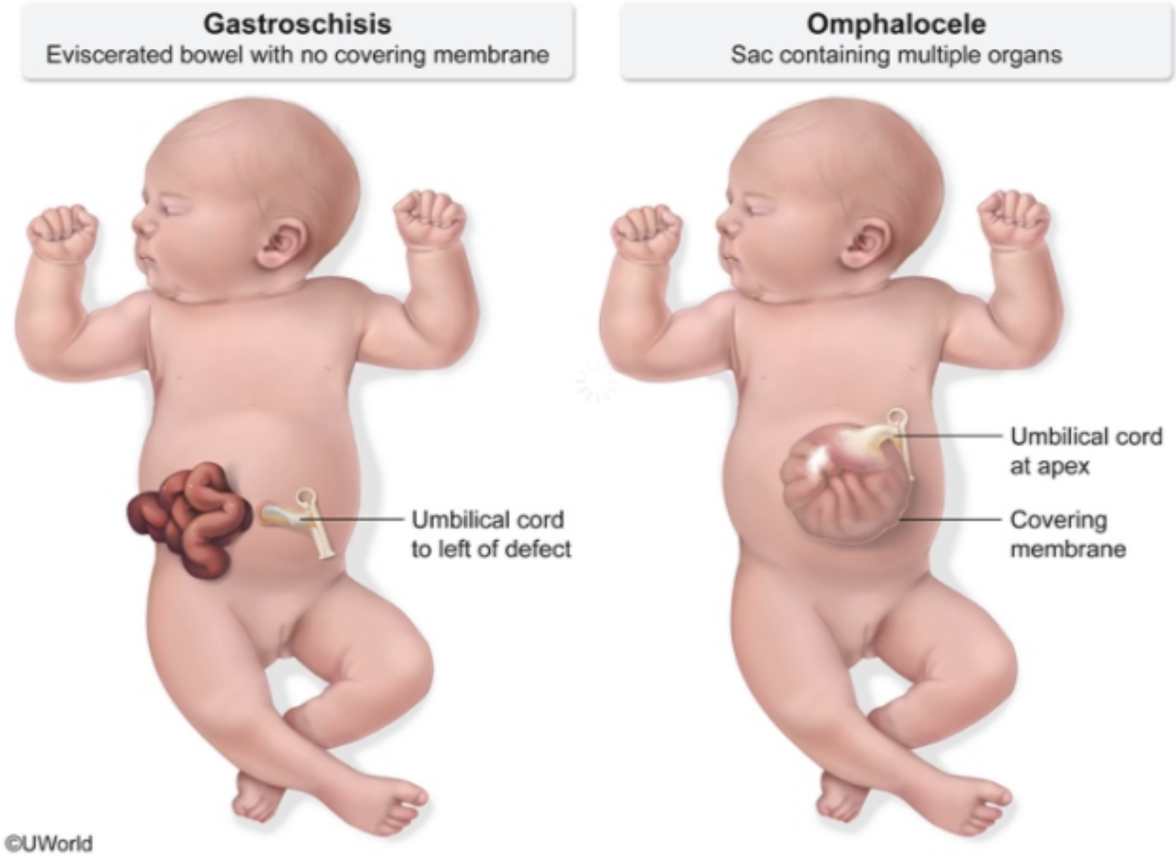

Zoom In | Zoom Out | Reset | Add To New Card | Existing Card

- Congenital and acquired umbilical hernias: examination and treatment.

(Choice A) During midgut development in the first trimester, the abdominal contents undergo physiologic herniation, followed by a rotation of the midgut and physiologic reduction. Failure of this reduction can result in omphalocele or gastroschisis. Omphalocele presents as a midline herniation of abdominal contents contained within a thin, membranous sac. Gastroschisis is a full-thickness abdominal wall defect that presents as an evisceration of exposed abdominal contents at birth.

(Choice C) Midgut development in the first trimester involves a physiologic occlusion of the intestinal lumen followed by recanalization. Failure of recanalization results in duodenal atresia, which presents with vomiting, often bilious, in the first 24 hours of life. Duodenal atresia is associated with Down syndrome.

(Choice D) Malrotation results from an incomplete rotation of the midgut prior to physiologic reduction into the abdominal cavity. Malrotation alone is asymptomatic. Its main complication is ischemia and subsequent small bowel necrosis due to volvulus, which twists and constricts the blood supply. Volvulus typically presents with bilious emesis in the first month of life.

(Choice E) Congenital inguinal hernias are formed when the processus vaginalis, an outpouching of the peritoneum, fails to obliterate, leaving a path to allow bowel contents into the inguinal canal. The hernias present as a mass in the groin and are more common in preterm male infants. Like umbilical hernias, congenital inguinal hernias are more prominent with increased abdominal pressure.

Educational objective:
Umbilical hernias are caused by a defect in the linea alba and present as protrusions at the umbilicus that are soft, reducible, and benign. They can occur in isolation or in association with other conditions, such as Down syndrome.

References

- Fetal abdominal wall defects.
- Congenital and acquired umbilical hernias: examination and treatment.

Embryology	Gastrointestinal & Nutrition	Umbilical hernia
Subject	System	Topic

Copyright © UWorld. All rights reserved.

A 45-year-old woman is brought to the emergency department after a generalized tonic-clonic seizure. She reports no prior history of seizures, but she has noticed right arm weakness over the last week. Her family history is significant for her mother's death from skin cancer. Physical examination shows a skin lesion measuring 13 mm on her back, as shown in the image below.

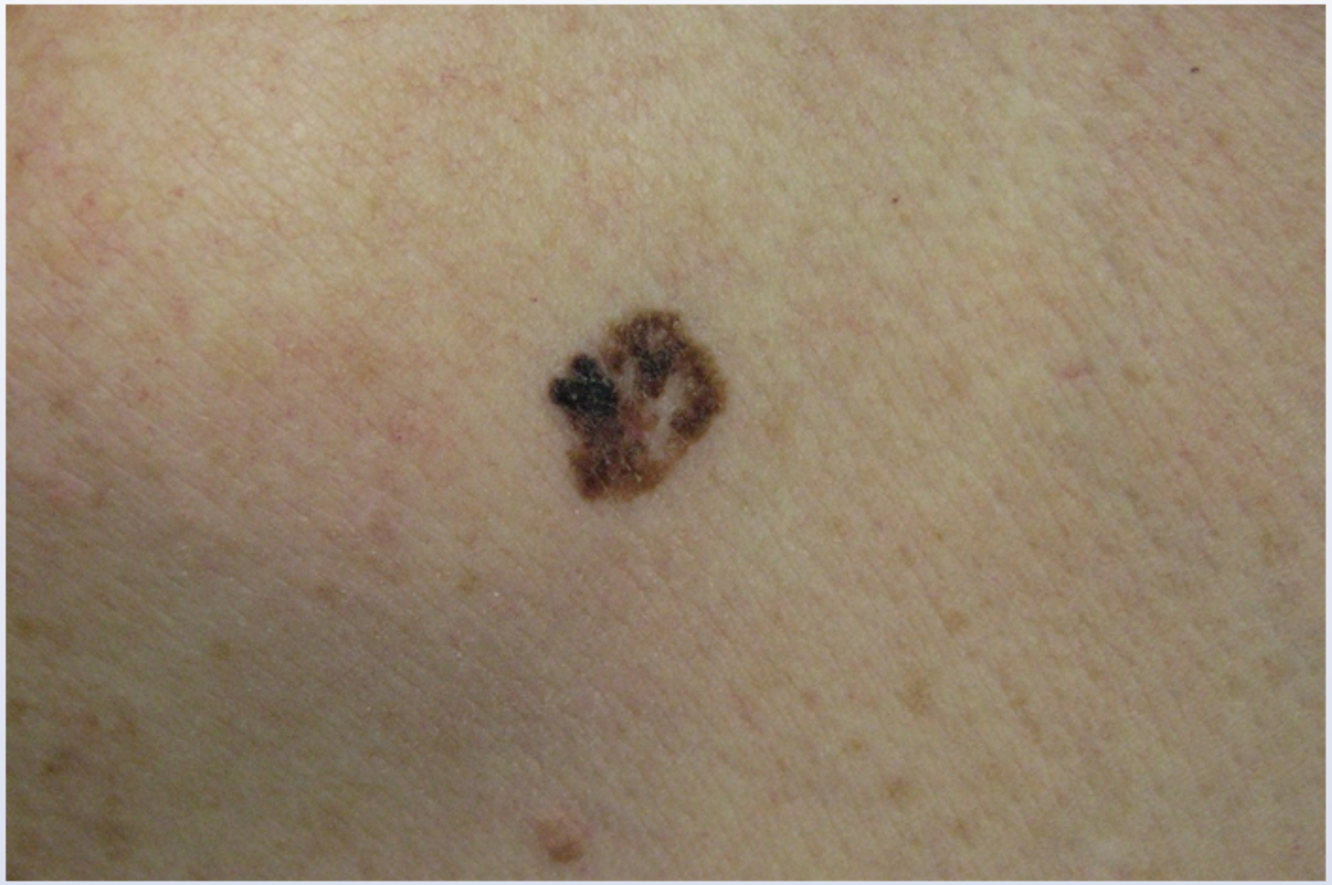

This lesion most likely originated from which of the following embryologic derivatives?

Settings

1
2
3
4
5
6
7
8
9
10
11
12
13
14
15
16
17
18
19
20
21
22
23
24
25
26
27
28
29
30

Item 8 of 40
Question Id: 1960

Mark | Previous | Next | Full Screen | Tutorial | Lab Values | Notes | Calculator | Reverse Color | Text Zoom | Settings

This lesion most likely originated from which of the following embryologic derivatives?

A. Endoderm
B. Mesoderm
C. Neural crest
D. Neuroectoderm
E. Surface ectoderm

Submit

Block Time Remaining: 00:00:20
TUTOR

4 | Feedback | Suspend | End Block

1 2 3 4 5 6 7 8 9 10 11 12 13 14 15 16 17 18 19 20 21 22 23 24 25 26 27 28 29 30

This lesion most likely originated from which of the following embryologic derivatives?

A. Endoderm (0%)

B. Mesoderm (2%)

✓ C. Neural crest (71%)

D. Neuroectoderm (11%)

E. Surface ectoderm (13%)

Omitted
Correct answer

71%
Answered correctly

06 secs
Time Spent

05/22/2020
Last Updated

Clinical features of melanoma (ABCDE)
• **A**symmetry: When bisected, the 2 sides are not identical • **B**order irregularities: Uneven edges, pigment fading off • **C**olor variegation: Variable mixtures of brown, tan, black & red • **D**iameter: ≥6 mm • **E**volving: Lesion changing in size, shape, or color; new lesion

This patient's family history of skin cancer, the melanocytic lesion seen on skin examination, and her 1-week history of focal neurologic deficit suggest that her seizure results from malignant melanoma metastatic to the central nervous system. Melanoma commonly metastasizes to the brain, gastrointestinal tract, bone, liver, and lungs. It is a malignancy of melanocytes, which are of neural crest origin.

(Choice A) The endoderm gives rise to all structures derived from the inner lining of the primitive gut tube. These include the thyroid follicular cells; epithelial surfaces of the trachea, bronchi, and lungs; liver and biliary tree; pancreas; and gastrointestinal and bladder epithelium.

(Choice B) The mesoderm gives rise to the dermis as well as most bones, muscles, blood vessels, and visceral tissue.

(Choice D) The neuroectoderm gives rise to the central nervous system, preganglionic autonomic neurons, retina, and posterior pituitary.

(Choice E) The surface ectoderm gives rise to the epidermis and its appendages, mammary glands (modified sweat glands), lens of the eye, and adenohypophysis.

Educational objective:
The most common metastatic tumors to the brain are lung cancer, renal cancer, and melanoma. Melanoma is a malignancy of melanocytes, which are embryologically derived from neural crest cells.

References

- Incidence of brain metastases in a cohort of patients with carcinoma of the breast, colon, kidney, and lung and melanoma.
- Incidence proportions of brain metastases in patients diagnosed (1973 to 2001) in the Metropolitan Detroit Cancer Surveillance System.

- Color variegation: Variable mixtures of brown, tan, black & red
- Diameter: ≥6 mm
- Evolving: Lesion changing in size, shape, or color; new lesion

This patient's family history of skin cancer, the melanocytic lesion seen on skin examination, and her 1-week history of focal neurologic deficit suggest that her seizure results from malignant melanoma metastatic to the central nervous system. Melanoma commonly metastasizes to the brain, gastrointestinal tract, bone, liver, and lungs. It is a malignancy of melanocytes, which are of neural crest origin.

(Choice A) The endoderm gives rise to all structures derived from the inner lining of the primitive gut tube. These include the thyroid follicular cells; epithelial surfaces of the trachea, bronchi, and lungs; liver and biliary tree; pancreas; and gastrointestinal and bladder epithelium.

(Choice B) The mesoderm gives rise to the dermis as well as most bones, muscles, blood vessels, and visceral tissue.

(Choice D) The neuroectoderm gives rise to the central nervous system, preganglionic autonomic neurons, retina, and posterior pituitary.

(Choice E) The surface ectoderm gives rise to the epidermis and its appendages, mammary glands (modified sweat glands), lens of the eye, and adenohypophysis.

Educational objective:
The most common metastatic tumors to the brain are lung cancer, renal cancer, and melanoma. Melanoma is a malignancy of melanocytes, which are embryologically derived from neural crest cells.

References

- Incidence of brain metastases in a cohort of patients with carcinoma of the breast, colon, kidney, and lung and melanoma.
- Incidence proportions of brain metastases in patients diagnosed (1973 to 2001) in the Metropolitan Detroit Cancer Surveillance System.

Embryology	Dermatology	Melanoma
Subject	System	Topic

Copyright © UWorld. All rights reserved.

A 3-day-old girl is brought to the emergency department by her parents due to persistent vomiting and refusal to feed. The vomiting began early in the morning and has been a greenish-yellow color. The emesis does not contain blood. The infant appears dehydrated. Her heart rate is 175/min and blood pressure is within normal limits. After initial evaluation is complete, the infant undergoes laparotomy. Findings include a normal-appearing duodenum, the absence of a large segment of jejunum and ileum, and the remainder of the distal ileum winding around a thin vascular stalk. Which of the following intrauterine processes is most likely responsible for this patient's condition?

- A. Abnormal rotation
- B. Cell migration failure
- C. Failure of partitioning
- D. Recanalization failure
- E. Vascular occlusion

Submit

A 3-day-old girl is brought to the emergency department by her parents due to persistent vomiting and refusal to feed. The vomiting began early in the morning and has been a greenish-yellow color. The emesis does not contain blood. The infant appears dehydrated. Her heart rate is 175/min and blood pressure is within normal limits. After initial evaluation is complete, the infant undergoes laparotomy. Findings include a normal-appearing duodenum, the absence of a large segment of jejunum and ileum, and the remainder of the distal ileum winding around a thin vascular stalk. Which of the following intrauterine processes is most likely responsible for this patient's condition?

- A. Abnormal rotation (32%)
- B. Cell migration failure (11%)
- C. Failure of partitioning (5%)
- D. Recanalization failure (21%)
- ✓ E. Vascular occlusion (28%)

Omitted
Correct answer
E

28%
Answered correctly

01 sec
Time Spent

02/01/2020
Last Updated

Explanation

Intestinal atresias			
	Duodenal	Jejunum/Ileum	Colonic

Intestinal atresias			
	Duodenal	**Jejunum/Ileum**	**Colonic**
Pathophysiology	• Failure of recanalization at 8-10 weeks gestation	• Vascular injury	• Unknown
Clinical findings	• Bilious or nonbilious emesis • **Double-bubble** sign on x-ray	• **Bilious** emesis • Abdominal distension	• Constipation • Abdominal distension
Associations	• **Down syndrome**	• Gastroschisis	• Hirschsprung disease

©UWorld

Bilious emesis in a neonate is a sign of intestinal **obstruction below** the second part of the duodenum. The differential diagnosis includes midgut volvulus, which is a surgical emergency and must be excluded definitively. Other causes include **intestinal stenosis** and **atresia**. The more distal the atresia, the more likely it is to present with abdominal distension rather than bilious emesis. The absence of a segment of jejunum and ileum in this case confirms that the infant's condition is due to intestinal atresia.

Intestinal atresias of the midgut (eg, jejunum, ileum, proximal colon) are the result of **vascular occlusion** in utero. Diminished intestinal perfusion leads to ischemia of a segment of bowel, with subsequent narrowing (stenosis) or obliteration (atresia) of the lumen. If a major vessel (eg, the superior mesenteric artery) is occluded, the area of intestinal necrosis is large. The result is a proximal segment that ends in a blind pouch; followed by an area of absent small bowel and associated dorsal mesentery; and, finally, a distal segment of ileum that assumes a **spiral configuration** around an ileocolic vessel. This specific pattern is known as an "apple-peel" or "Christmas tree" deformity.

Bilious emesis in a neonate is a sign of intestinal **obstruction below** the second part of the duodenum. The differential diagnosis includes midgut volvulus, which is a surgical emergency and must be excluded definitively. Other causes include **intestinal stenosis** and **atresia**. The more distal the atresia, the more likely it is to present with abdominal distension rather than bilious emesis. The absence of a segment of jejunum and ileum in this case confirms that the infant's condition is due to intestinal atresia.

Intestinal atresias of the midgut (eg, jejunum, ileum, proximal colon) are the result of **vascular occlusion** in utero. Diminished intestinal perfusion leads to ischemia of a segment of bowel, with subsequent narrowing (stenosis) or obliteration (atresia) of the lumen. If a major vessel (eg, the superior mesenteric artery) is occluded, the area of intestinal necrosis is large. The result is a proximal segment that ends in a blind pouch; followed by an area of absent small bowel and associated dorsal mesentery; and, finally, a distal segment of ileum that assumes a **spiral configuration** around an ileocolic vessel. This specific pattern is known as an "apple-peel" or "Christmas tree" deformity.

(Choice A) Improper rotation of the developing gut and the mesentery can lead to malrotation and subsequent midgut volvulus. The presentation of midgut volvulus (bilious emesis) is similar to intestinal atresia. However, the surgical findings in this case (atresia rather than malrotation) rule out midgut volvulus.

(Choice B) Hirschsprung disease results from the failure of neural crest cells to migrate into the distal colonic wall. Without neural crest cells, submucosal and myenteric plexi do not develop and the distal colon becomes nonfunctional. Affected infants have intestinal obstruction and failure to pass stool.

(Choice C) Failure of the tracheoesophageal septum to partition the foregut into the esophagus and the trachea during the 4th-5th week of gestation leads to tracheoesophageal fistula.

(Choice D) Duodenal atresia occurs when the duodenal lumen fails to recanalize after endothelial proliferation during the 8th-10th week of gestation. Recanalization failure is not the cause of atresia or stenosis in the distal gut; distal atresias are due to vascular injury.

Educational objective:
Intestinal atresia distal to the duodenum occurs due to vascular accidents in utero. "Apple-peel" atresia occurs when the superior mesenteric artery is obstructed. The result is a blind-ending proximal jejunum; a length of absent bowel and mesentery; and, finally, a terminal ileum spiraled around an ileocolic vessel.

References

superior mesenteric artery) is occluded, the area of intestinal necrosis is large. The result is a proximal segment that ends in a blind pouch; followed by an area of absent small bowel and associated dorsal mesentery; and, finally, a distal segment of ileum that assumes a **spiral configuration** around an ileocolic vessel. This specific pattern is known as an "apple-peel" or "Christmas tree" deformity.

(Choice A) Improper rotation of the developing gut and the mesentery can lead to malrotation and subsequent midgut volvulus. The presentation of midgut volvulus (bilious emesis) is similar to intestinal atresia. However, the surgical findings in this case (atresia rather than malrotation) rule out midgut volvulus.

(Choice B) Hirschsprung disease results from the failure of neural crest cells to migrate into the distal colonic wall. Without neural crest cells, submucosal and myenteric plexi do not develop and the distal colon becomes nonfunctional. Affected infants have intestinal obstruction and failure to pass stool.

(Choice C) Failure of the tracheoesophageal septum to partition the foregut into the esophagus and the trachea during the 4th-5th week of gestation leads to tracheoesophageal fistula.

(Choice D) Duodenal atresia occurs when the duodenal lumen fails to recanalize after endothelial proliferation during the 8th-10th week of gestation. Recanalization failure is not the cause of atresia or stenosis in the distal gut; distal atresias are due to vascular injury.

Educational objective:
Intestinal atresia distal to the duodenum occurs due to vascular accidents in utero. "Apple-peel" atresia occurs when the superior mesenteric artery is obstructed. The result is a blind-ending proximal jejunum; a length of absent bowel and mesentery; and, finally, a terminal ileum spiraled around an ileocolic vessel.

References

- Apple peel small bowel.

Embryology	Gastrointestinal & Nutrition	Intestinal atresia
Subject	System	Topic

Copyright © UWorld. All rights reserved.

superior mesenteric artery) is occluded, the area of intestinal necrosis is large. The result is a proximal segment that ends in a blind pouch;

Exhibit Display

Apple peel atresia

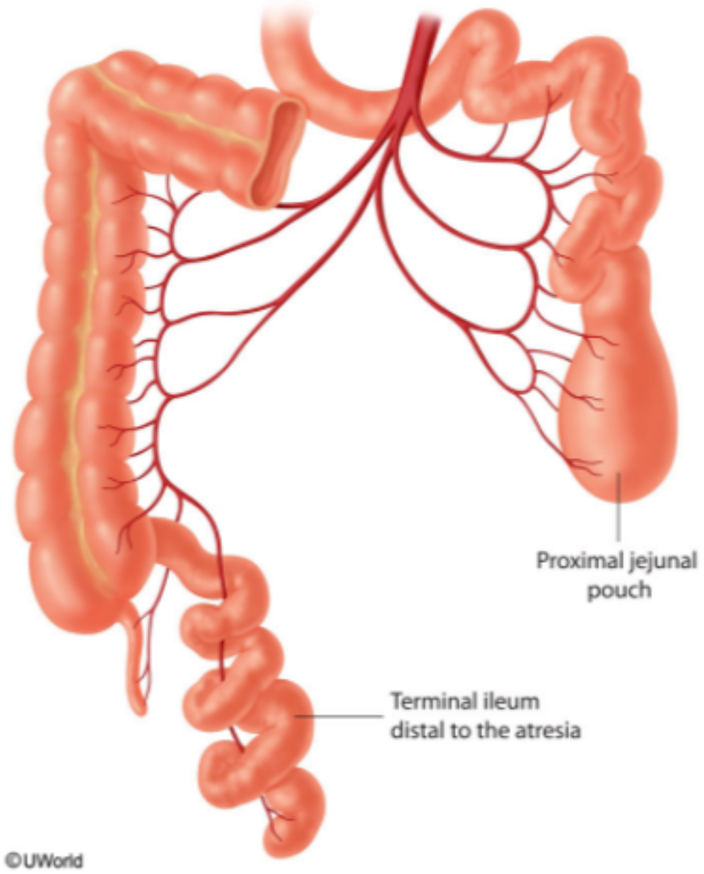

Zoom In | Zoom Out | Reset | Add To New Card | Existing Card

superior mesenteric artery) is occluded, the area of intestinal necrosis is large. The result is a proximal segment that ends in a blind pouch;

Exhibit Display

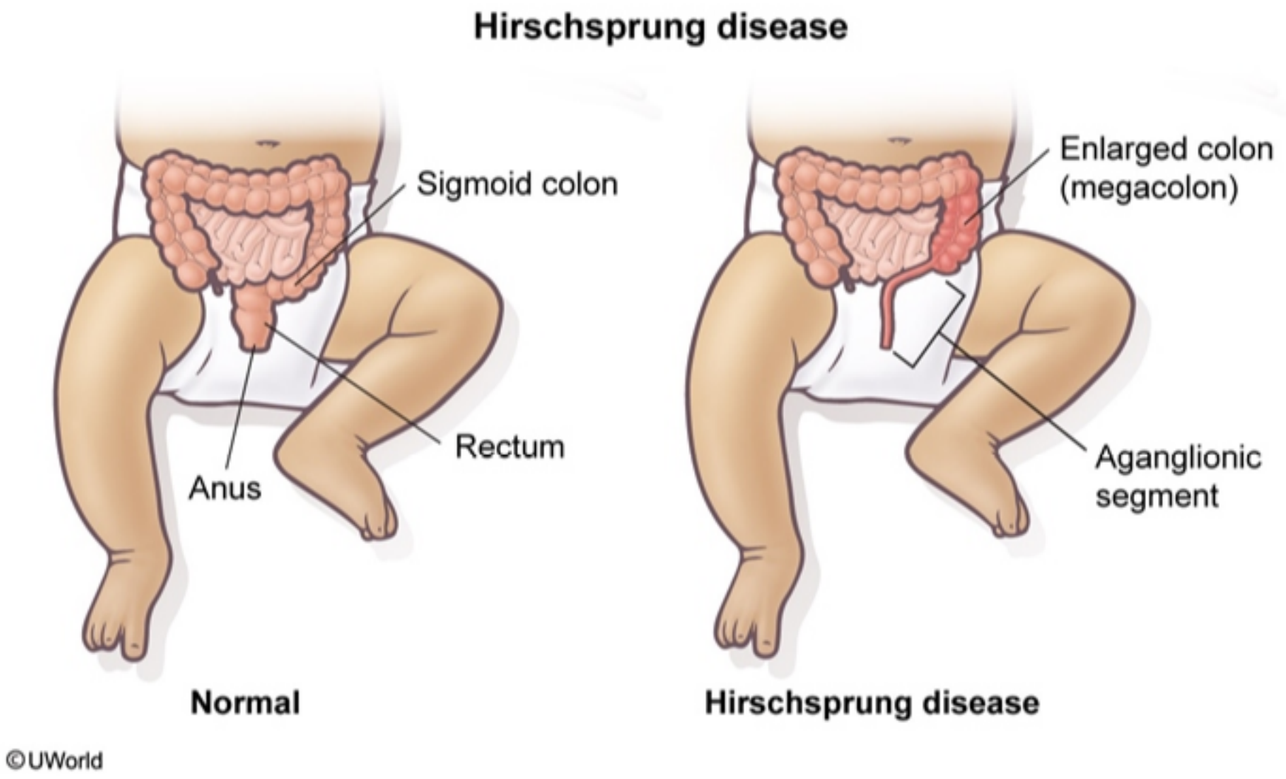

Zoom In Zoom Out Reset Add To New Card | Existing Card

superior mesenteric artery) is occluded, the area of intestinal necrosis is large. The result is a proximal segment that ends in a blind pouch;

Exhibit Display

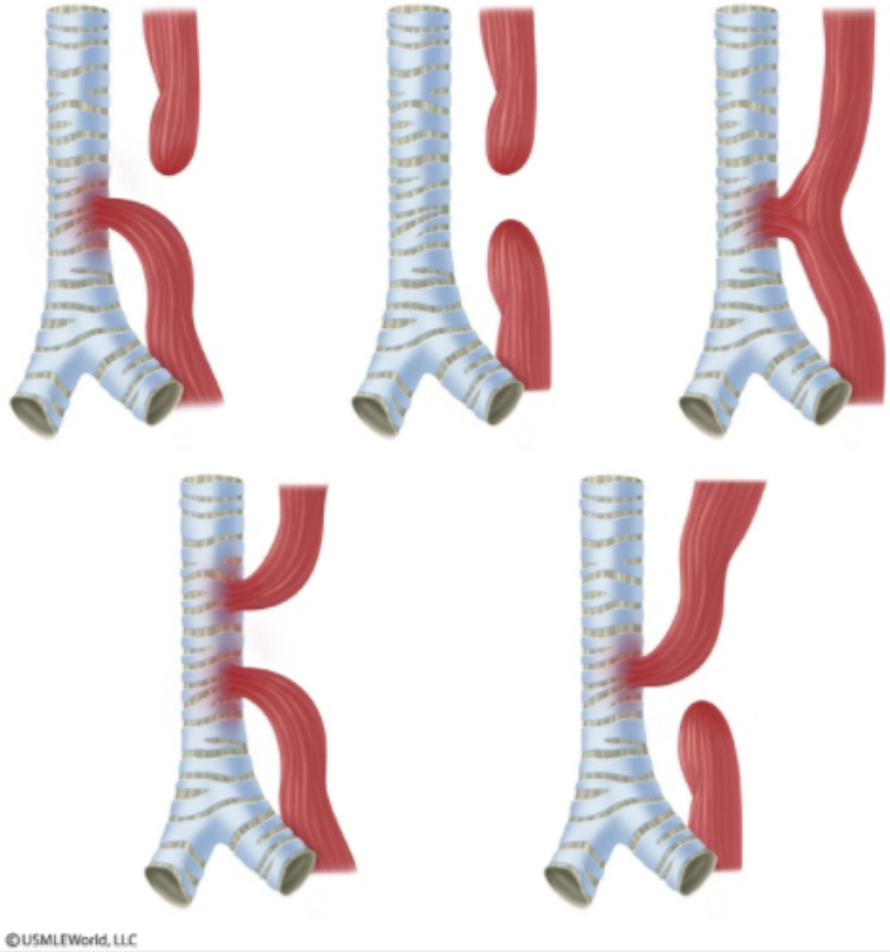

Zoom In | Zoom Out | Reset | Add To New Card | Existing Card

A 15-year-old girl is brought in for evaluation of amenorrhea. She has never menstruated, but her mother had menarche at age 14. The patient has no other medical problems or allergies. She takes no medications and does not use tobacco, alcohol, or drugs. The patient plays the violin for her high school orchestra and is the captain of her junior varsity tennis team. She is not sexually active. Her height is 175 cm (5 ft 8 in), weight is 65 kg (143 lb), and BMI is 21.2 kg/m^2. Examination shows fully developed secondary sexual characteristics. Pelvic ultrasound shows a shortened vaginal canal with a rudimentary uterus. Which of the following is the most likely diagnosis in this patient?

- A. 21-hydroxylase deficiency
- B. Androgen insensitivity syndrome
- C. Kallmann syndrome
- D. Klinefelter syndrome
- E. Müllerian aplasia
- F. Triple X syndrome

Submit

A 15-year-old girl is brought in for evaluation of amenorrhea. She has never menstruated, but her mother had menarche at age 14. The patient has no other medical problems or allergies. She takes no medications and does not use tobacco, alcohol, or drugs. The patient plays the violin for her high school orchestra and is the captain of her junior varsity tennis team. She is not sexually active. Her height is 175 cm (5 ft 8 in), weight is 65 kg (143 lb), and BMI is 21.2 kg/m^2. Examination shows fully developed secondary sexual characteristics. Pelvic ultrasound shows a shortened vaginal canal with a rudimentary uterus. Which of the following is the most likely diagnosis in this patient?

- A. 21-hydroxylase deficiency (3%)
- B. Androgen insensitivity syndrome (24%)
- C. Kallmann syndrome (6%)
- D. Klinefelter syndrome (3%)
- ✓ E. Müllerian aplasia (58%)
- F. Triple X syndrome (3%)

Omitted
Correct answer
E

58%
Answered correctly

02 secs
Time Spent

01/15/2020
Last Updated

Explanation

Genital development

Undifferentiated gonad

Genital development

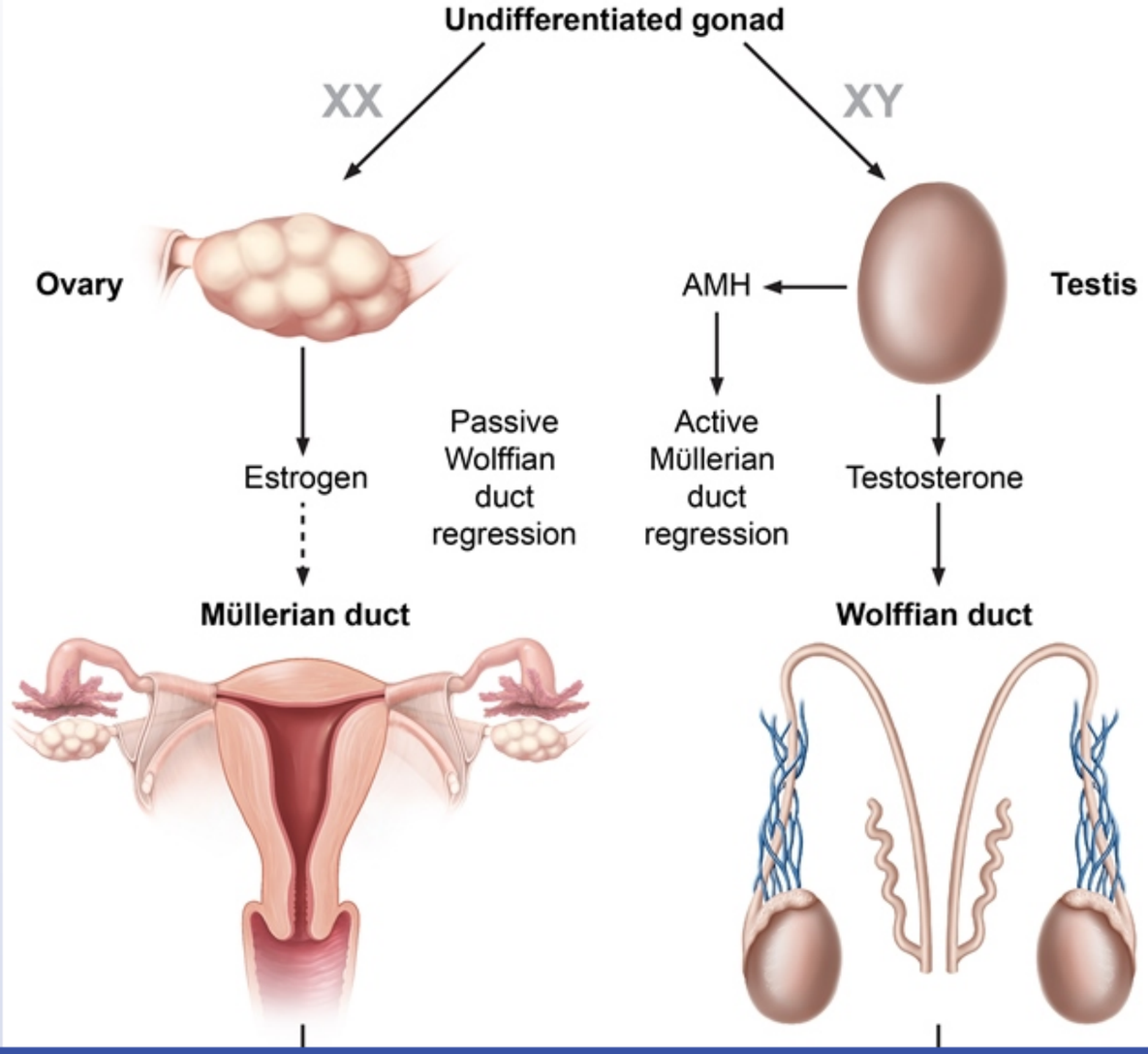

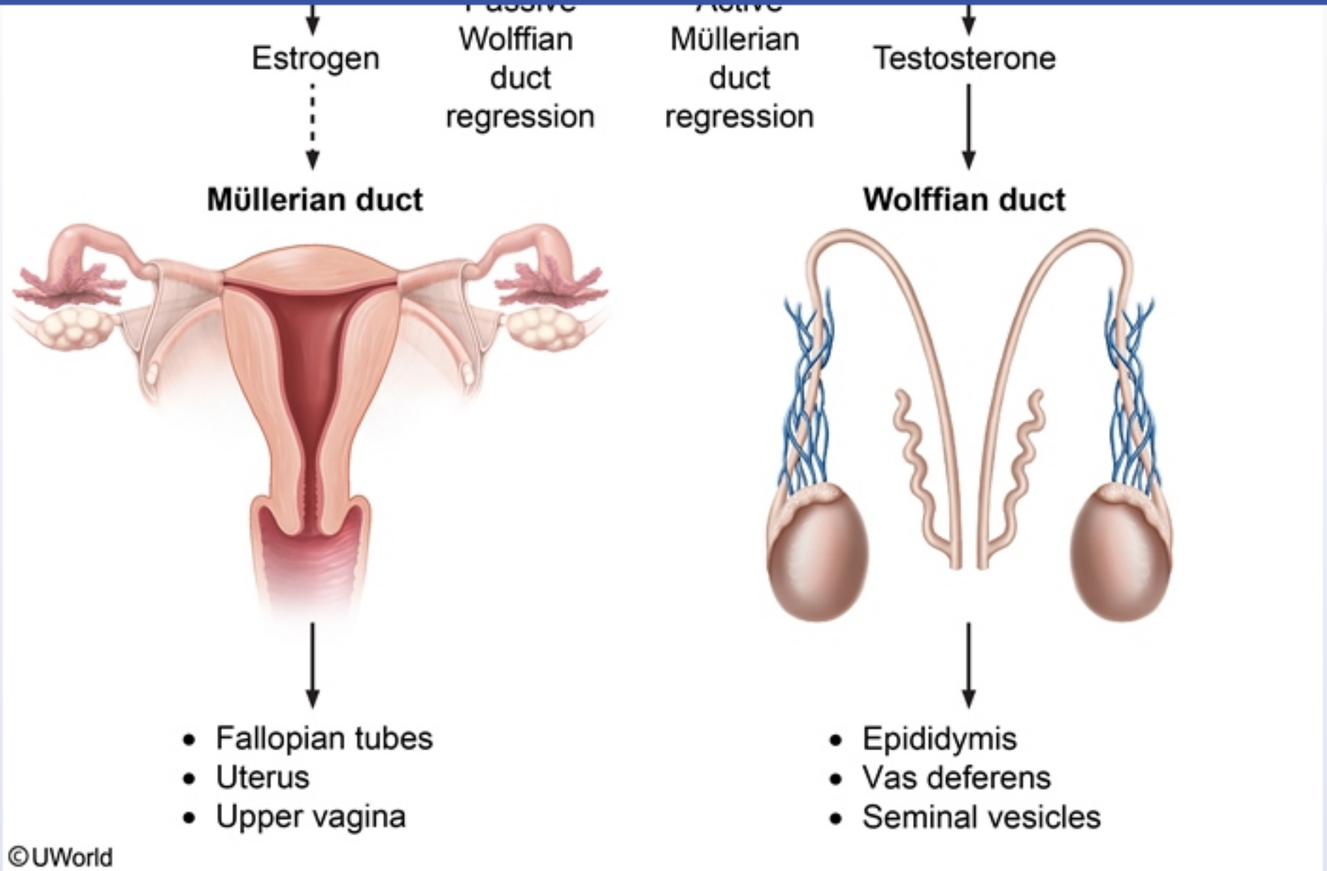

The sexually undifferentiated embryo at <6 weeks gestation has 2 pairs of genital ducts: the paramesonephric (Müllerian) ducts and the mesonephric (Wolffian) ducts. In the normal female (XX) fetus, the Müllerian ducts give rise to the fallopian tubes, uterus, cervix, and upper vagina by 20 weeks gestation. The Wolffian ducts degenerate from the lack of hormonal stimulation.

This patient is most likely a 46,XX female with Müllerian aplasia, also known as vaginal agenesis or Mayer-Rokitansky-Küster-Hauser (MRKH) syndrome. Aplasia is defined as defective development or congenital absence of an organ or tissue, and patients with MRKH have **variable uterine development** and **no upper vagina** (eg, short vagina). As the uterus is hypoplastic or absent, the patient cannot menstruate (eg,

©UWorld

The sexually undifferentiated embryo at <6 weeks gestation has 2 pairs of genital ducts: the paramesonephric (Müllerian) ducts and the mesonephric (Wolffian) ducts. In the normal female (XX) fetus, the Müllerian ducts give rise to the fallopian tubes, uterus, cervix, and upper vagina by 20 weeks gestation. The Wolffian ducts degenerate from the lack of hormonal stimulation.

This patient is most likely a 46,XX female with Müllerian aplasia, also known as vaginal agenesis or Mayer-Rokitansky-Küster-Hauser (MRKH) syndrome. Aplasia is defined as defective development or congenital absence of an organ or tissue, and patients with MRKH have **variable uterine development** and **no upper vagina** (eg, short vagina). As the uterus is hypoplastic or absent, the patient cannot menstruate (eg, **primary amenorrhea**). Patients with MRKH have **normal ovaries**, which secrete estrogen normally and enable **regular development of secondary sexual characteristics** (eg, breast, pubic hair).

Other Müllerian defects may result from inappropriate fusion of the Müllerian ducts (eg, unicornuate, bicornuate, and septate uterus). All females with Müllerian defects should undergo renal ultrasound, as up to 50% will have a coexisting urologic anomaly (eg, unilateral **renal agenesis**).

(Choice A) Congenital adrenal hyperplasia is most commonly due to 21-hydroxylase deficiency and has a variable presentation depending on the severity of the enzyme deficiency. Neonates typically have virilization and life-threatening hyponatremia (salt-wasting). Late-onset 21-hydroxylase deficiency usually presents as hirsutism, oligomenorrhea, and acne.

(Choice B) Patients with androgen insensitivity syndrome (AIS) are 46,XY males who appear phenotypically female due to an androgen receptor defect. In contrast to patients with MRKH, patients with AIS have minimal axillary or pubic hair due to androgen resistance. In addition, patients with AIS have cryptorchid testes and no uterus or ovaries.

(Choice C) Kallmann syndrome occurs due to decreased synthesis of gonadotropin-releasing hormone (GnRH) in the hypothalamus (hypogonadotropic hypogonadism). Although females are rarely affected, those with the condition present with primary amenorrhea, no secondary sexual characteristics, and an olfactory sensory defect.

(Choice D) Klinefelter syndrome (47,XXY) affects males and is characterized by tall stature, poorly developed secondary sexual characteristics, atrophic testes, and infertility.

(Choice F) Patients with a 47,XXX karyotype may have a tall stature and slightly decreased IQ scores. Physical features are typically normal, including sexual development

(Choice A) Congenital adrenal hyperplasia is most commonly due to 21-hydroxylase deficiency and has a variable presentation depending on the severity of the enzyme deficiency. Neonates typically have virilization and life-threatening hyponatremia (salt-wasting). Late-onset 21-hydroxylase deficiency usually presents as hirsutism, oligomenorrhea, and acne.

(Choice B) Patients with androgen insensitivity syndrome (AIS) are 46,XY males who appear phenotypically female due to an androgen receptor defect. In contrast to patients with MRKH, patients with AIS have minimal axillary or pubic hair due to androgen resistance. In addition, patients with AIS have cryptorchid testes and no uterus or ovaries.

(Choice C) Kallmann syndrome occurs due to decreased synthesis of gonadotropin-releasing hormone (GnRH) in the hypothalamus (hypogonadotropic hypogonadism). Although females are rarely affected, those with the condition present with primary amenorrhea, no secondary sexual characteristics, and an olfactory sensory defect.

(Choice D) Klinefelter syndrome (47,XXY) affects males and is characterized by tall stature, poorly developed secondary sexual characteristics, atrophic testes, and infertility.

(Choice F) Patients with a 47,XXX karyotype may have a tall stature and slightly decreased IQ scores. Physical features are typically normal, including sexual development.

Educational objective:
Patients with Müllerian aplasia (ie, Mayer-Rokitansky-Küster-Hauser syndrome) have no upper vagina (eg, short vagina) and variable uterine development. These patients are 46,XX females with normal ovaries and secondary sexual characteristics.

References

- ACOG Committee opinion: no. 562: müllerian agenesis: diagnosis, management, and treatment.
- Amenorrhea: an approach to diagnosis and management.

Embryology	Female Reproductive System & Breast	Amenorrhea
Subject	System	Topic

Copyright © UWorld. All rights reserved.

Exhibit Display

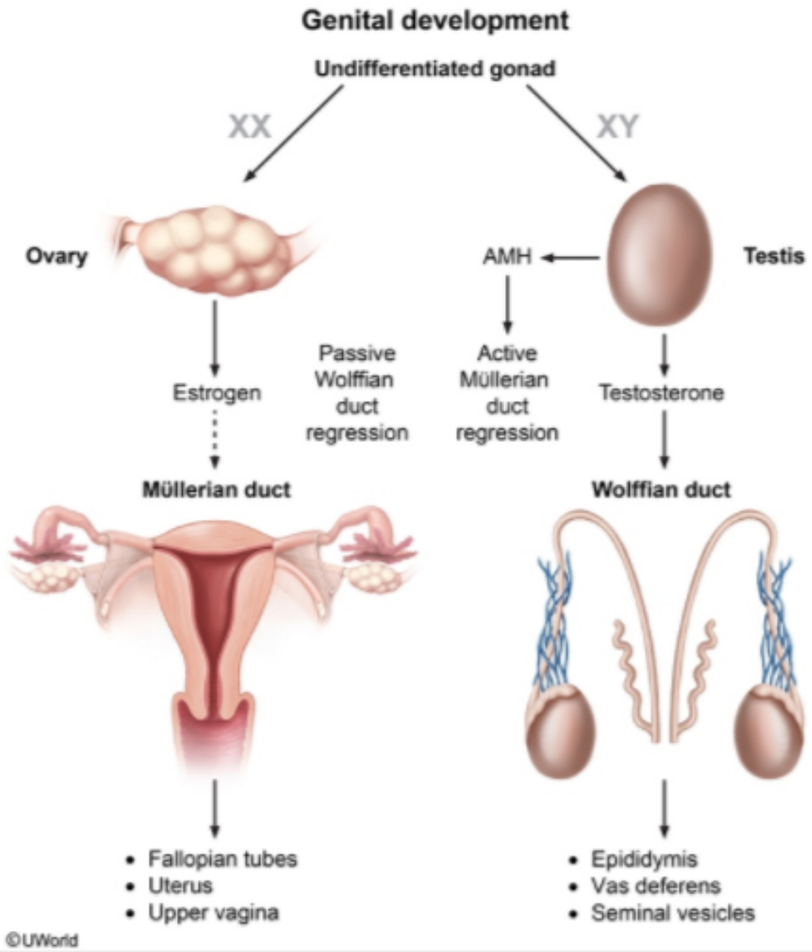

Zoom In | Zoom Out | Reset | Add To New Card | Existing Card

secondary sexual characteristics (eg, breast, pubic hair).

uterine development and **no upper vagina** (eg, short vagina). As the uterus is hypoplastic or absent, the patient cannot menstruate (eg,

Exhibit Display

Androgen insensitivity syndrome

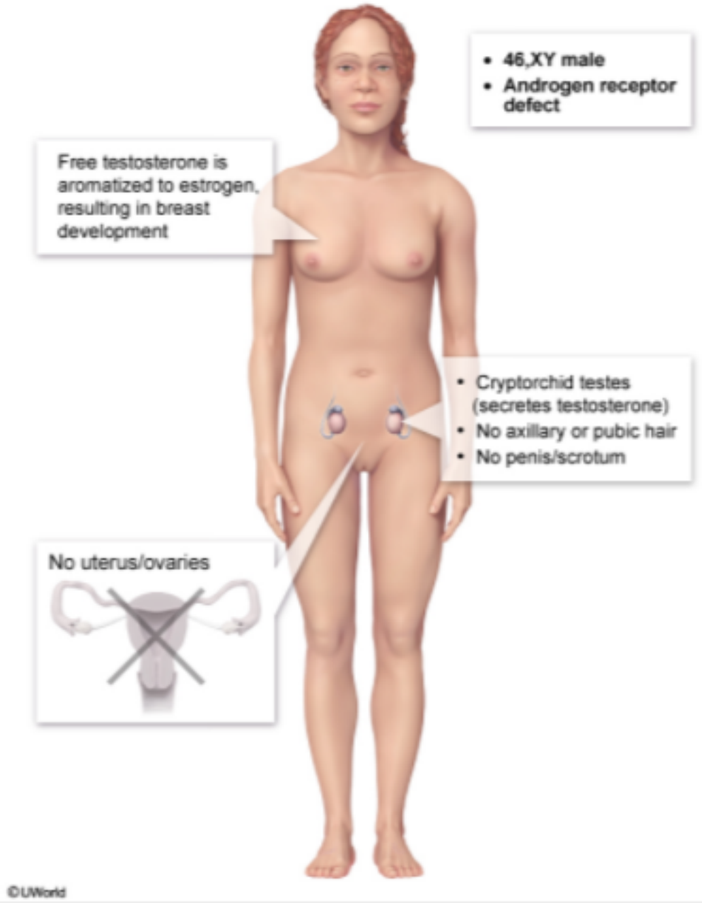

Zoom In | Zoom Out | Reset | Add To New Card | Existing Card

1 2 3 4 5 6 7 8 9 10 11 12 13 14 15 16 17 18 19 20 21 22 23 24 25 26 27 28 29 30

uterine development and **no upper vagina** (eg, short vagina). As the uterus is hypoplastic or absent, the patient cannot menstruate (eg,

Exhibit Display

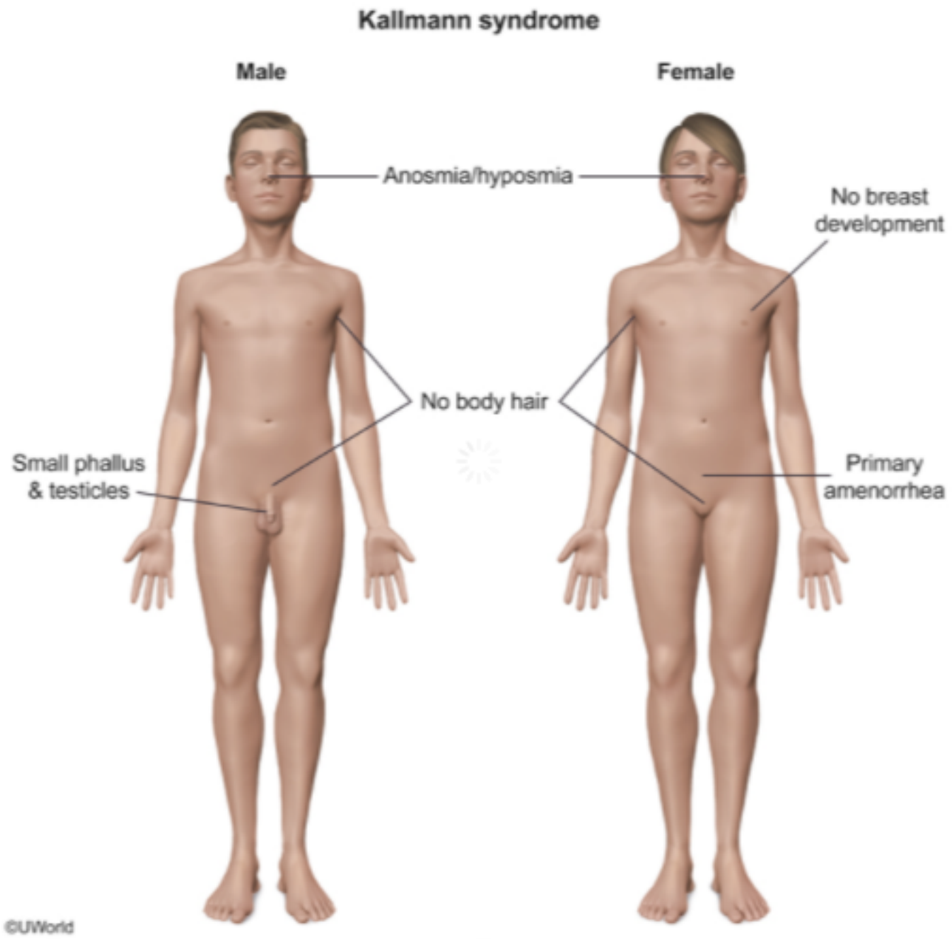

Zoom In | Zoom Out | Reset | Add To New Card | Existing Card

1 2 3 4 5 6 7 8 9 10 11 12 13 14 15 16 17 18 19 20 21 22 23 24 25 26 27 28 29 30

uterine development and **no upper vagina** (eg, short vagina). As the uterus is hypoplastic or absent, the patient cannot menstruate (eg,

Exhibit Display

Klinefelter syndrome (47,XXY)

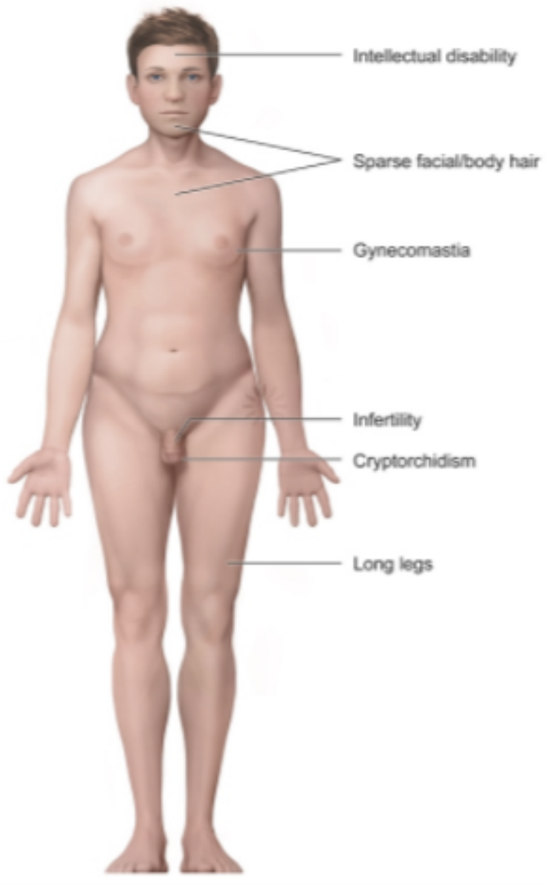

Zoom In | Zoom Out | Reset | Add To New Card | Existing Card

(Choice A) Congenital adrenal hyperplasia is most commonly due to 21-hydroxylase deficiency and has a variable presentation depending on the severity of the enzyme deficiency. Neonates typically have virilization and life-threatening hyponatremia (salt-wasting). Late-onset 21-hydroxylase deficiency usually presents as hirsutism, oligomenorrhea, and acne.

(Choice B) Patients with androgen insensitivity syndrome (AIS) are 46,XY males who appear phenotypically female due to an androgen receptor defect. In contrast to patients with MRKH, patients with AIS have minimal axillary or pubic hair due to androgen resistance. In addition, patients with AIS have cryptorchid testes and no uterus or ovaries.

(Choice C) Kallmann syndrome occurs due to decreased synthesis of gonadotropin-releasing hormone (GnRH) in the hypothalamus (hypogonadotropic hypogonadism). Although females are rarely affected, those with the condition present with primary amenorrhea, no secondary sexual characteristics, and an olfactory sensory defect.

(Choice D) Klinefelter syndrome (47,XXY) affects males and is characterized by tall stature, poorly developed secondary sexual characteristics, atrophic testes, and infertility.

(Choice F) Patients with a 47,XXX karyotype may have a tall stature and slightly decreased IQ scores. Physical features are typically normal, including sexual development.

Educational objective:
Patients with Müllerian aplasia (ie, Mayer-Rokitansky-Küster-Hauser syndrome) have no upper vagina (eg, short vagina) and variable uterine development. These patients are 46,XX females with normal ovaries and secondary sexual characteristics.

References

- ACOG Committee opinion: no. 562: müllerian agenesis: diagnosis, management, and treatment.
- Amenorrhea: an approach to diagnosis and management.

Embryology	Female Reproductive System & Breast	Amenorrhea
Subject	System	Topic

Copyright © UWorld. All rights reserved.

Five measurements of blood oxygen saturation taken in a fetus are: 67, 61, 56, 52 and 31%. The highest value is most likely recorded in which of the following vessels?

A. Ductus arteriosus

B. Superior vena cava

C. Inferior vena cava

D. Pulmonary trunk

E. Descending aorta

F. Umbilical artery

Submit

Five measurements of blood oxygen saturation taken in a fetus are: 67, 61, 56, 52 and 31%. The highest value is most likely recorded in which of the following vessels?

A. Ductus arteriosus (11%)
B. Superior vena cava (3%)
✓ C. Inferior vena cava (65%)
D. Pulmonary trunk (3%)
E. Descending aorta (3%)
F. Umbilical artery (12%)

Omitted
Correct answer
C

65%
Answered correctly

02 secs
Time Spent

02/03/2020
Last Updated

Explanation

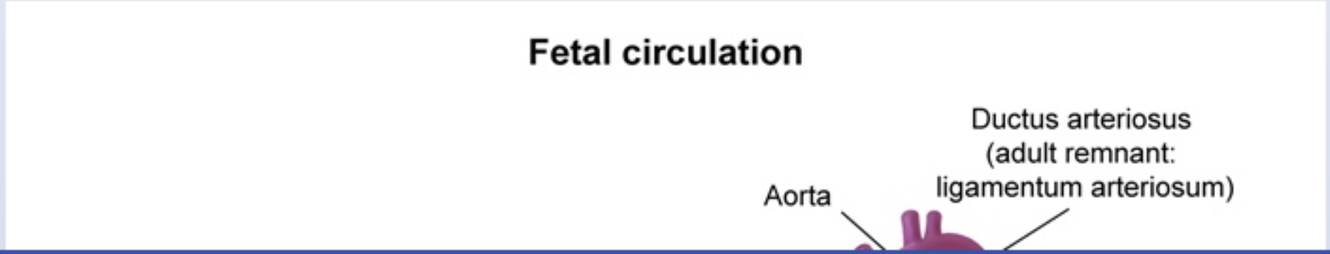

Fetal circulation

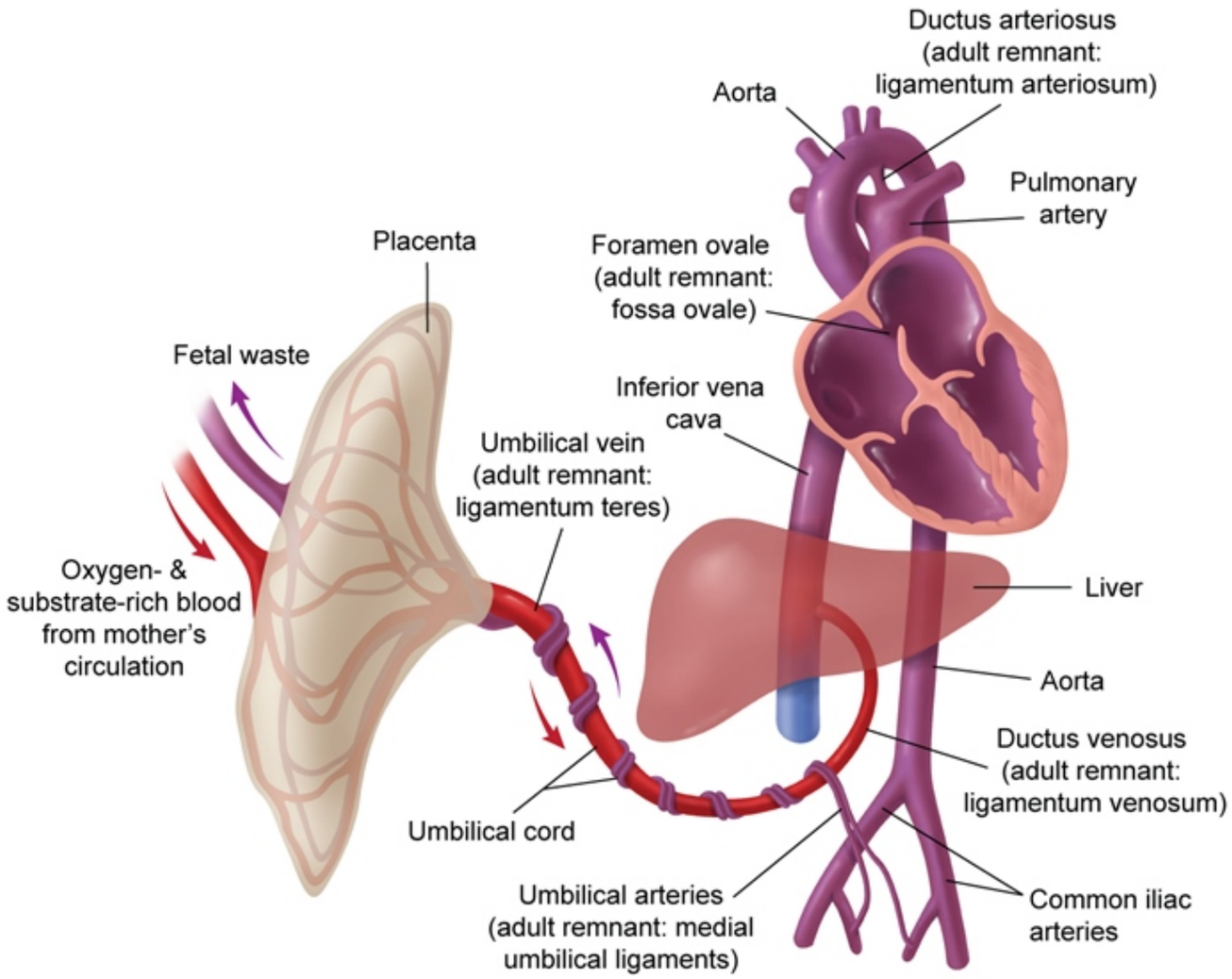

©UWorld

The fetal circulation differs considerably from the adult circulation. Oxygenated blood from the placenta is delivered to the fetus via the umbilical vein. Thus the umbilical vein has the highest oxygen content in the fetal circulation. (The ligamentum teres is the remnant of the umbilical vein in the adult.) Blood from the umbilical vein is first delivered to the liver, where it bypasses the hepatic circulation via the ductus venosus and enters the inferior vena cava (IVC). Thus, of the choices listed, the IVC has the highest oxygen content. From the IVC, blood is delivered to the heart where it is either pumped into the pulmonary circulation or crosses directly from the right heart to the left heart via the foramen ovale. A fraction of the blood pumped into the pulmonary circulation may bypass the lungs via the ductus arteriosus and pass directly into the descending aorta. From the aorta, blood circulates to all of the fetal tissues. Deoxygenated blood is delivered from the fetus back to the placenta by the paired umbilical arteries.

(Choice A) The ductus arteriosus shunts blood from the pulmonary artery into the descending aorta. This blood is mixed with completely deoxygenated blood from the systemic circulation. In the adult, the ductus arteriosus becomes a fibrotic band, the ligamentum arteriosum.

(Choice B) The superior vena cava does not participate in the circulation of oxygenated blood in the fetus; it contains only deoxygenated blood returning from the fetal head and upper extremities.

(Choice D) The pulmonary trunk contains a mixture of oxygenated and deoxygenated blood that it delivers both to the fetal lungs and to the descending aorta via the ductus arteriosus.

(Choice E) The descending aorta contains the same partially deoxygenated blood that is present in the fetal heart and pulmonary trunk. It delivers this blood to the fetal tissues and then to the umbilical arteries for reoxygenation.

(Choice F) The umbilical arteries originate from the fetal internal iliac arteries and carry deoxygenated blood back to the placenta via the umbilical cord.

Educational Objective:
The most highly oxygenated blood in the fetus is carried by the umbilical vein, which empties directly into the inferior vena cava via the ductus venosus.

Embryology | Pulmonary & Critical Care | Fetal circulation

the adult.) Blood from the umbilical vein is first delivered to the liver, where it bypasses the hepatic circulation via the ductus venosus and enters the inferior vena cava (IVC). Thus, of the choices listed, the IVC has the highest oxygen content. From the IVC, blood is delivered to the heart where it is either pumped into the pulmonary circulation or crosses directly from the right heart to the left heart via the foramen ovale. A fraction of the blood pumped into the pulmonary circulation may bypass the lungs via the ductus arteriosus and pass directly into the descending aorta. From the aorta, blood circulates to all of the fetal tissues. Deoxygenated blood is delivered from the fetus back to the placenta by the paired umbilical arteries.

(Choice A) The ductus arteriosus shunts blood from the pulmonary artery into the descending aorta. This blood is mixed with completely deoxygenated blood from the systemic circulation. In the adult, the ductus arteriosus becomes a fibrotic band, the ligamentum arteriosum.

(Choice B) The superior vena cava does not participate in the circulation of oxygenated blood in the fetus; it contains only deoxygenated blood returning from the fetal head and upper extremities.

(Choice D) The pulmonary trunk contains a mixture of oxygenated and deoxygenated blood that it delivers both to the fetal lungs and to the descending aorta via the ductus arteriosus.

(Choice E) The descending aorta contains the same partially deoxygenated blood that is present in the fetal heart and pulmonary trunk. It delivers this blood to the fetal tissues and then to the umbilical arteries for reoxygenation.

(Choice F) The umbilical arteries originate from the fetal internal iliac arteries and carry deoxygenated blood back to the placenta via the umbilical cord.

Educational Objective:
The most highly oxygenated blood in the fetus is carried by the umbilical vein, which empties directly into the inferior vena cava via the ductus venosus.

Embryology	Pulmonary & Critical Care	Fetal circulation
Subject	System	Topic

Copyright © UWorld. All rights reserved.

1 2 3 4 5 6 7 8 9 10 11 12 13 14 15 16 17 18 19 20 21 22 23 24 25 26 27 28 29 30

In normal female development, non-fusion of the urethral folds forms the labia minora and the vestibule of the vagina. In males, non-fusion of the urethral folds would most likely result in which of the following?

A. Bifid scrotum

B. Cryptorchidism

C. Epispadias

D. Hydrocele of the testis

E. Hypospadias

Submit

In normal female development, non-fusion of the urethral folds forms the labia minora and the vestibule of the vagina. In males, non-fusion of the urethral folds would most likely result in which of the following?

- A. Bifid scrotum (9%)
- B. Cryptorchidism (1%)
- C. Epispadias (11%)
- D. Hydrocele of the testis (1%)
- ✓ E. Hypospadias (77%)

Omitted
Correct answer
E

77%
Answered correctly

01 sec
Time Spent

04/16/2020
Last Updated

Explanation

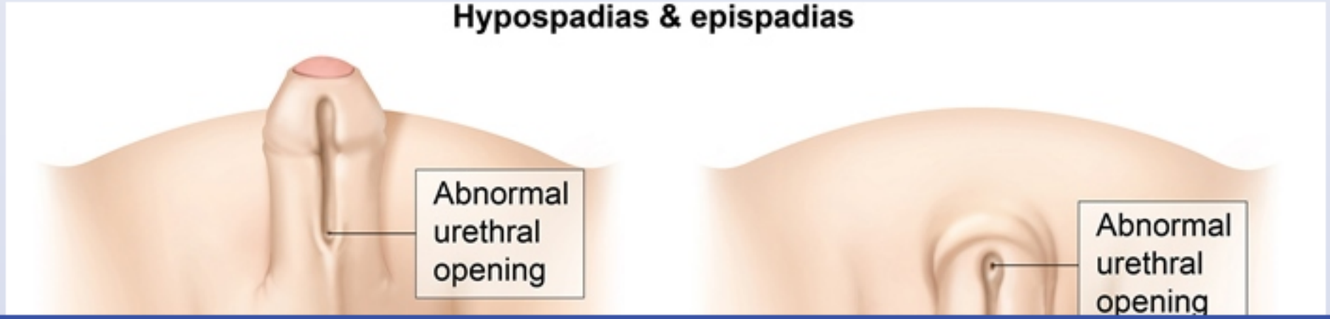

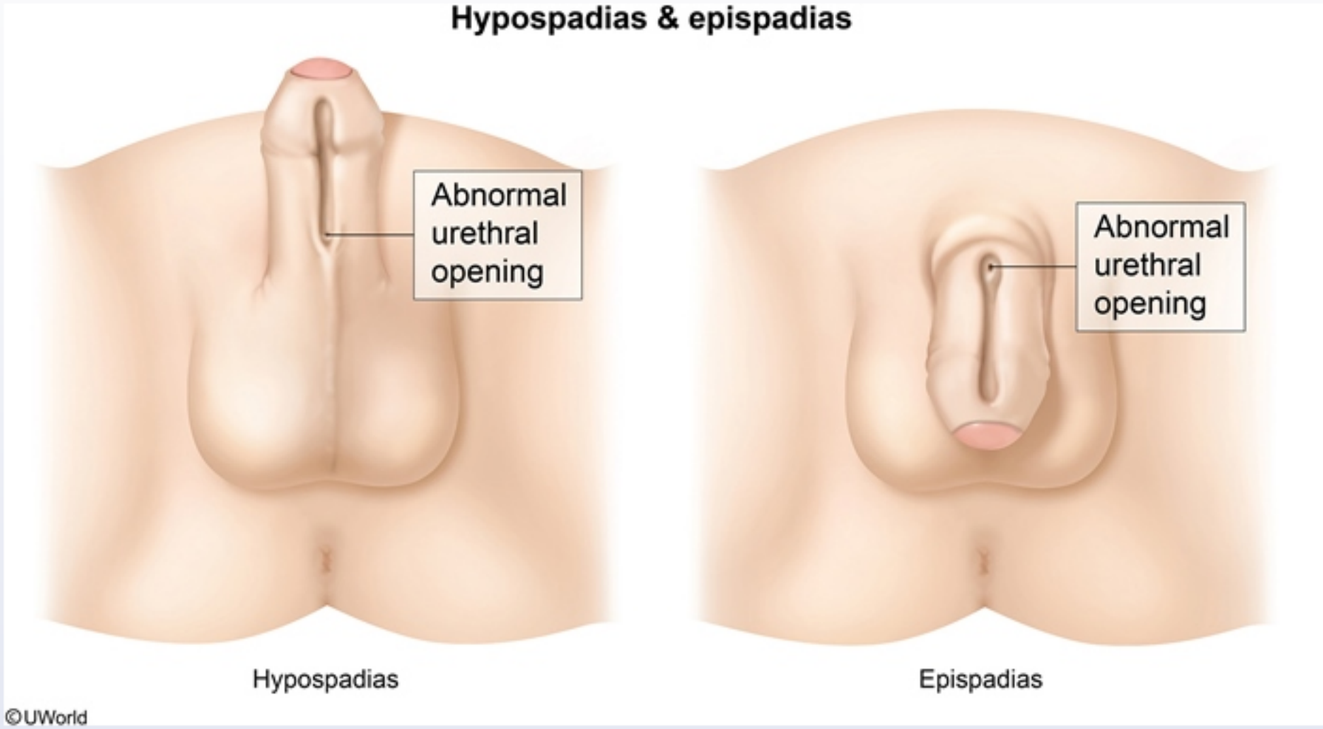

Differentiation and development of the external genitalia occurs during **weeks 8-15** of gestation. In females, the urethral (urogenital) folds do not fuse and ultimately form the labia minora and the vestibule of the vagina. In males, the urethral folds fuse to form the ventral aspect of the penis and the penile raphe, which serve as the anterior wall of the urethra.

Incomplete fusion of these folds in a male would result in an **abnormal opening** of the urethra at a location proximal to the distal tip of the glans penis. Depending on the degree of nonunion, the urethral opening can be anywhere from the perineum to just proximal to the glans penis. This condition is known as **hypospadias** and can generally be repaired surgically to allow normal urination and sexual activity.

(Choice A) A bifid scrotum (two separate sacs) results from malunion of the labioscrotal folds. In females, the labioscrotal swellings form the labia majora.

©UWorld

Differentiation and development of the external genitalia occurs during **weeks 8-15** of gestation. In females, the urethral (urogenital) folds do not fuse and ultimately form the labia minora and the vestibule of the vagina. In males, the urethral folds fuse to form the ventral aspect of the penis and the penile raphe, which serve as the anterior wall of the urethra.

Incomplete fusion of these folds in a male would result in an **abnormal opening** of the urethra at a location proximal to the distal tip of the glans penis. Depending on the degree of nonunion, the urethral opening can be anywhere from the perineum to just proximal to the glans penis. This condition is known as **hypospadias** and can generally be repaired surgically to allow normal urination and sexual activity.

(Choice A) A bifid scrotum (two separate sacs) results from malunion of the labioscrotal folds. In females, the labioscrotal swellings form the labia majora.

(Choice B) Cryptorchidism is failure of a fetal testis to descend into the scrotum. Most undescended testes will descend spontaneously by the time the infant is 4 months old.

(Choice C) The genital tubercle becomes the glans penis in males and the clitoris in females. Epispadias is an abnormal opening of the urethra on the dorsal surface of the penile shaft that results from faulty positioning of the genital tubercle in the fifth week of gestation.

(Choice D) The processus vaginalis is a projection of the peritoneal cavity that accompanies the descending testis into the scrotum and ultimately forms the tunica vaginalis of the testis. Hydrocele is development of a fluid-filled peritoneal sac within the scrotum that results from incomplete obliteration of the processus vaginalis.

Educational objective:
In males, incomplete fusion of the urethral (urogenital) folds results in hypospadias, an abnormal opening of the urethra proximal to the glans penis along the ventral shaft of the penis.

Embryology	Male Reproductive System	Hypospadia and epispadia
Subject	System	Topic

Copyright © UWorld. All rights reserved.

©UWorld

Exhibit Display

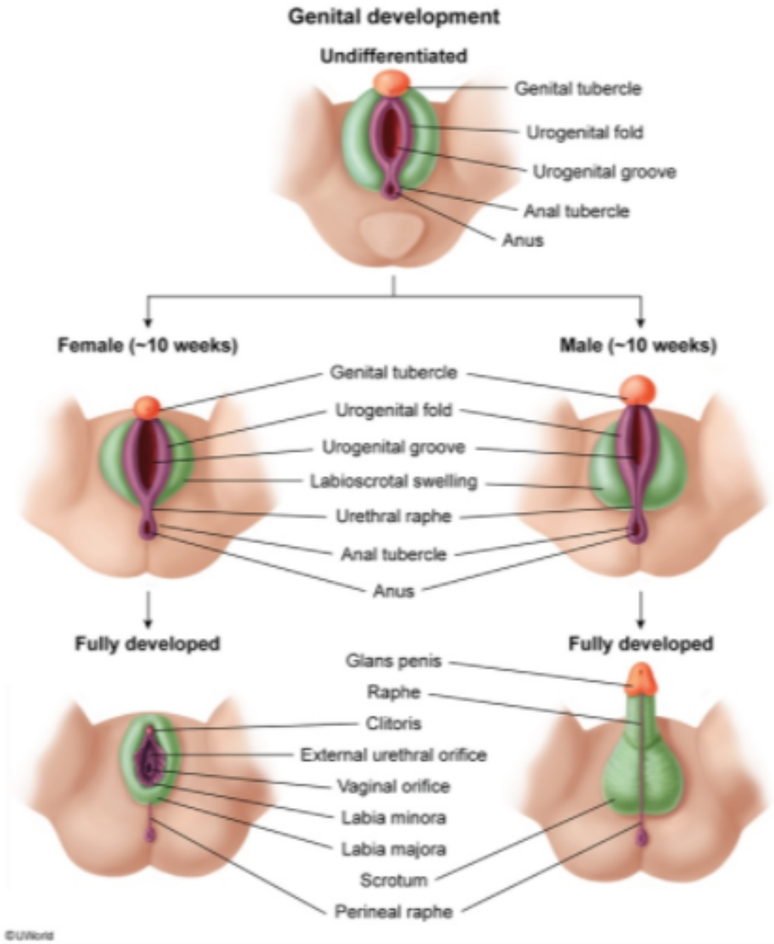

Zoom In | Zoom Out | Reset | Add To New Card | Existing Card

A 32-year-old woman, gravida 2 para 1, with an uncomplicated prenatal course delivered a 4.1-kg (9-lb) newborn at 39 weeks gestation via spontaneous vaginal delivery. Apgar scores were 8 and 10 at 1 and 5 minutes, respectively. Further evaluation in the newborn nursery shows abnormal sexual differentiation. Karyotype analysis shows a 46,XY genotype. Biopsy of gonadal tissue shows a lack of Sertoli cells but normally functioning Leydig cells. Which of the following phenotypes is most likely to be present?

	Internal reproductive organs	External genitalia
A.	Female	Female and Male
B.	Female	Male
C.	Female and Male	Female
D.	Female and Male	Male
E.	Male	Female and Male
F.	Male	Male

Submit

A 32-year-old woman, gravida 2 para 1, with an uncomplicated prenatal course delivered a 4.1-kg (9-lb) newborn at 39 weeks gestation via spontaneous vaginal delivery. Apgar scores were 8 and 10 at 1 and 5 minutes, respectively. Further evaluation in the newborn nursery shows abnormal sexual differentiation. Karyotype analysis shows a 46,XY genotype. Biopsy of gonadal tissue shows a lack of Sertoli cells but normally functioning Leydig cells. Which of the following phenotypes is most likely to be present?

	Internal reproductive organs	External genitalia
A. (4%)	Female	Female and Male
B. (12%)	Female	Male
C. (6%)	Female and Male	Female
✓ D. (41%)	Female and Male	Male
E. (24%)	Male	Female and Male
F. (9%)	Male	Male

Omitted
Correct answer
D

41%
Answered correctly

02 secs
Time Spent

02/05/2020
Last Updated

SRY gene expression

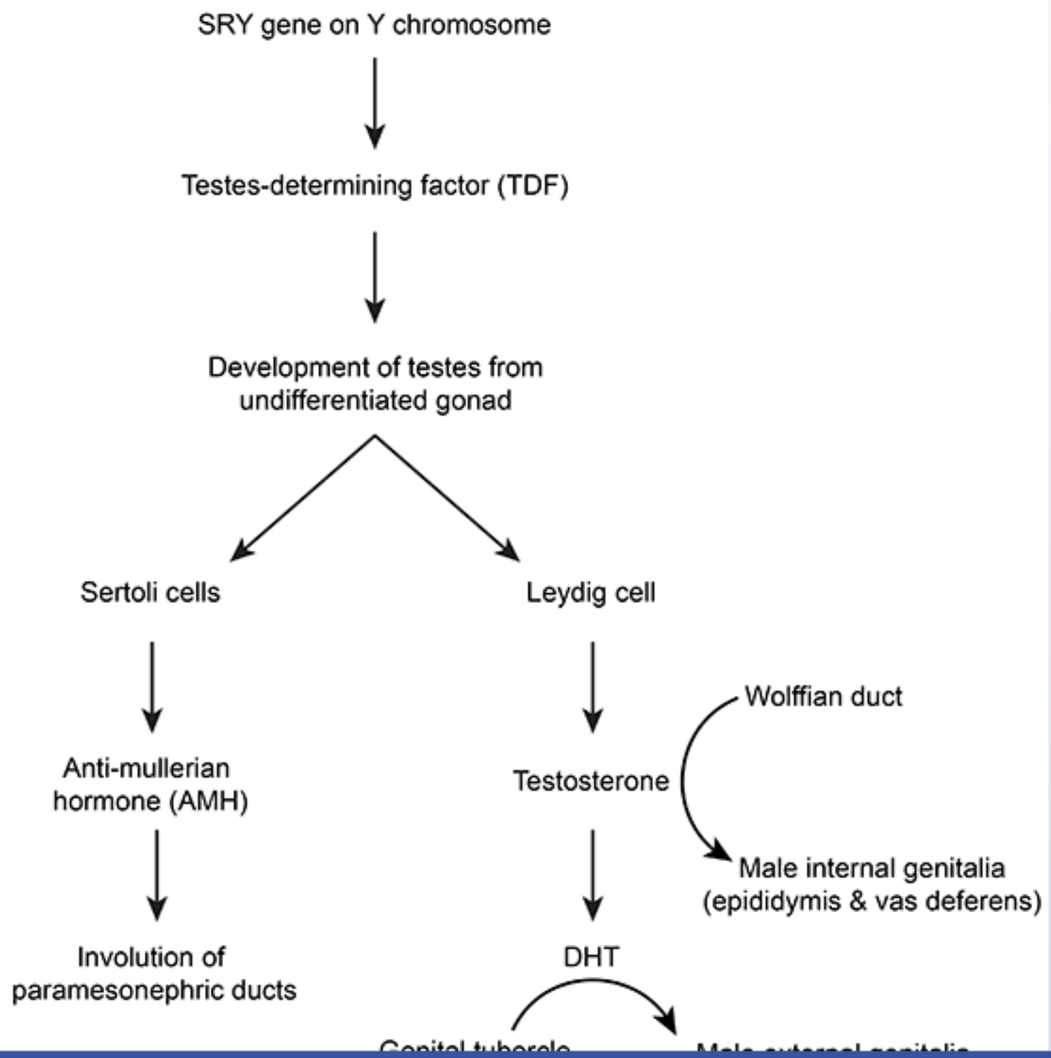

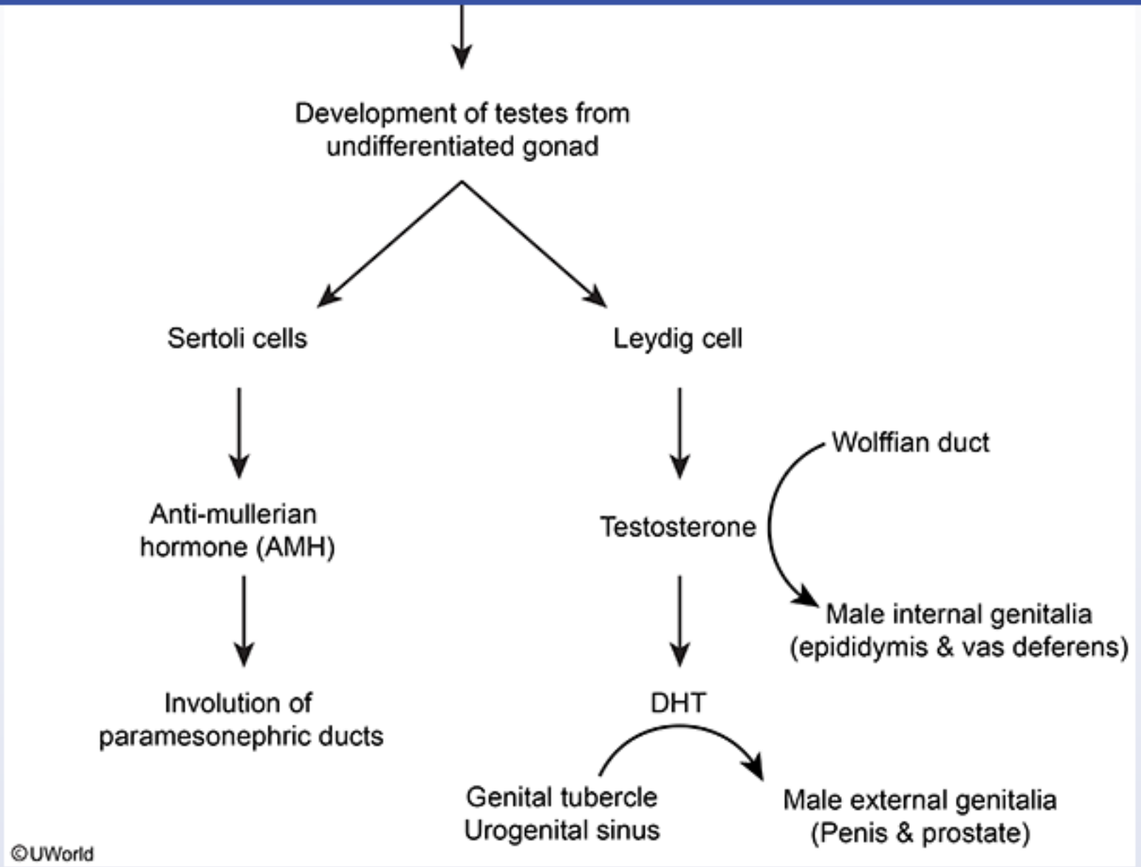

All early embryos have primitive (undifferentiated) gonads, Wolffian (mesonephric) ducts, and Müllerian (paramesonephric) ducts. The primitive gonads develop from the genital ridges and differentiate into either testes (male) or ovaries (female). This differentiation is a result of the **SRY gene** on the Y chromosome that codes for testes-determining factor, which allows XY embryos to **develop testes** from the primitive gonad. In the absence of the Y chromosome, primitive gonads develop into ovaries.

The testes contain both Sertoli and Leydig cells:

1. **Sertoli cells** suppress female internal reproductive organ development by producing **anti-Müllerian hormone** (AMH), which causes

©UWorld

All early embryos have primitive (undifferentiated) gonads, Wolffian (mesonephric) ducts, and Müllerian (paramesonephric) ducts. The primitive gonads develop from the genital ridges and differentiate into either testes (male) or ovaries (female). This differentiation is a result of the **SRY gene** on the Y chromosome that codes for testes-determining factor, which allows XY embryos to **develop testes** from the primitive gonad. In the absence of the Y chromosome, primitive gonads develop into ovaries.

The testes contain both Sertoli and Leydig cells:

1. **Sertoli cells** suppress female internal reproductive organ development by producing **anti-Müllerian hormone** (AMH), which causes **Müllerian duct involution**. Sertoli cells also produce androgen-binding protein, which concentrates testosterone in the seminiferous tubules to enable spermatogenesis.
2. **Leydig cells** secrete testosterone, which stimulates the **Wolffian** (mesonephric) ducts to develop into **internal male** reproductive organs (eg, epididymides, vas deferens, ejaculatory ducts, seminal vesicles). Testosterone is peripherally converted into **dihydrotestosterone**, which transforms the genital tubercle, urogenital folds, and labioscrotal swelling into the **external male** reproductive organs.

In the **absence of Sertoli cells or AMH**, the Müllerian ducts develop into the **internal female** reproductive organs (eg, fallopian tubes, uterus, cervix, upper vagina). Therefore, this infant would develop male internal and external reproductive organs due to the presence of Leydig cells **(Choice C)**. The infant would also have female internal reproductive organs from the lack of Sertoli cells.

(Choices A and B) Female internal reproductive organs would develop from a normal XX embryo (or an XY embryo with absence of the SRY gene). The presence of ambiguous or male-type genitalia in genetic females is consistent with androgen excess, as can occur with congenital adrenal hyperplasia due to 21-hydroxylase or 11β-hydroxylase deficiency.

(Choice E) The development of only male internal reproductive organs requires normal functioning of both Sertoli and Leydig cells. Ambiguous (undervirilized) genitalia in genetic males can occur with 17-alpha-hydroxylase deficiency.

(Choice F) Male internal and external reproductive organs are indicative of normal development of an XY embryo with both Sertoli and Leydig cell function.

Educational objective:
The SRY gene on the Y chromosome codes for the testes-determining factor, which differentiates the primitive gonads into testes. Sertoli cells

(eg, epididymides, vas deferens, ejaculatory ducts, seminal vesicles). Testosterone is peripherally converted into **dihydrotestosterone**, which transforms the genital tubercle, urogenital folds, and labioscrotal swelling into the **external male** reproductive organs.

In the **absence of Sertoli cells or AMH**, the Müllerian ducts develop into the **internal female** reproductive organs (eg, fallopian tubes, uterus, cervix, upper vagina). Therefore, this infant would develop male internal and external reproductive organs due to the presence of Leydig cells **(Choice C)**. The infant would also have female internal reproductive organs from the lack of Sertoli cells.

(Choices A and B) Female internal reproductive organs would develop from a normal XX embryo (or an XY embryo with absence of the SRY gene). The presence of ambiguous or male-type genitalia in genetic females is consistent with androgen excess, as can occur with congenital adrenal hyperplasia due to 21-hydroxylase or 11β-hydroxylase deficiency.

(Choice E) The development of only male internal reproductive organs requires normal functioning of both Sertoli and Leydig cells. Ambiguous (undervirilized) genitalia in genetic males can occur with 17-alpha-hydroxylase deficiency.

(Choice F) Male internal and external reproductive organs are indicative of normal development of an XY embryo with both Sertoli and Leydig cell function.

Educational objective:
The SRY gene on the Y chromosome codes for the testes-determining factor, which differentiates the primitive gonads into testes. Sertoli cells produce anti-Müllerian hormone, which causes regression of the Müllerian ducts and suppresses female internal reproductive organ development. Leydig cells produce testosterone, differentiating Wolffian ducts into internal male reproductive organs. Dihydrotestosterone is required for differentiation of the external male genitalia.

References

- Genetic regulation of mammalian gonad development.

Embryology	Male Reproductive System	Sexual differentiation
Subject	System	Topic

Copyright © UWorld. All rights reserved.

A 23-year-old man comes to the office with a 2-week history of malaise, loss of appetite, and vague abdominal pain. The patient has had no nausea, vomiting, changes in his bowel habits, dysuria, urinary frequency, or hematuria. He had an appendectomy for acute appendicitis at age 15; his medical history is otherwise unremarkable. He does not use tobacco or alcohol and has had no recent travel. His father was diagnosed with colon cancer at age 60. Physical examination reveals normal bowel sounds and no guarding or rebound tenderness. Abdominal CT scan obtained as part of this patient's evaluation is shown in the image below.

The anatomical structure indicated by the arrow originates from which of the following embryologic divisions?

- A. Ectoderm
- B. Endoderm
- C. Mesoderm
- D. Neural crest
- E. Notochord

Submit

A 23-year-old man comes to the office with a 2-week history of malaise, loss of appetite, and vague abdominal pain. The patient has had no nausea, vomiting, changes in his bowel habits, dysuria, urinary frequency, or hematuria. He had an appendectomy for acute appendicitis at age 15; his medical history is otherwise unremarkable. He does not use tobacco or alcohol and has had no recent travel. His father was diagnosed with colon cancer at age 60. Physical examination reveals normal bowel sounds and no guarding or rebound tenderness. Abdominal CT scan obtained as part of this patient's evaluation is shown in the image below.

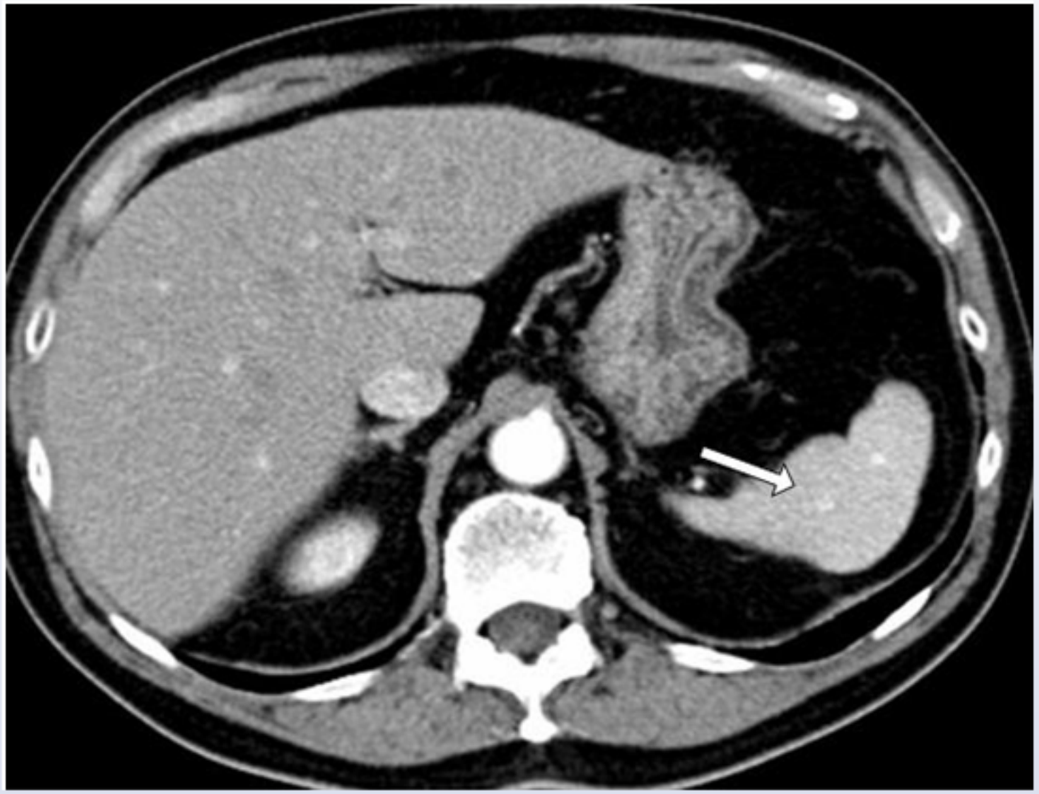

The anatomical structure indicated by the arrow originates from which of the following embryologic divisions?

The anatomical structure indicated by the arrow originates from which of the following embryologic divisions?

- A. Ectoderm
- B. Endoderm
- C. Mesoderm
- D. Neural crest
- E. Notochord

Submit

Settings

1 2 3 4 5 6 7 8 9 10 11 12 13 14 15 16 17 18 19 20 21 22 23 24 25 26 27 28 29 30

Item 14 of 40
Question Id: 12198

Mark | Previous | Next | Full Screen | Tutorial | Lab Values | Notes | Calculator | Reverse Color | Text Zoom | Settings

The anatomical structure indicated by the arrow originates from which of the following embryologic divisions?

A. Ectoderm (2%)

B. Endoderm (18%)

✓ C. Mesoderm (74%)

D. Neural crest (4%)

E. Notochord (0%)

Omitted
Correct answer

74%
Answered correctly

04 secs
Time Spent

02/04/2020
Last Updated

Block Time Remaining: 00:00:34
TUTOR

4 | Feedback | Suspend | End Block

Embryological derivatives		
Ectoderm	Surface ectoderm	• Anterior pituitary (Rathke pouch) • Lens & cornea • Inner ear sensory organs, olfactory epithelium • Nasal & oral epithelial linings, salivary glands • Epidermis, sweat & mammary glands
	Neural tube	• Brain & spinal cord • Posterior pituitary, pineal gland • Retina
	Neural crest	• Neural ganglia, adrenal medulla • Schwann cells; pia & arachnoid mater • Aorticopulmonary septum & endocardial cushions • Branchial arches (bones & cartilage) • Skull bones • Melanocytes
Mesoderm		• Muscles (skeletal, cardiac & smooth) • Connective tissue, bone & cartilage • Serosal linings (eg, peritoneum) • Cardiovascular & lymphatic system • Spleen & hemopoietic cells • Kidney & ureters, internal genitalia • Adrenal cortex
		• Gastrointestinal tract, liver, pancreas

Ectoderm		• Epidermis, sweat & mammary glands
	Neural tube	• Brain & spinal cord • Posterior pituitary, pineal gland • Retina
	Neural crest	• Neural ganglia, adrenal medulla • Schwann cells; pia & arachnoid mater • Aorticopulmonary septum & endocardial cushions • Branchial arches (bones & cartilage) • Skull bones • Melanocytes
Mesoderm		• Muscles (skeletal, cardiac & smooth) • Connective tissue, bone & cartilage • Serosal linings (eg, peritoneum) • Cardiovascular & lymphatic system • Spleen & hemopoietic cells • Kidney & ureters, internal genitalia • Adrenal cortex
Endoderm		• Gastrointestinal tract, liver, pancreas • Lungs • Thymus, parathyroids, thyroid follicular cells • Middle ear epithelium • Bladder & urethra • Parafollicular (C) cells*

*Formerly thought to be of neural crest origin.

Endoderm	• Gastrointestinal tract, liver, pancreas • Lungs • Thymus, parathyroids, thyroid follicular cells • Middle ear epithelium • Bladder & urethra • Parafollicular (C) cells*

*Formerly thought to be of neural crest origin.

The arrow in this patient's abdominal CT scan is pointing to the **spleen**, a large, wedge-shaped lymphatic organ that is situated in the **posterior superior** portion of the **left abdominal cavity**. While most gut tissue is endodermal in origin, the spleen is unique as it is derived from condensed mesenchymal tissue in the dorsal mesentery during embryonic development. Mesenchymal tissue arises from the **mesoderm germ layer** and is characterized by loosely associated cells surrounded by the extracellular matrix.

(Choice E) The notochord is a mesodermally derived structure that almost completely regresses in humans, and its only major derivative is the nucleus pulposus of the intervertebral disc. Other major derivatives of the mesoderm germ layer include muscle, bone, lymphatics, the cardiovascular system, and kidneys/ureters.

Educational objective:
The spleen is a large, wedge-shaped lymphatic organ that is situated in the posterior superior portion of the left abdominal cavity. It is derived from mesoderm in the dorsal mesentery during embryonic development.

References

- Embryonic origins of spleen asymmetry.

Embryology	Gastrointestinal & Nutrition	Embryologic derivatives
Subject	System	Topic

Copyright © UWorld. All rights reserved.

A 35-year-old man comes to the emergency department due to persistent abdominal pain. Yesterday, during a soccer game, he suffered a full-speed collision with another player. He had diffuse abdominal pain at the time but did not seek care until this morning, when the pain seemed to worsen. As part of the patient's evaluation, a CT scan of the abdomen is obtained and shown in the image below. It is determined that his injury involves an organ that is supplied mainly by an artery of the foregut even though the organ itself is not a foregut derivative. Which of the following organs is most likely to be injured in this patient?

A. A

B. B

C. C

D. D

E. E

Submit

A 35-year-old man comes to the emergency department due to persistent abdominal pain. Yesterday, during a soccer game, he suffered a full-speed collision with another player. He had diffuse abdominal pain at the time but did not seek care until this morning, when the pain seemed to worsen. As part of the patient's evaluation, a CT scan of the abdomen is obtained and shown in the image below. It is determined that his injury involves an organ that is supplied mainly by an artery of the foregut even though the organ itself is not a foregut derivative. Which of the following organs is most likely to be injured in this patient?

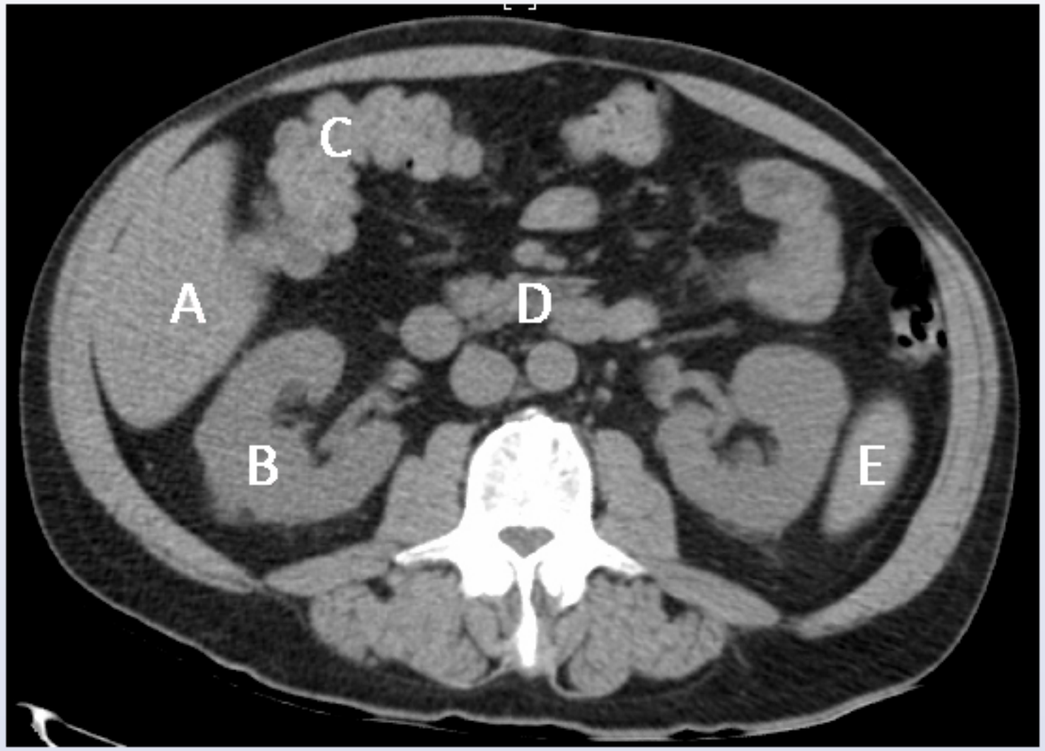

A. A

B. B

Settings

1 2 3 4 5 6 7 8 9 10 11 12 13 14 15 16 17 18 19 20 21 22 23 24 25 26 27 28 29 30

Item 15 of 40
Question Id: 2022

Mark | Previous | Next | Full Screen | Tutorial | Lab Values | Notes | Calculator | Reverse Color | Text Zoom | Settings

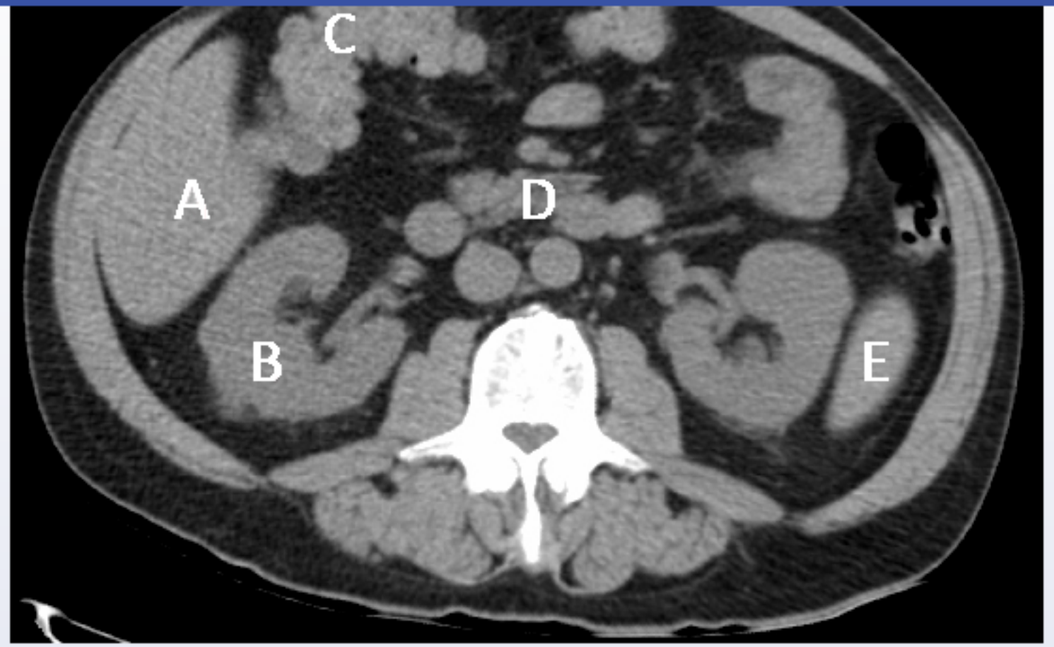

A. A

B. B

C. C

D. D

E. E

Submit

Block Time Remaining: 00:00:38
TUTOR

4 | Feedback | Suspend | End Block

Settings

1 2 3 4 5 6 7 8 9 10 11 12 13 14 15 16 17 18 19 20 21 22 23 24 25 26 27 28 29 30

Item 15 of 40
Question Id: 2022

Mark | Previous | Next | Full Screen | Tutorial | Lab Values | Notes | Calculator | Reverse Color | Text Zoom | Settings

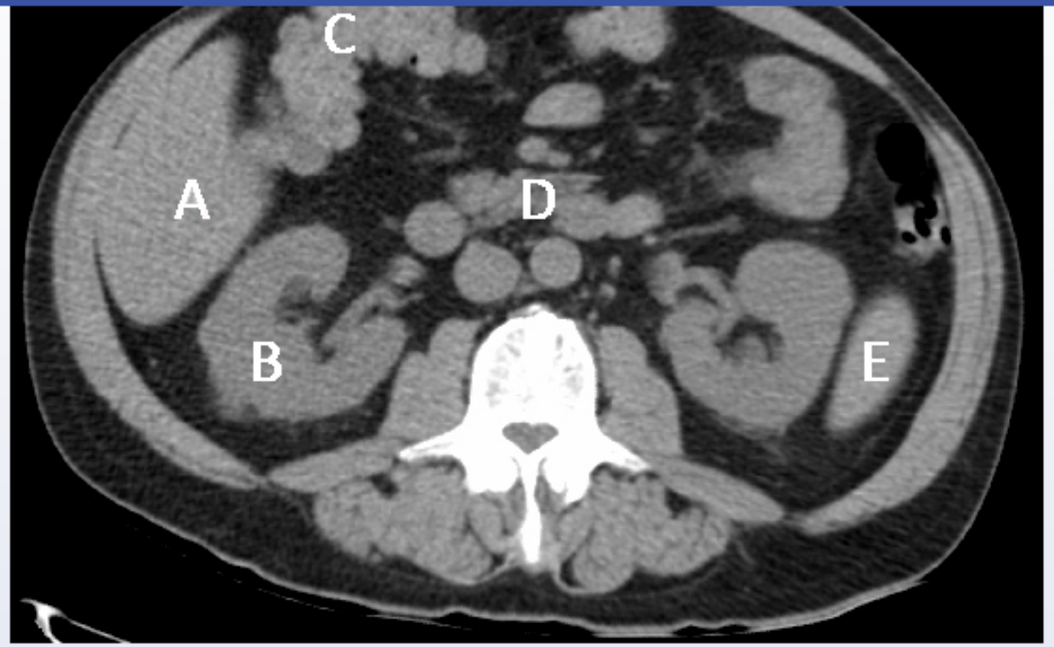

A. A (9%)

B. B (3%)

C. C (5%)

D. D (11%)

✓ E. E (69%)

Omitted
Correct answer

69%
Answered correctly

06 secs
Time Spent

01/13/2020
Last Updated

Block Time Remaining: 00:00:40
TUTOR

4 | Feedback | Suspend | End Block

The most common intra-abdominal organ injured during **blunt trauma** is the **spleen**. CT scans and MRI are conventionally presented so that the patient's left is on the reader's right (imagine that the patient is supine with the feet directed toward the viewer). This is a relatively caudal (lower) abdominal image that includes the kidneys; therefore, only the tail of the spleen is visible.

The spleen is an intraperitoneal organ derived from the **mesoderm** of the dorsal mesentery. However, the spleen is unique in that its blood supply derives from a **foregut derivative** (the splenic artery off of the celiac trunk). Venous return from the spleen courses through the splenic vein to return to the portal circulation rather than the systemic circulation.

(Choice A) The liver is an endoderm-derived structure of the foregut and receives its arterial blood from the proper hepatic artery (via the celiac trunk). The liver also receives venous blood from the gut via the portal vein.

(Choice B) Like the spleen, the kidneys are derived from the mesoderm. However, the kidneys are retroperitoneal and supplied by the renal arteries (from the abdominal aorta) and drained by the renal veins (to the inferior vena cava).

(Choice C) The first two-thirds of the transverse colon is derived from the midgut and supplied by the superior mesenteric artery. The last one-third of the transverse colon arises from the hindgut and is supplied by branches of the inferior mesenteric artery. These 2 vessels anastomose via the marginal artery.

(Choice D) The pancreas is an endoderm-derived structure of the foregut that receives blood primarily from the superior and inferior pancreaticoduodenal arteries.

Educational objective:
The spleen is of mesodermal origin (the dorsal mesentery). Although it is supplied by the splenic artery (a branch of the major foregut vessel, the celiac trunk), it is not a foregut derivative.

References

- Embryonic origins of spleen asymmetry.

Embryology	Gastrointestinal & Nutrition	Spleen rupture
Subject	System	Topic

1 2 3 4 5 6 7 8 9 10 11 12 13 14 15 16 17 18 19 20 21 22 23 24 25 26 27 28 29 30

The most common intra-abdominal organ injured during **blunt trauma** is the **spleen**. CT scans and MRI are conventionally presented so that the

Exhibit Display

Upper abdominal vasculature

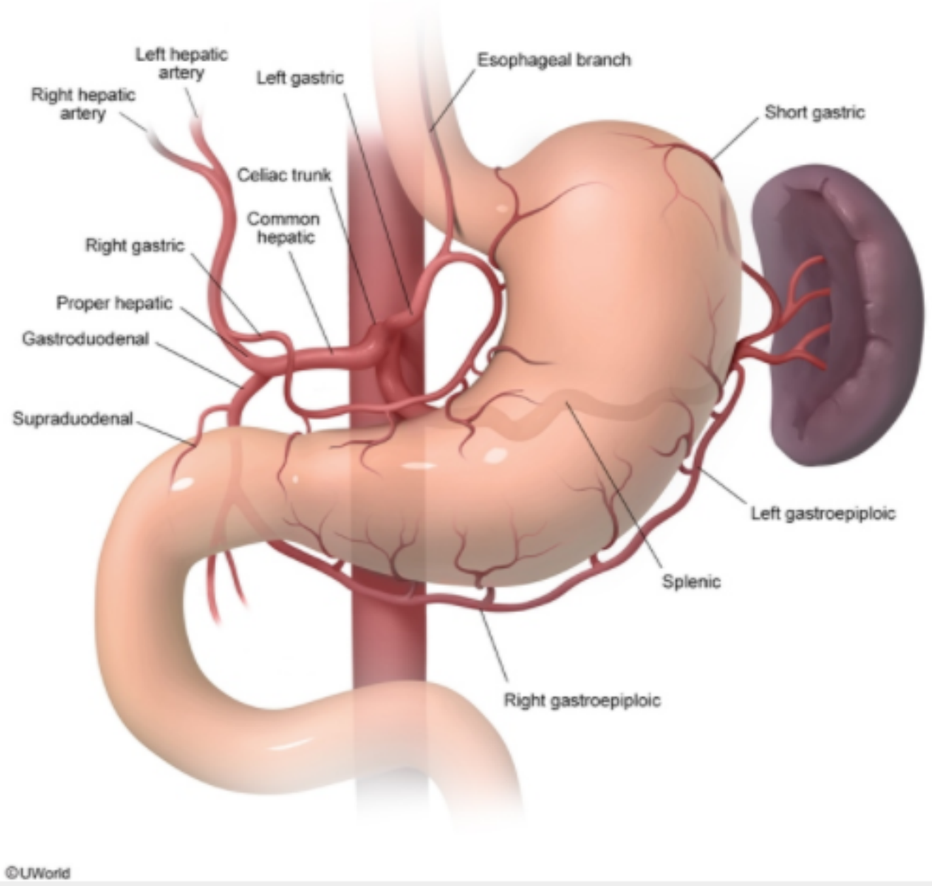

Zoom In | Zoom Out | Reset | Add To New Card | Existing Card

The most common intra-abdominal organ injured during **blunt trauma** is the **spleen**. CT scans and MRI are conventionally presented so that the

Exhibit Display

Portal venous system

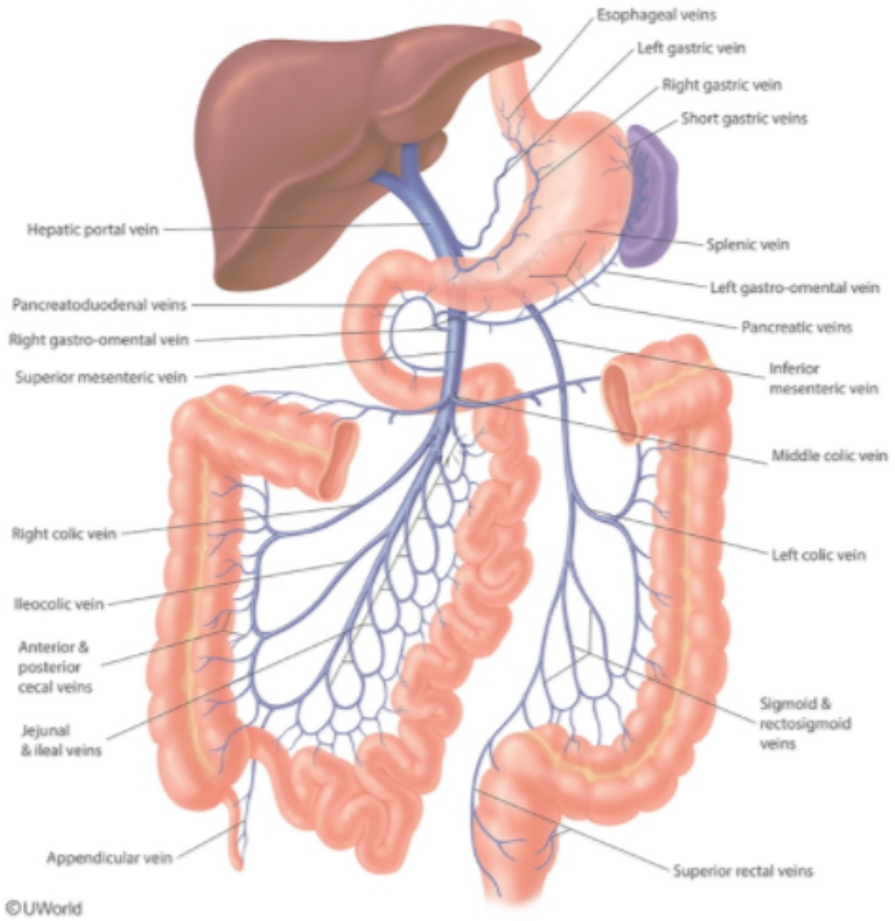

Zoom In | Zoom Out | Reset | Add To New Card | Existing Card

An infant born to a 22-year-old female has ambiguous genitalia. The gonadal cells contain a Y chromosome and there is no uterus on pelvic examination. The absence of a uterus is due to the effects of which of the following substances in the fetal period?

A. Testosterone (T)

B. Dihydrotestosterone (DHT)

C. Dehydroepiandrosterone (DHEA)

D. Luteinizing hormone (LH)

E. Mullerian inhibitory factor (MIF)

Submit

1 2 3 4 5 6 7 8 9 10 11 12 13 14 15 16 17 18 19 20 21 22 23 24 25 26 27 28 29 30

An infant born to a 22-year-old female has ambiguous genitalia. The gonadal cells contain a Y chromosome and there is no uterus on pelvic examination. The absence of a uterus is due to the effects of which of the following substances in the fetal period?

- A. Testosterone (T) (2%)
- B. Dihydrotestosterone (DHT) (3%)
- C. Dehydroepiandrosterone (DHEA) (1%)
- D. Luteinizing hormone (LH) (0%)
- ✓ E. Mullerian inhibitory factor (MIF) (91%)

Omitted
Correct answer
E

91%
Answered correctly

02 secs
Time Spent

01/21/2020
Last Updated

Explanation

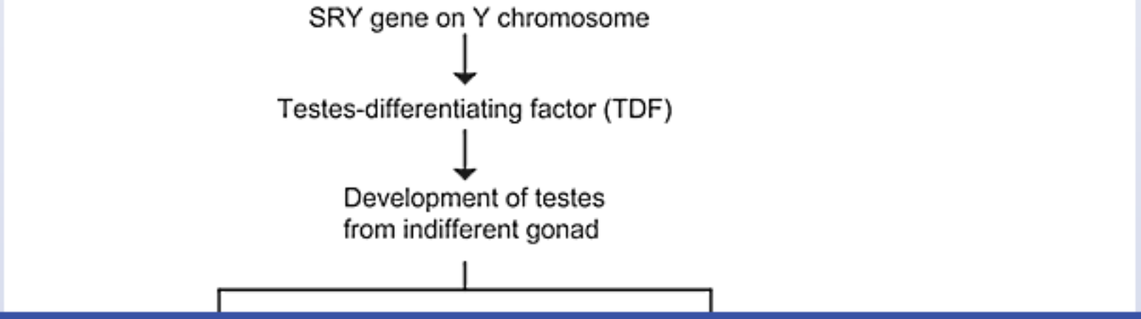

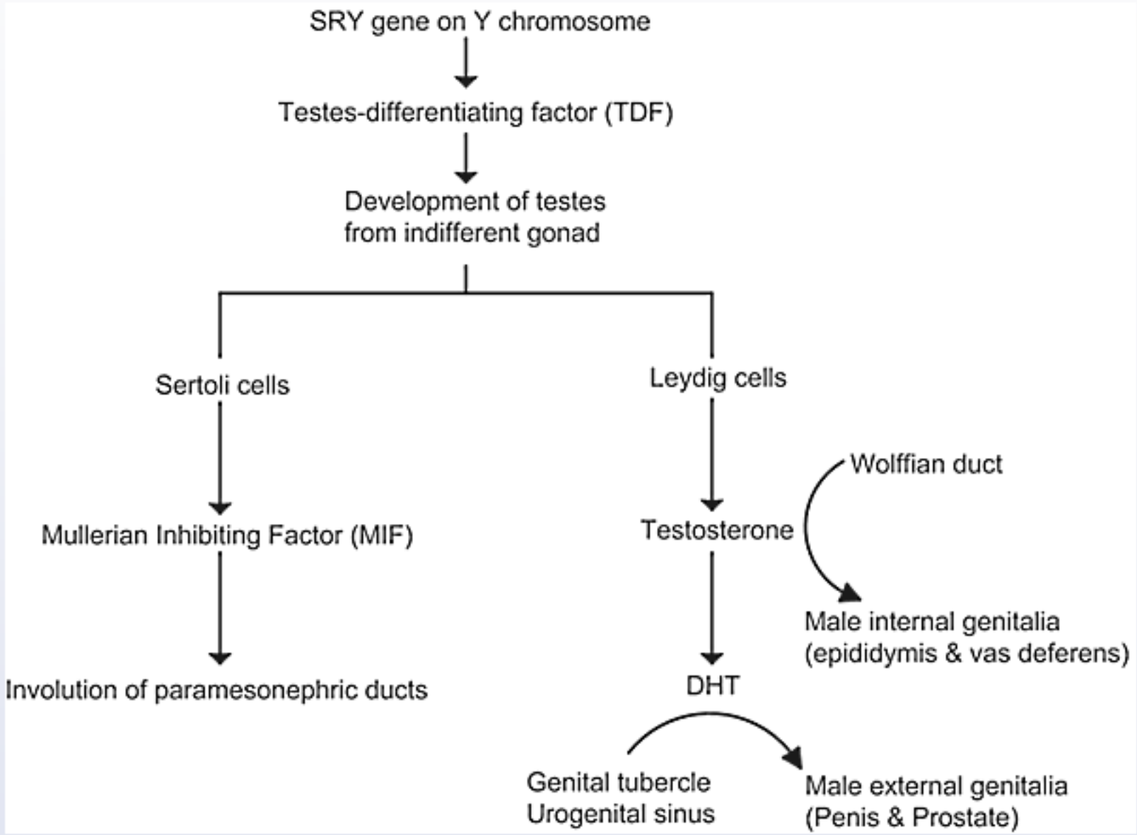

Although the genetic sex is determined at fertilization, the gonads and external genitalia are initially undifferentiated. During the first six weeks of gestation, the embryo has gonads, paramesonephric (müllerian) ducts *and* mesonephric (wolffian) ducts, a genital tubercle (phallus), urethral folds and genital swellings. Differentiation of the reproductive system occurs in the following sequence: gonadal development, genital duct development, and external genitalia development.

1. Gonadal stage: The primordial germ cells originate near the yolk sac and move towards the genital ridge, forming primitive gonads consisting of germ cells, supporting cells and steroidogenic cells. Under the influence of the SRY gene on the Y chromosome, male gonads

Urogenital sinus (Penis & Prostate)

Although the genetic sex is determined at fertilization, the gonads and external genitalia are initially undifferentiated. During the first six weeks of gestation, the embryo has gonads, paramesonephric (müllerian) ducts *and* mesonephric (wolffian) ducts, a genital tubercle (phallus), urethral folds and genital swellings. Differentiation of the reproductive system occurs in the following sequence: gonadal development, genital duct development, and external genitalia development.

1. Gonadal stage: The primordial germ cells originate near the yolk sac and move towards the genital ridge, forming primitive gonads consisting of germ cells, supporting cells and steroidogenic cells. Under the influence of the SRY gene on the Y chromosome, male gonads begin to secrete testosterone (from Leydig cells) and müllerian-inhibiting factor (from Sertoli cells).
2. Ductal stage: In the male embryo, mullerian-inhibiting factor (MIF) causes the paramesonephric (mullerian) ducts to regress, while the mesonephric ducts develop into the epididymis, ductus deferens and seminal vesicles. In the female embryo, testosterone and MIF are not produced. The müllerian (paramesonephric) ducts give rise to the uterine tubes, uterus, cervix, and upper vagina under the influence of maternal estrogen and the mesonephric ducts regress.
3. Genital stage: The genital tubercle gives rise to glans penis in males and the glans clitoris in females. The urogenital folds transform into the ventral aspect of the penis in males and the labia minora in females. The genital swellings become the scrotum in males and the labia majora in females. The urogenital sinus gives rise to the bladder, urethra, prostate, and bulbourethral glands in males. In females it develops into the bladder, urethra, lower vagina and Bartholin glands.

(Choice A) Testosterone is produced by Leydig cells of the testes. During embryogenesis it is responsible for development of the internal male genitalia.

(Choice B) Dihydrotestosterone is an active metabolite of testosterone. During embryonic life it mediates formation of the male external genitalia, while in the adult it is responsible for development of male secondary sex characteristics.

(Choice C) Dehydroepiandrosterone (DHEA) is a sex hormone precursor produced by the adrenal gland. It is not known to play a role in sexual differentiation.

(Choice D) Luteinizing hormone (LH) is produced by the anterior pituitary gland. In the male it is trophic to Leydig cells and stimulates testosterone production. In the female it is responsible for maturation of the ovarian follicles, ovulation, and formation of the corpus luteum.

consisting of germ cells, supporting cells and steroidogenic cells. Under the influence of the SRY gene on the Y chromosome, male gonads begin to secrete testosterone (from Leydig cells) and müllerian-inhibiting factor (from Sertoli cells).

2. Ductal stage: In the male embryo, mullerian-inhibiting factor (MIF) causes the paramesonephric (mullerian) ducts to regress, while the mesonephric ducts develop into the epididymis, ductus deferens and seminal vesicles. In the female embryo, testosterone and MIF are not produced. The müllerian (paramesonephric) ducts give rise to the uterine tubes, uterus, cervix, and upper vagina under the influence of maternal estrogen and the mesonephric ducts regress.
3. Genital stage: The genital tubercle gives rise to glans penis in males and the glans clitoris in females. The urogenital folds transform into the ventral aspect of the penis in males and the labia minora in females. The genital swellings become the scrotum in males and the labia majora in females. The urogenital sinus gives rise to the bladder, urethra, prostate, and bulbourethral glands in males. In females it develops into the bladder, urethra, lower vagina and Bartholin glands.

(Choice A) Testosterone is produced by Leydig cells of the testes. During embryogenesis it is responsible for development of the internal male genitalia.

(Choice B) Dihydrotestosterone is an active metabolite of testosterone. During embryonic life it mediates formation of the male external genitalia, while in the adult it is responsible for development of male secondary sex characteristics.

(Choice C) Dehydroepiandrosterone (DHEA) is a sex hormone precursor produced by the adrenal gland. It is not known to play a role in sexual differentiation.

(Choice D) Luteinizing hormone (LH) is produced by the anterior pituitary gland. In the male it is trophic to Leydig cells and stimulates testosterone production. In the female it is responsible for maturation of the ovarian follicles, ovulation, and formation of the corpus luteum.

Educational Objective:
The embryonic testis secretes testosterone and müllerian inhibiting factor (MIF). MIF is responsible for regression of the paramesonephric (müllerian) ducts that normally give rise to the internal genitalia in the female fetus. Testosterone mediates development of male internal genitalia and DHT mediates development of the external genitalia.

Embryology	Male Reproductive System	Infertility
Subject	System	Topic

Amniocentesis is performed on a 35-year-old pregnant woman. The phospholipid content of the amniotic fluid is determined in order to check for:

A. Fetal neural tube defect

B. Erythroblastosis fetalis

C. Karyotype abnormalities

D. Fetal lung maturity

E. Cystic fibrosis

F. Fetal adrenal dysfunction

Submit

Amniocentesis is performed on a 35-year-old pregnant woman. The phospholipid content of the amniotic fluid is determined in order to check for:

- A. Fetal neural tube defect (4%)
- B. Erythroblastosis fetalis (1%)
- C. Karyotype abnormalities (3%)
- ✓ D. Fetal lung maturity (87%)
- E. Cystic fibrosis (1%)
- F. Fetal adrenal dysfunction (1%)

Omitted
Correct answer
D

87%
Answered correctly

02 secs
Time Spent

02/03/2020
Last Updated

Explanation

Phospholipids, including dipalmitoyl phosphatidylcholine, are a major component of pulmonary surfactant. The level of phosphatidylcholine (also called lecithin) is measured in amniotic fluid in order to gauge fetal lung maturity. When the lecithin to sphingomyelin (L/S) ratio in amniotic fluid is ≥ 2, the fetal lung is considered mature, meaning that it is producing adequate surfactant to avoid neonatal respiratory distress syndrome after birth. The L/S ratio is measured in cases of premature labor and/or premature rupture of the membranes in order to determine the timing of delivery and whether or not to give the mother corticosteroids to induce fetal surfactant production.

(Choice A) When a fetal neural tube defect is suspected, amniotic fluid is sampled to measure the level of alpha-fetoprotein (AFP). Elevated AFP

Phospholipids, including dipalmitoyl phosphatidylcholine, are a major component of pulmonary surfactant. The level of phosphatidylcholine (also called lecithin) is measured in amniotic fluid in order to gauge fetal lung maturity. When the lecithin to sphingomyelin (L/S) ratio in amniotic fluid is ≥ 2, the fetal lung is considered mature, meaning that it is producing adequate surfactant to avoid neonatal respiratory distress syndrome after birth. The L/S ratio is measured in cases of premature labor and/or premature rupture of the membranes in order to determine the timing of delivery and whether or not to give the mother corticosteroids to induce fetal surfactant production.

(Choice A) When a fetal neural tube defect is suspected, amniotic fluid is sampled to measure the level of alpha-fetoprotein (AFP). Elevated AFP levels suggest a neural tube closure defect, such as spina bifida.

(Choice B) In cases of suspected erythroblastosis fetalis, amniocentesis is used to assess fetal hemolysis by measuring amniotic fluid bilirubin levels.

(Choice C) Karyotype analysis of fetal cells obtained by amniocentesis is used to detect chromosomal abnormalities and metabolic disorders.

(Choice E) Antenatal diagnosis of cystic fibrosis (CF) may be performed via genetic mutation analysis of fetal cells obtained during amniocentesis.

(Choice F) Antenatal detection of a fetal adrenal disorder such as congenital adrenal hyperplasia can be accomplished via amniocentesis. This analysis may involve measurement of amniotic fluid 17-hydroxyprogesterone levels, gene linkage analysis involving the HLA region of chromosome 6, or detection of abnormal genes via molecular probes.

Educational Objective:
Phospholipids, including dipalmitoyl phosphatidylcholine, are a major component of pulmonary surfactant. The amniotic fluid lecithin (phosphatidylcholine) to sphingomyelin ratio (L/S ratio) is measured in order to assess fetal lung maturity. The fetal lungs are considered mature when they are producing adequate surfactant to yield an L/S ratio greater than 2.

Embryology	Pulmonary & Critical Care	Neonatal respiratory distress syndrome
Subject	System	Topic

Copyright © UWorld. All rights reserved.

Phospholipids, including dipalmitoyl phosphatidylcholine, are a major component of pulmonary surfactant. The level of phosphatidylcholine (also called lecithin) is measured in amniotic fluid in order to gauge fetal lung maturity. When the lecithin to sphingomyelin (L/S) ratio in amniotic fluid is ≥ 2, the fetal lung is considered mature, meaning that it is producing adequate surfactant to avoid neonatal respiratory distress syndrome after birth. The L/S ratio is measured in cases of premature labor and/or premature rupture of the membranes in order to determine the timing of delivery and whether or not to give the mother corticosteroids to induce fetal surfactant production.

(Choice A) When a fetal neural tube defect is suspected, amniotic fluid is sampled to measure the level of alpha-fetoprotein (AFP). Elevated AFP levels suggest a neural tube closure defect, such as spina bifida.

(Choice B) In cases of suspected erythroblastosis fetalis, amniocentesis is used to assess fetal hemolysis by measuring amniotic fluid bilirubin levels.

(Choice C) Karyotype analysis of fetal cells obtained by amniocentesis is used to detect chromosomal abnormalities and metabolic disorders.

(Choice E) Antenatal diagnosis of cystic fibrosis (CF) may be performed via genetic mutation analysis of fetal cells obtained during amniocentesis.

(Choice F) Antenatal detection of a fetal adrenal disorder such as congenital adrenal hyperplasia can be accomplished via amniocentesis. This analysis may involve measurement of amniotic fluid 17-hydroxyprogesterone levels, gene linkage analysis involving the HLA region of chromosome 6, or detection of abnormal genes via molecular probes.

Educational Objective:
Phospholipids, including dipalmitoyl phosphatidylcholine, are a major component of pulmonary surfactant. The amniotic fluid lecithin (phosphatidylcholine) to sphingomyelin ratio (L/S ratio) is measured in order to assess fetal lung maturity. The fetal lungs are considered mature when they are producing adequate surfactant to yield an L/S ratio greater than 2.

Embryology	Pulmonary & Critical Care	Neonatal respiratory distress syndrome
Subject	System	Topic

Copyright © UWorld. All rights reserved.

A 22-year-old woman at 14 weeks gestation comes to the physician for a prenatal visit. She reports feeling well with the exception of some mild fatigue. Her pregnancy has been uncomplicated to date. On physical examination, the patient's abdomen appears larger than would be expected at 14 weeks. An obstetrical ultrasound reveals twins, a male and a female. Which of the following describes the most likely type of twin placentation in this patient?

A. Dichorionic/diamniotic

B. Dichorionic/monoamniotic

C. Monochorionic/diamniotic

D. Monochorionic/monoamniotic

E. Monochorionic/monoamniotic conjoined

Submit

1 2 3 4 5 6 7 8 9 10 11 12 13 14 15 16 17 18 19 20 21 22 23 24 25 26 27 28 29 30

A 22-year-old woman at 14 weeks gestation comes to the physician for a prenatal visit. She reports feeling well with the exception of some mild fatigue. Her pregnancy has been uncomplicated to date. On physical examination, the patient's abdomen appears larger than would be expected at 14 weeks. An obstetrical ultrasound reveals twins, a male and a female. Which of the following describes the most likely type of twin placentation in this patient?

- ✓ A. Dichorionic/diamniotic (76%)
- B. Dichorionic/monoamniotic (8%)
- C. Monochorionic/diamniotic (11%)
- D. Monochorionic/monoamniotic (2%)
- E. Monochorionic/monoamniotic conjoined (1%)

Omitted
Correct answer
A

76%
Answered correctly

02 secs
Time Spent

04/12/2020
Last Updated

Explanation

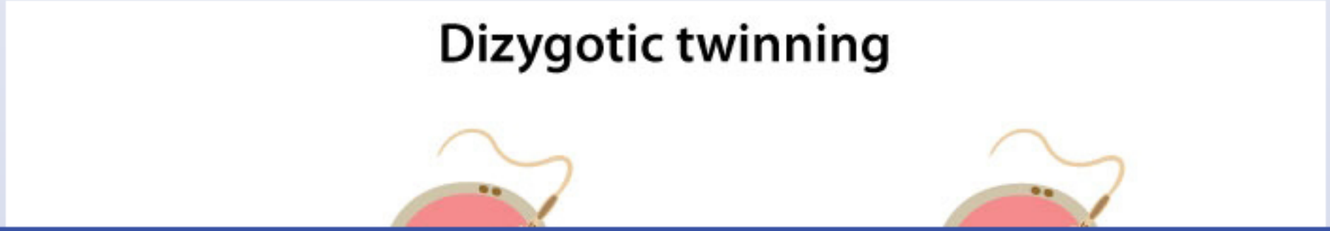

Settings

1 2 3 4 5 6 7 8 9 10 11 12 13 14 15 16 17 18 19 20 21 22 23 24 25 26 27 28 29 30

Item 18 of 40
Question Id: 8406

Mark | Previous | Next | Full Screen | Tutorial | Lab Values | Notes | Calculator | Reverse Color | Text Zoom | Settings

Dizygotic twinning

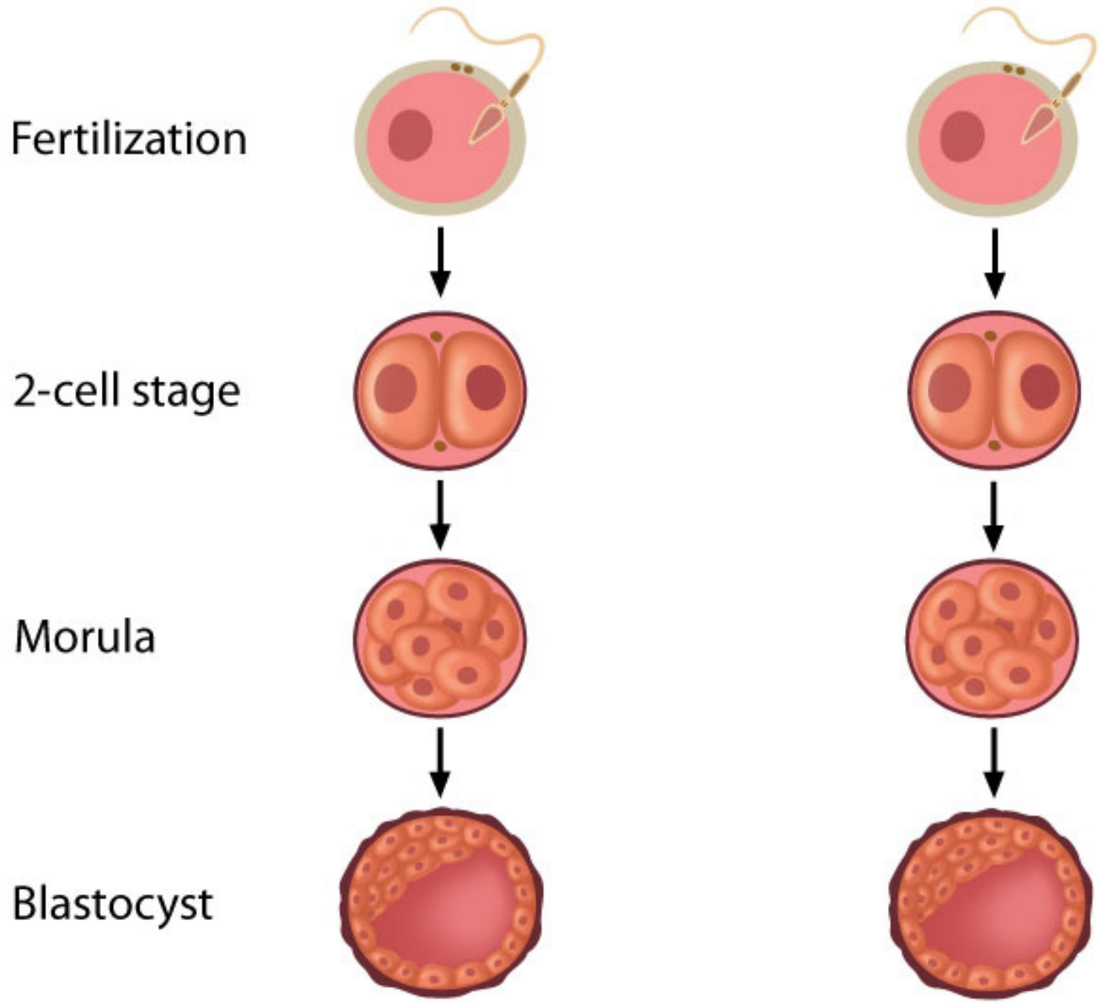

Block Time Remaining: 00:00:46
TUTOR

2 | Feedback | Suspend | End Block

1
2
3
4
5
6
7
8
9
10
11
12
13
14
15
16
17
18
19
20
21
22
23
24
25
26
27
28
29
30

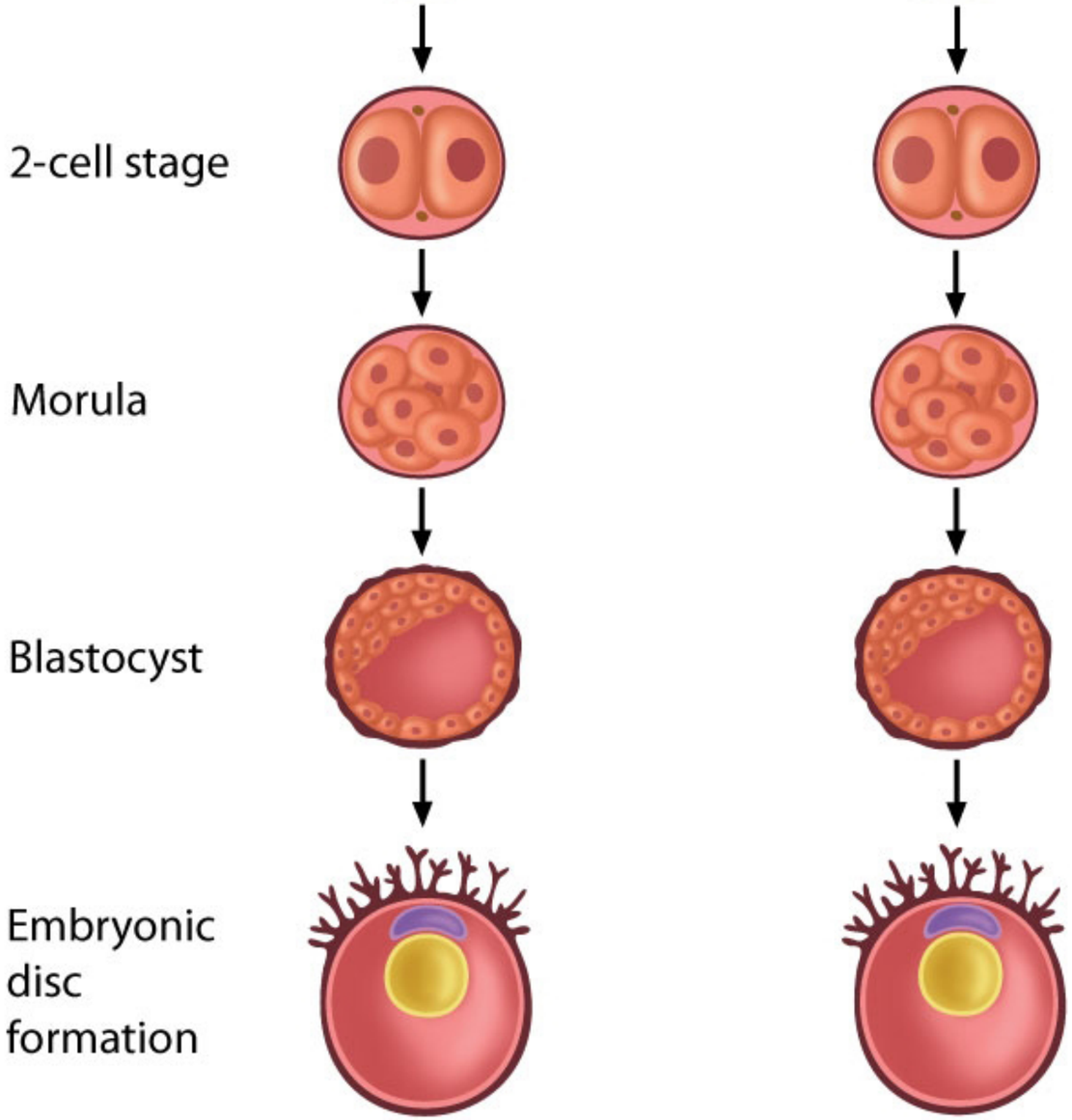

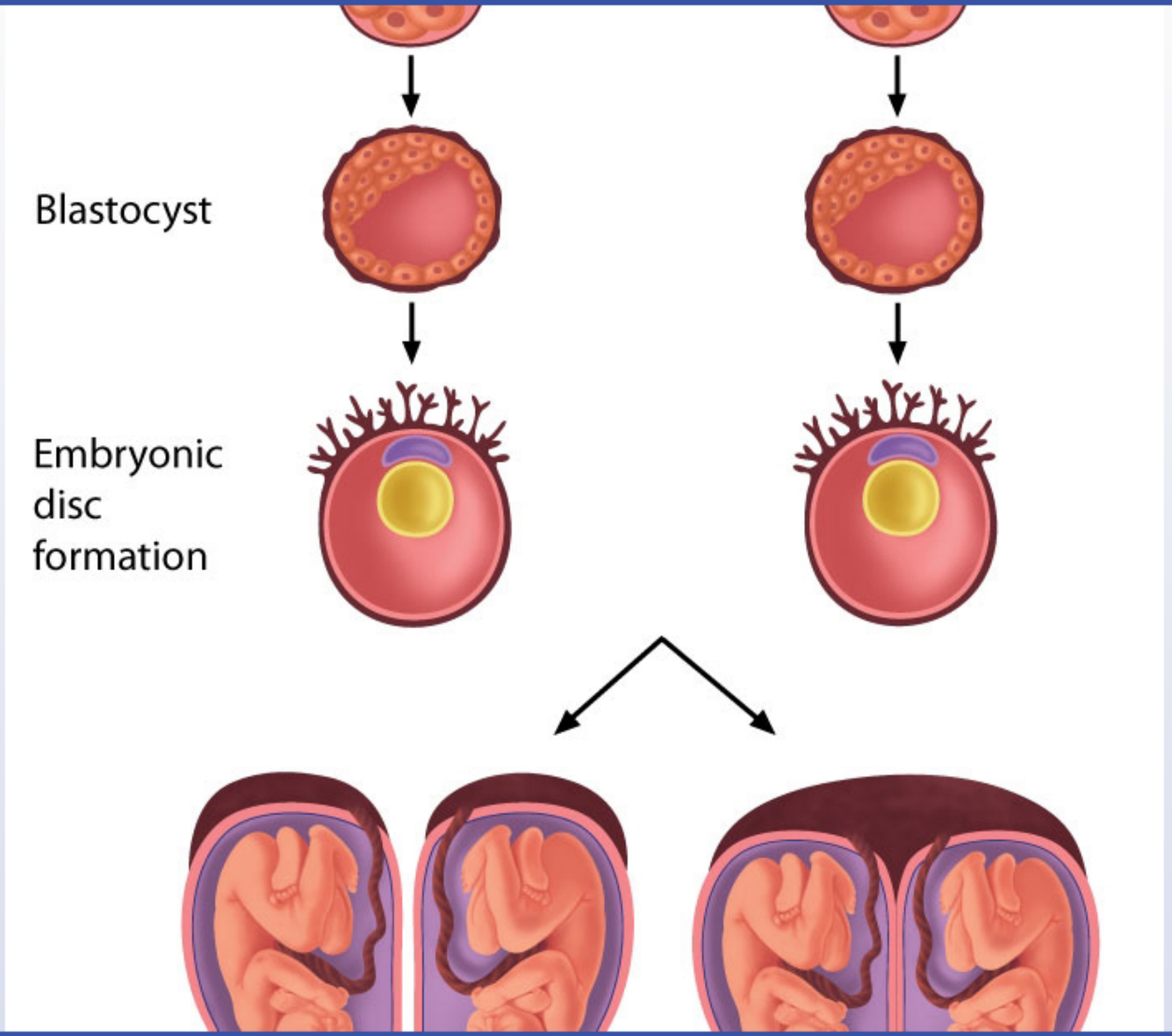
Blastocyst
Embryonic disc formation

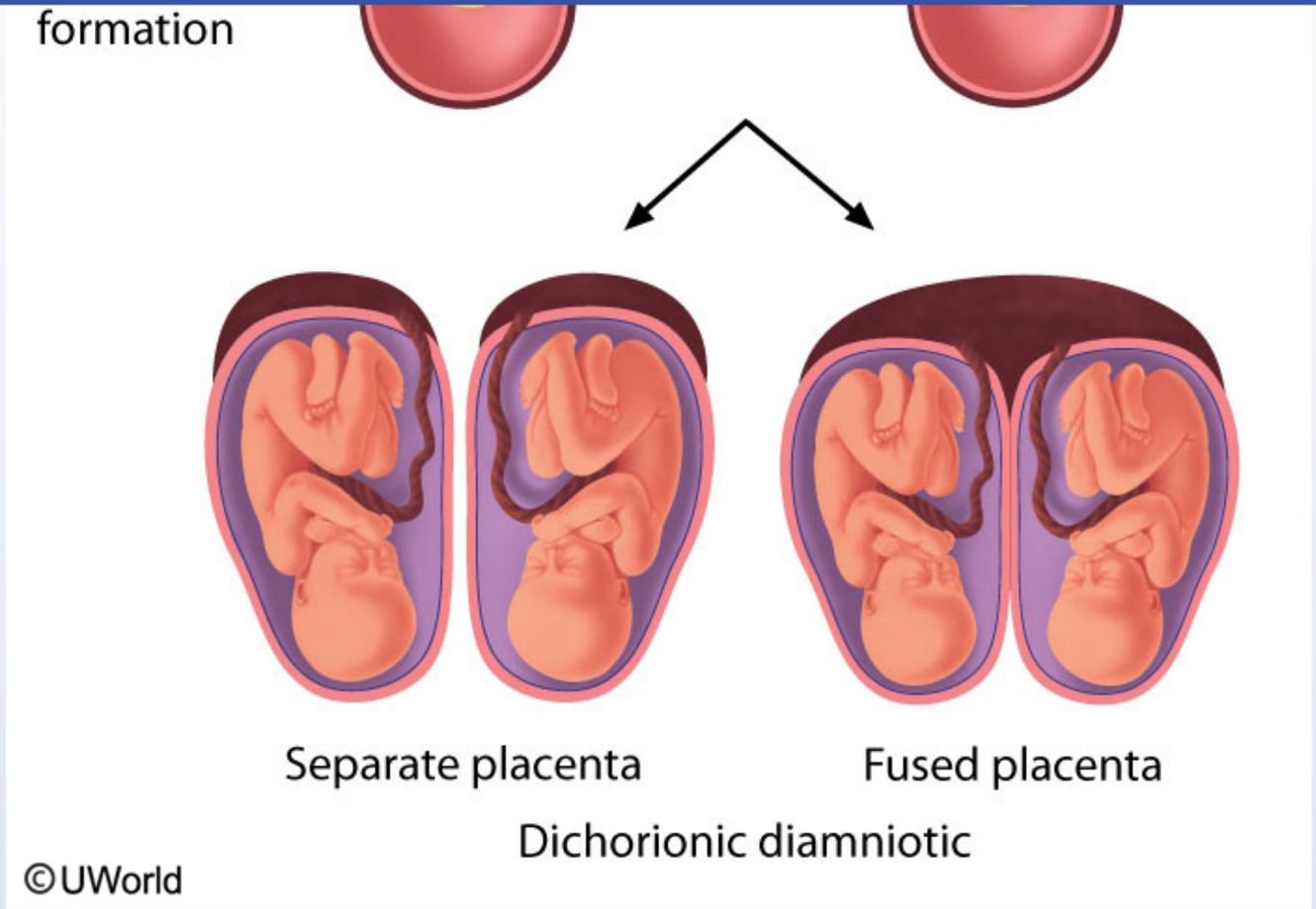

This patient is pregnant with twins of **different sexes** which can only occur in **dizygotic twins** due to the fertilization of 2 oocytes by 2 different sperm. Dizygotic twins are almost always **dichorionic/diamniotic** (eg, 2 chorions and 2 amnions) but may falsely give the appearance of being monochorionic/monoamniotic if the chorions and amnions fuse due to proximity of implantation sites.

In contrast, monozygotic twins develop from division of a single zygote after fertilization of a single oocyte. They are of the **same sex**, are genetically identical, and are similar in appearance. The type of placentation in monozygotic twins depends on when zygote division occurs during

Dichorionic diamniotic

©UWorld

This patient is pregnant with twins of **different sexes** which can only occur in **dizygotic twins** due to the fertilization of 2 oocytes by 2 different sperm. Dizygotic twins are almost always **dichorionic/diamniotic** (eg, 2 chorions and 2 amnions) but may falsely give the appearance of being monochorionic/monoamniotic if the chorions and amnions fuse due to proximity of implantation sites.

In contrast, monozygotic twins develop from division of a single zygote after fertilization of a single oocyte. They are of the **same sex**, are genetically identical, and are similar in appearance. The type of placentation in monozygotic twins depends on when zygote division occurs during embryonic development.

- Early division (days 0-4) can result in monozygotic twins with 2 chorions and 2 amnions (eg, dichorionic/diamniotic), which may or may not be fused. If the sexes are the same, it may be difficult to distinguish whether the twins are monozygotic or dizygotic until later in the pregnancy.
- Division between days 4-8 is the most common outcome in monozygotic twins and results in 1 chorion (eg, shared placenta) but 2 amnions (eg, monochorionic/diamniotic twins) **(Choice C)**.
- Late division (8-12 days) results in 1 chorion and 1 amnion. A monochorionic/monoamniotic pregnancy is associated with a high fetal fatality rate, due primarily to the increased risk of umbilical cord entanglement **(Choice D)**.
- Division occurring after 13 days can result in monochorionic/monoamniotic conjoined twins **(Choice E)**.

(Choice B) Dichorionic/monoamniotic twins do not exist.

Educational objective:
Dizygotic twins occur due to fertilization of 2 oocytes by 2 different sperm, can be different sexes, and almost always have 2 chorions and 2 amnions (eg, dichorionic/diamniotic). In contrast, monozygotic twins arise from the fertilization of a single oocyte, are the same sex, and can be dichorionic/diamniotic (days 0-4), monochorionic/diamniotic (days 4-8), monochorionic/monoamniotic (days 8-12), or monochorionic/monoamniotic conjoined twins (> 13 days).

Subject	System	Topic
Embryology	Pregnancy, Childbirth & Puerperium	Multiple gestation

This patient is pregnant with twins of **different sexes** which can only occur in **dizygotic twins** due to the fertilization of 2 oocytes by 2 different sperm. Dizygotic twins are almost always **dichorionic/diamniotic** (eg, 2 chorions and 2 amnions) but may falsely give the appearance of being monochorionic/monoamniotic if the chorions and amnions fuse due to proximity of implantation sites.

In contrast, monozygotic twins develop from division of a single zygote after fertilization of a single oocyte. They are of the **same sex**, are genetically identical, and are similar in appearance. The type of placentation in monozygotic twins depends on when zygote division occurs during embryonic development.

- Early division (days 0-4) can result in monozygotic twins with 2 chorions and 2 amnions (eg, dichorionic/diamniotic), which may or may not be fused. If the sexes are the same, it may be difficult to distinguish whether the twins are monozygotic or dizygotic until later in the pregnancy.
- Division between days 4-8 is the most common outcome in monozygotic twins and results in 1 chorion (eg, shared placenta) but 2 amnions (eg, monochorionic/diamniotic twins) **(Choice C)**.
- Late division (8-12 days) results in 1 chorion and 1 amnion. A monochorionic/monoamniotic pregnancy is associated with a high fetal fatality rate, due primarily to the increased risk of umbilical cord entanglement **(Choice D)**.
- Division occurring after 13 days can result in monochorionic/monoamniotic conjoined twins **(Choice E)**.

(Choice B) Dichorionic/monoamniotic twins do not exist.

Educational objective:
Dizygotic twins occur due to fertilization of 2 oocytes by 2 different sperm, can be different sexes, and almost always have 2 chorions and 2 amnions (eg, dichorionic/diamniotic). In contrast, monozygotic twins arise from the fertilization of a single oocyte, are the same sex, and can be dichorionic/diamniotic (days 0-4), monochorionic/diamniotic (days 4-8), monochorionic/monoamniotic (days 8-12), or monochorionic/monoamniotic conjoined twins (> 13 days).

Embryology	Pregnancy, Childbirth & Puerperium	Multiple gestation
Subject	System	Topic

Copyright © UWorld. All rights reserved.

1
2
3
4
5
6
7
8
9
10
11
12
13
14
15
16
17
18
19
20
21
22
23
24
25
26
27
28
29
30

This patient is pregnant with twins of **different sexes** which can only occur in **dizygotic twins** due to the fertilization of 2 oocytes by 2 different

Exhibit Display

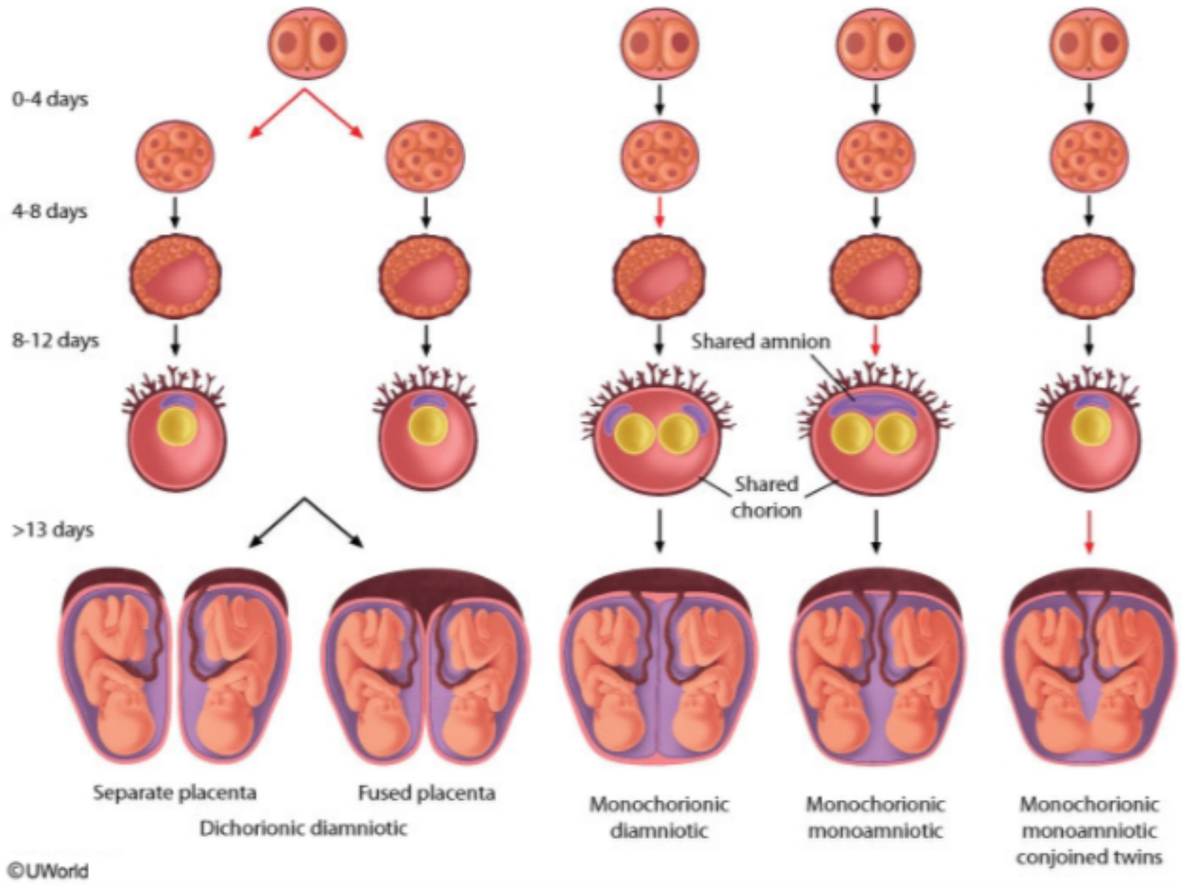

Zoom In | Zoom Out | Reset | Add To New Card | Existing Card

A 32-year-old woman complains of weakness in her hands and "heaviness" in her eyelids at the end of each day. Chest imaging shows an anterior mediastinal mass. The organ from which this mass most likely originated shares its embryologic origin with:

- A. Thyroid gland
- B. Superior parathyroid glands
- C. Inferior parathyroid glands
- D. Larynx
- E. Palatine tonsils

Submit

1 2 3 4 5 6 7 8 9 10 11 12 13 14 15 16 17 18 19 20 21 22 23 24 25 26 27 28 29 30

A 32-year-old woman complains of weakness in her hands and "heaviness" in her eyelids at the end of each day. Chest imaging shows an anterior mediastinal mass. The organ from which this mass most likely originated shares its embryologic origin with:

- A. Thyroid gland (22%)
- B. Superior parathyroid glands (16%)
- ✓ C. Inferior parathyroid glands (46%)
- D. Larynx (5%)
- E. Palatine tonsils (8%)

Omitted
Correct answer
C

46%
Answered correctly

01 sec
Time Spent

02/03/2020
Last Updated

Explanation

Myasthenia gravis causes muscle weakness, with the extraocular muscles most commonly affected. Patients often experience ptosis and diplopia. The muscle weakness worsens with activity, and patients often note that their symptoms are worse at the end of the day. The majority of patients with myasthenia gravis are found to have a thymoma or thymic hyperplasia.

Myasthenia gravis causes muscle weakness, with the extraocular muscles most commonly affected. Patients often experience ptosis and diplopia. The muscle weakness worsens with activity, and patients often note that their symptoms are worse at the end of the day. The majority of patients with myasthenia gravis are found to have a thymoma or thymic hyperplasia.

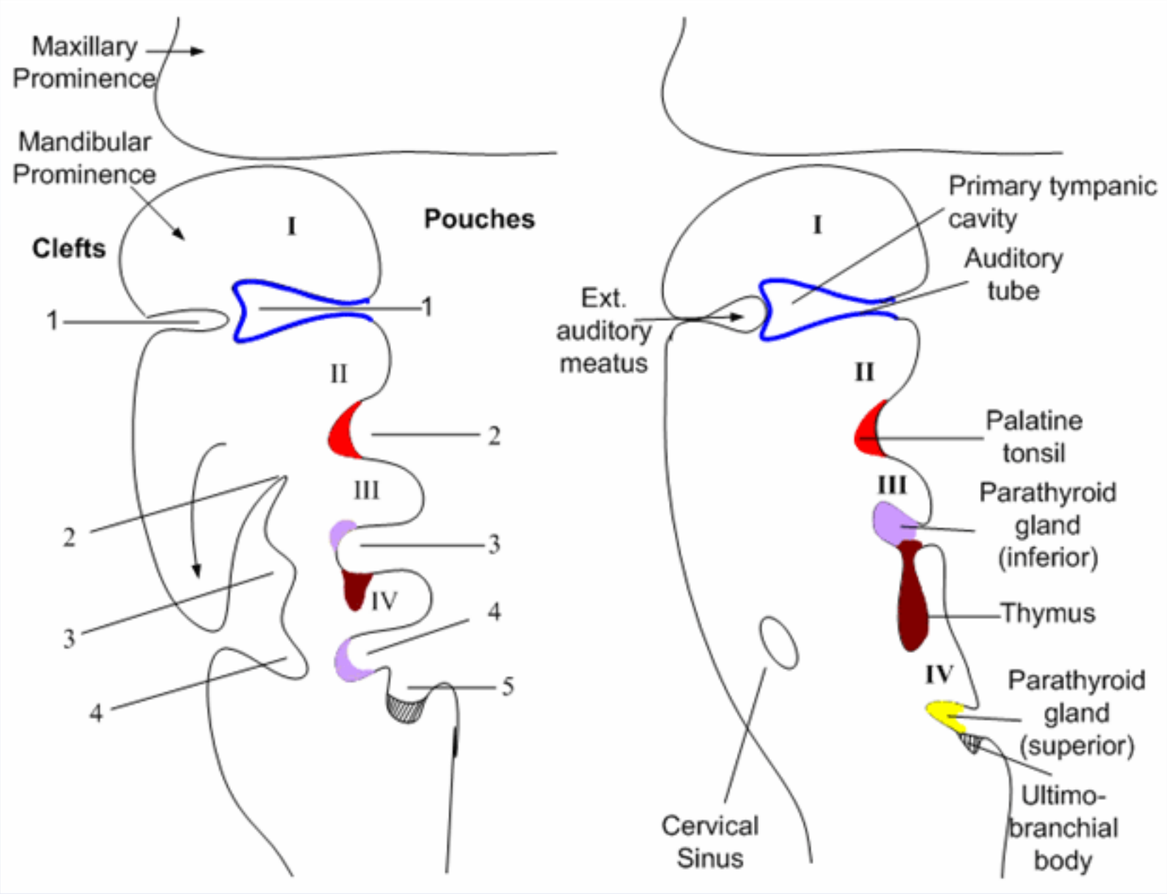

The thymus is derived from the third pharyngeal pouch, as are the inferior parathyroid glands. The table below lists the derivatives of the pharyngeal pouches, grooves and membranes:

Myasthenia gravis causes muscle weakness, with the extraocular muscles most commonly affected. Patients often experience ptosis and diplopia. The muscle weakness worsens with activity, and patients often note that their symptoms are worse at the end of the day. The majority of patients with myasthenia gravis are found to have a thymoma or thymic hyperplasia.

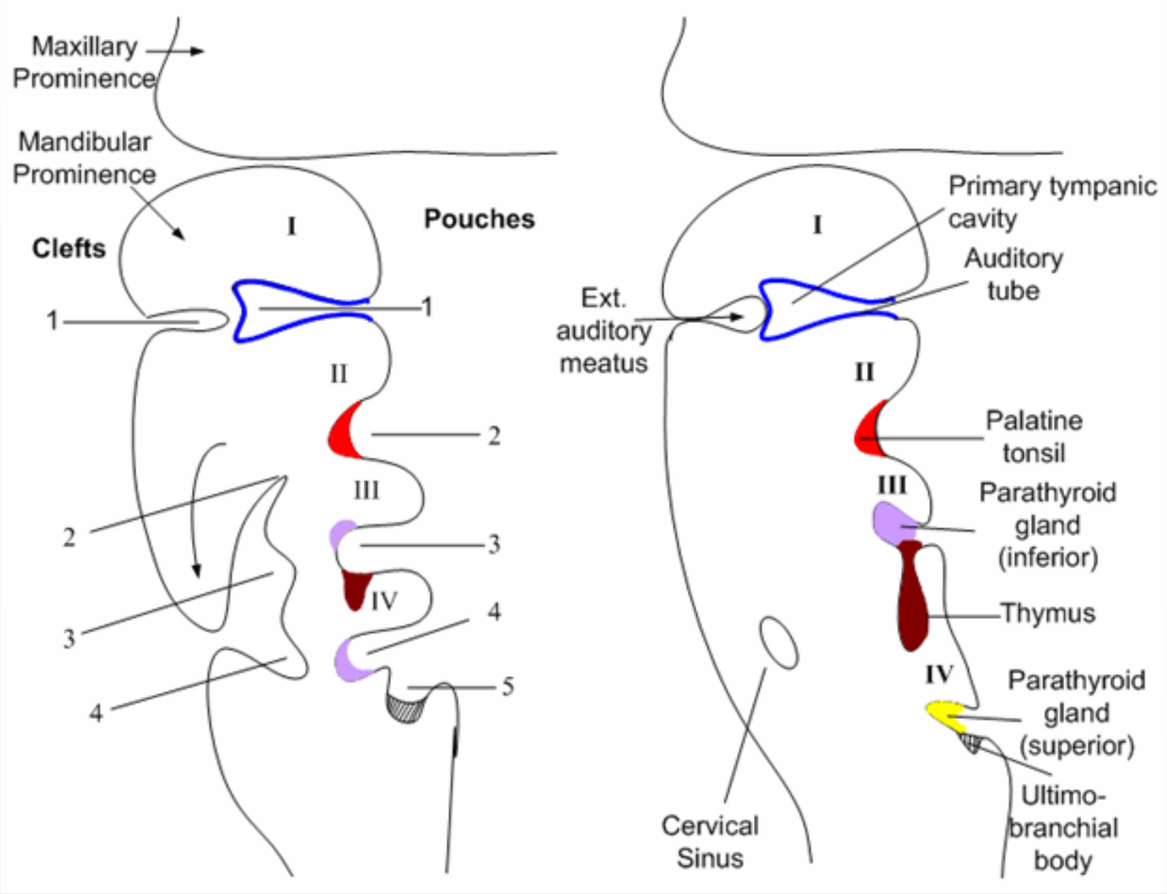

The thymus is derived from the third pharyngeal pouch, as are the inferior parathyroid glands. The table below lists the derivatives of the pharyngeal pouches, grooves and membranes:

The thymus is derived from the third pharyngeal pouch, as are the inferior parathyroid glands. The table below lists the derivatives of the pharyngeal pouches, grooves and membranes:

	Pharyngeal pouch	Pharyngeal membrane	Pharyngeal groove
1	Epithelium of middle ear and auditory tube	Tympanic membrane	Epithelium of external ear canal
2	Epithelium of palatine tonsil crypts	Obliterated	
3	Thymus, inferior parathyroid glands	Obliterated	
4	Superior parathyroid glands, ultimobranchial body	Obliterated	

(Choice A) The floor of the foregut gives rise to the thyroid diverticulum. The thyroid diverticulum migrates caudally to the neck, but remains attached to the floor of the mouth by the thyroglossal duct.

(Choice B) The superior parathyroid glands and ultimobranchial body are formed from the 4th pharyngeal pouch.

(Choice D) Most of the laryngeal cartilages develop from the 4th and 6th pharyngeal arches.

(Choice E) The palatine tonsils are derived from the second pharyngeal pouches.

Educational Objective:
Myasthenia gravis is associated with abnormalities of the thymus (e.g. thymoma, thymic hyperplasia). The thymus and inferior parathyroid glands arise from the 3rd pharyngeal pouch.

1	Epithelium of middle ear and auditory tube	Tympanic membrane	Epithelium of external ear canal
2	Epithelium of palatine tonsil crypts	Obliterated	
3	Thymus, inferior parathyroid glands	Obliterated	
4	Superior parathyroid glands, ultimobranchial body	Obliterated	

(Choice A) The floor of the foregut gives rise to the thyroid diverticulum. The thyroid diverticulum migrates caudally to the neck, but remains attached to the floor of the mouth by the thyroglossal duct.

(Choice B) The superior parathyroid glands and ultimobranchial body are formed from the 4th pharyngeal pouch.

(Choice D) Most of the laryngeal cartilages develop from the 4th and 6th pharyngeal arches.

(Choice E) The palatine tonsils are derived from the second pharyngeal pouches.

Educational Objective:
Myasthenia gravis is associated with abnormalities of the thymus (e.g. thymoma, thymic hyperplasia). The thymus and inferior parathyroid glands arise from the 3rd pharyngeal pouch.

Embryology	Rheumatology/Orthopedics & Sports	Myasthenia gravis
Subject	System	Topic

Copyright © UWorld. All rights reserved.

Settings

1 2 3 4 5 6 7 8 9 10 11 12 13 14 15 16 17 18 19 20 21 22 23 24 25 26 27 28 29 30

Item 20 of 40
Question Id: 437

Mark | Previous | Next | Full Screen | Tutorial | Lab Values | Notes | Calculator | Reverse Color | Text Zoom | Settings

A 32-year-old man presents to the emergency department with a one-day history of severe abdominal pain along with nausea and vomiting. His pain is constant and radiates to his back. He admits to "drinking a few beers" with some friends a couple days ago. Laboratory studies reveal significantly elevated amylase and lipase. An abdominal CT shows pancreas divisum, a common congenital anomaly that results from failure of the pancreatic ductal systems of the ventral and dorsal pancreatic primordia to fuse during embryogenesis. Which of the following pancreatic structures is derived from the ventral pancreatic primordium?

A. Tail

B. Body

C. Superior aspect of the head

D. Accessory pancreatic duct

E. Main pancreatic duct

Submit

Block Time Remaining: 00:00:49
TUTOR

1 | Feedback | Suspend | End Block

A 32-year-old man presents to the emergency department with a one-day history of severe abdominal pain along with nausea and vomiting. His pain is constant and radiates to his back. He admits to "drinking a few beers" with some friends a couple days ago. Laboratory studies reveal significantly elevated amylase and lipase. An abdominal CT shows pancreas divisum, a common congenital anomaly that results from failure of the pancreatic ductal systems of the ventral and dorsal pancreatic primordia to fuse during embryogenesis. Which of the following pancreatic structures is derived from the ventral pancreatic primordium?

- A. Tail (7%)
- B. Body (5%)
- C. Superior aspect of the head (22%)
- D. Accessory pancreatic duct (15%)
- ✓ E. Main pancreatic duct (49%)

Omitted
Correct answer
E

49%
Answered correctly

02 secs
Time Spent

06/23/2020
Last Updated

Explanation

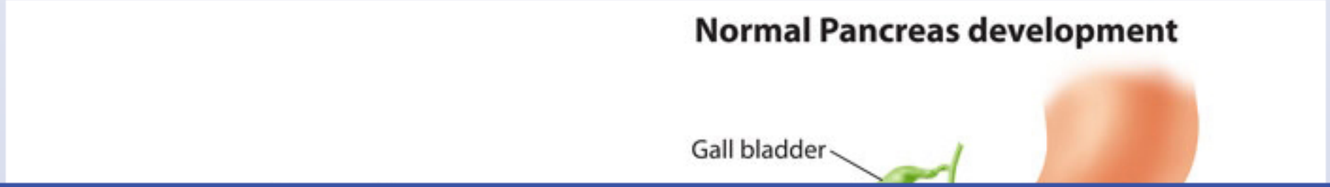

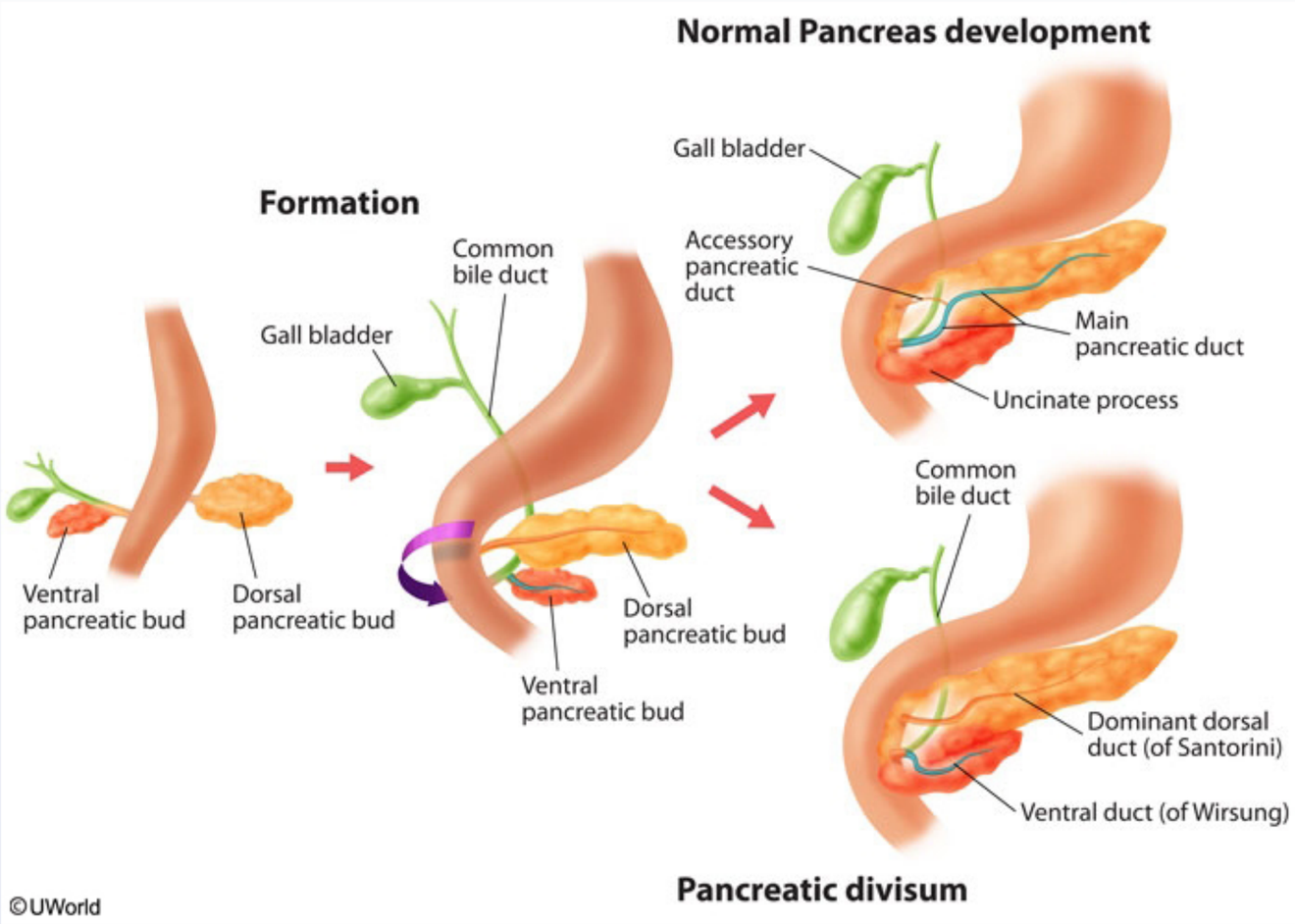

Early in fetal life, the duodenal portion of the foregut gives rise to the dorsal and ventral pancreatic buds. The dorsal pancreatic bud forms the pancreatic tail, body, most of the head, and the small accessory pancreatic duct. The smaller ventral bud gives rise to the uncinate process, a portion of the pancreatic head, and the proximal portion of the main pancreatic duct. The dorsal and ventral pancreatic buds then fuse during the eighth week of fetal life. The proximal part of the dorsal (accessory) pancreatic duct often degenerates, although it may persist as a functional lesser pancreatic duct. The remainder of the accessory duct fuses with the ventral duct to form the main pancreatic duct (of Wirsung).

Early in fetal life, the duodenal portion of the foregut gives rise to the dorsal and ventral pancreatic buds. The dorsal pancreatic bud forms the pancreatic tail, body, most of the head, and the small accessory pancreatic duct. The smaller ventral bud gives rise to the uncinate process, a portion of the pancreatic head, and the proximal portion of the main pancreatic duct. The dorsal and ventral pancreatic buds then fuse during the eighth week of fetal life. The proximal part of the dorsal (accessory) pancreatic duct often degenerates, although it may persist as a functional lesser pancreatic duct. The remainder of the accessory duct fuses with the ventral duct to form the main pancreatic duct (of Wirsung).

Pancreas divisum occurs when the ventral and dorsal pancreatic buds fail to fuse; the pancreatic secretions are instead drained via two separate duct systems. The dominant dorsal duct (of Santorini) opens into the duodenum via the minor papilla, and is responsible for draining the majority of the pancreas. The smaller ventral duct (of Wirsung) opens into the major papilla, and functions to drain the inferior/posterior portion of the head and uncinate process. Pancreas divisum is found in 5% of the population and is usually clinically silent. It is commonly detected as an incidental finding on imaging studies or at autopsy. In some, it may predispose to the development of recurrent pancreatitis.

(Choices A, B, C and D) The pancreatic tail, body, superior aspect of the head, and accessory pancreatic duct are derivatives of the dorsal pancreatic bud.

Educational objective:
The dorsal pancreatic bud forms the majority of pancreatic tissue (body, tail, and most of the head). The ventral pancreatic bud is a precursor of the uncinate process, inferior/posterior portion of the head, and major pancreatic duct (of Wirsung). Failure of the dorsal and ventral pancreatic buds to fuse leads to pancreas divisum. In this condition, the pancreatic ductal systems remain separate, with the accessory duct draining the majority of the pancreas.

References

- Clinical significance of the accessory pancreatic duct.

Embryology	Gastrointestinal & Nutrition	Acute pancreatitis
Subject	System	Topic

Copyright © UWorld. All rights reserved.

The concentrations of two substances in the amniotic fluid of a pregnant woman are graphed below.

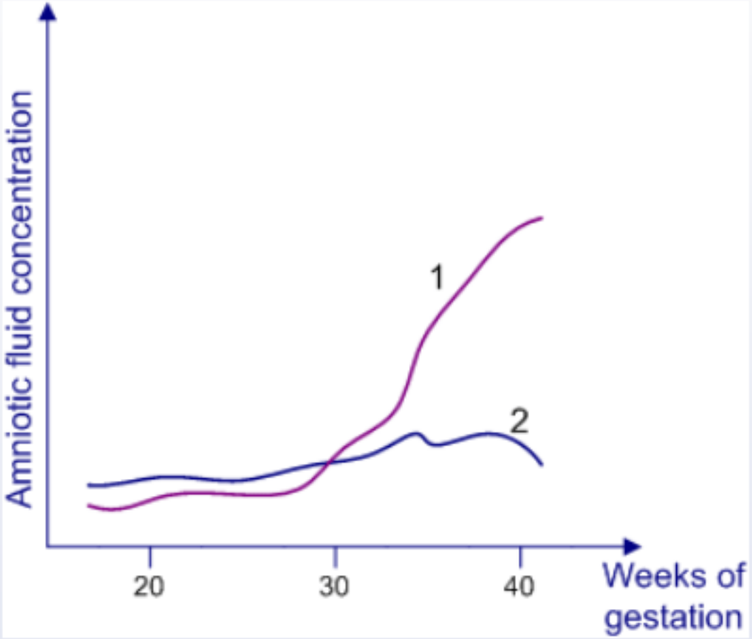

The two curves most likely correspond to:

A. Curve 1 – phosphatidylglycerol; Curve 2 – phosphatidylcholine

B. Curve 1 – sphingomyelin; Curve 2 – albumin

C. Curve 1 – phosphatidylcholine; Curve 2 – sphingomyelin

D. Curve 1 – sphingomyelin; Curve 2 – phosphatidylglycerol

E. Curve 1 – albumin; Curve 2 – phosphatidylcholine

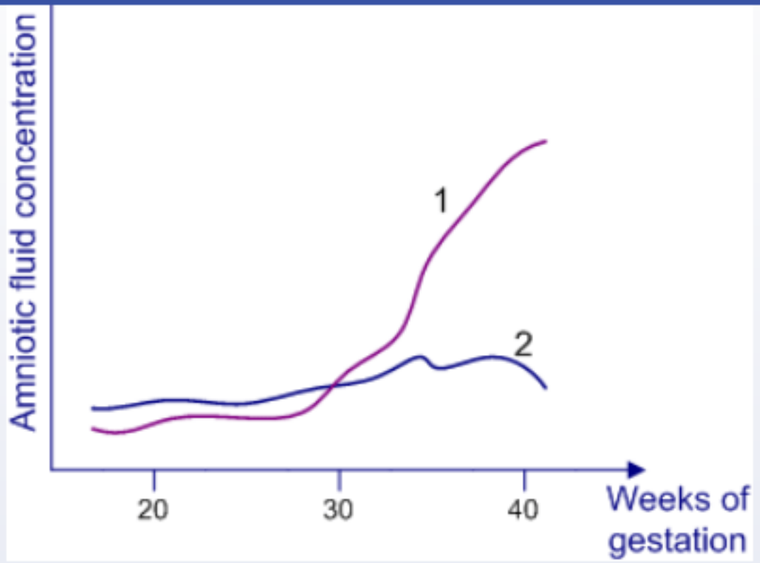

The two curves most likely correspond to:

- A. Curve 1 – phosphatidylglycerol; Curve 2 – phosphatidylcholine
- B. Curve 1 – sphingomyelin; Curve 2 – albumin
- C. Curve 1 – phosphatidylcholine; Curve 2 – sphingomyelin
- D. Curve 1 – sphingomyelin; Curve 2 – phosphatidylglycerol
- E. Curve 1 – albumin; Curve 2 – phosphatidylcholine

Submit

1 2 3 4 5 6 7 8 9 10 11 12 13 14 15 16 17 18 19 20 21 22 23 24 25 26 27 28 29 30

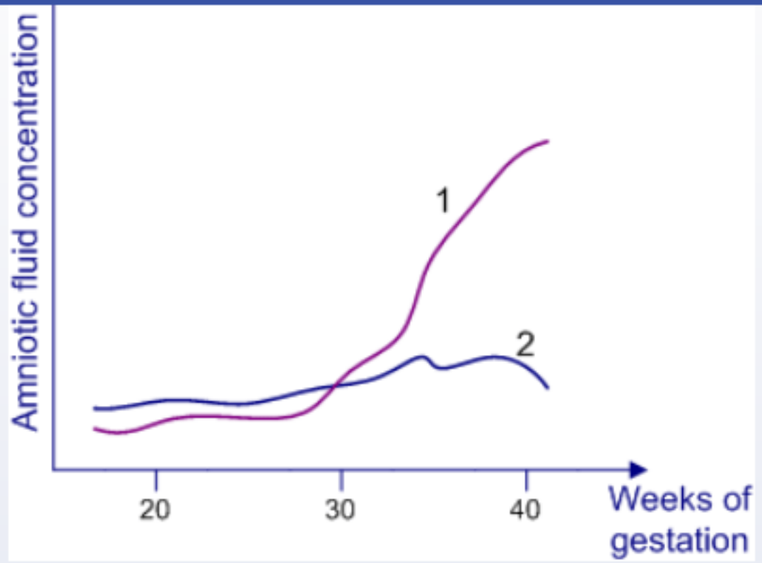

The two curves most likely correspond to:

- A. Curve 1 – phosphatidylglycerol; Curve 2 – phosphatidylcholine (4%)
- B. Curve 1 – sphingomyelin; Curve 2 – albumin (4%)
- ✓ C. Curve 1 – phosphatidylcholine; Curve 2 – sphingomyelin (72%)
- D. Curve 1 – sphingomyelin; Curve 2 – phosphatidylglycerol (15%)
- E. Curve 1 – albumin; Curve 2 – phosphatidylcholine (2%)

Omitted
Correct answer

72%
Answered correctly

06 secs
Time Spent

06/21/2020
Last Updated

Explanation

Phosphatidylcholine (also known as lecithin) is a component of pulmonary surfactant and sphingomyelin is a common membrane phospholipid. A commonly used measure of fetal lung maturity is the amniotic fluid lecithin/sphingomyelin (L/S) ratio. The amniotic fluid concentration of lecithin approximately equals that of sphingomyelin until the middle of the 3rd trimester, at which point mature type II pneumocytes begin secreting surfactant. The lecithin concentration then increases sharply while the sphingomyelin level remains unchanged. By 35 weeks gestation, the L/S ratio averages 2:1 or higher, indicating lung maturity.

(Choice A) Phosphatidylglycerol is a component of surfactant. Its levels in amniotic fluid begin to increase after 36 weeks of gestation, in parallel with increased surfactant production by the maturing fetal lung. Phosphatidylcholine (lecithin) is also a component of surfactant. Its level in amniotic fluid rises sharply after 30 weeks gestation.

(Choice B) During the third trimester, amniotic fluid sphingomyelin levels remain unchanged, as sphingomyelin is a common membrane phospholipid and only a minor component of pulmonary surfactant. Amniotic fluid total protein and albumin concentrations normally decrease by about 50% from early gestation to term.

Educational Objective:
Dipalmitoyl phosphatidylcholine (lecithin, L) and phosphatidylglycerol are major constituents of surfactant. Fetal lung lecithin production increases sharply after 30 weeks gestation, and phosphatidylglycerol production increases at 36 weeks gestation. The amniotic fluid sphingomyelin (S) level should remain approximately constant during the third trimester. An L/S ratio $\geq$ 2.0 indicates adequate surfactant production to avoid neonatal hyaline membrane disease.

Embryology	Pulmonary & Critical Care	Neonatal respiratory distress syndrome
Subject	System	Topic

Copyright © UWorld. All rights reserved.

1 2 3 4 5 6 7 8 9 10 11 12 13 14 15 16 17 18 19 20 21 22 23 24 25 26 27 28 29 30

A 5-month-old boy is brought to the office for right-sided scrotal enlargement. The enlargement has been present since birth and increases when he cries or strains to pass a bowel movement. There is no history of trauma or infection. The boy's parents do not believe he is in pain and have not noted discoloration of the area. On ultrasonography, the enlargement is found to be a fluid collection around the right testis. The specific embryologic defect giving rise to this patient's condition can also lead directly to which of the following?

- A. Direct inguinal hernia
- B. Femoral hernia
- C. Hypospadias
- D. Indirect inguinal hernia
- E. Orchitis
- F. Testicular torsion

Submit

1 2 3 4 5 6 7 8 9 10 11 12 13 14 15 16 17 18 19 20 21 22 23 24 25 26 27 28 29 30

A 5-month-old boy is brought to the office for right-sided scrotal enlargement. The enlargement has been present since birth and increases when he cries or strains to pass a bowel movement. There is no history of trauma or infection. The boy's parents do not believe he is in pain and have not noted discoloration of the area. On ultrasonography, the enlargement is found to be a fluid collection around the right testis. The specific embryologic defect giving rise to this patient's condition can also lead directly to which of the following?

- A. Direct inguinal hernia (14%)
- B. Femoral hernia (0%)
- C. Hypospadias (3%)
- ✓ D. Indirect inguinal hernia (67%)
- E. Orchitis (4%)
- F. Testicular torsion (9%)

Omitted
Correct answer
D

67%
Answered correctly

01 sec
Time Spent

06/20/2020
Last Updated

Explanation

Indirect inguinal hernia

Normal anatomy | **Indirect inguinal hernia**

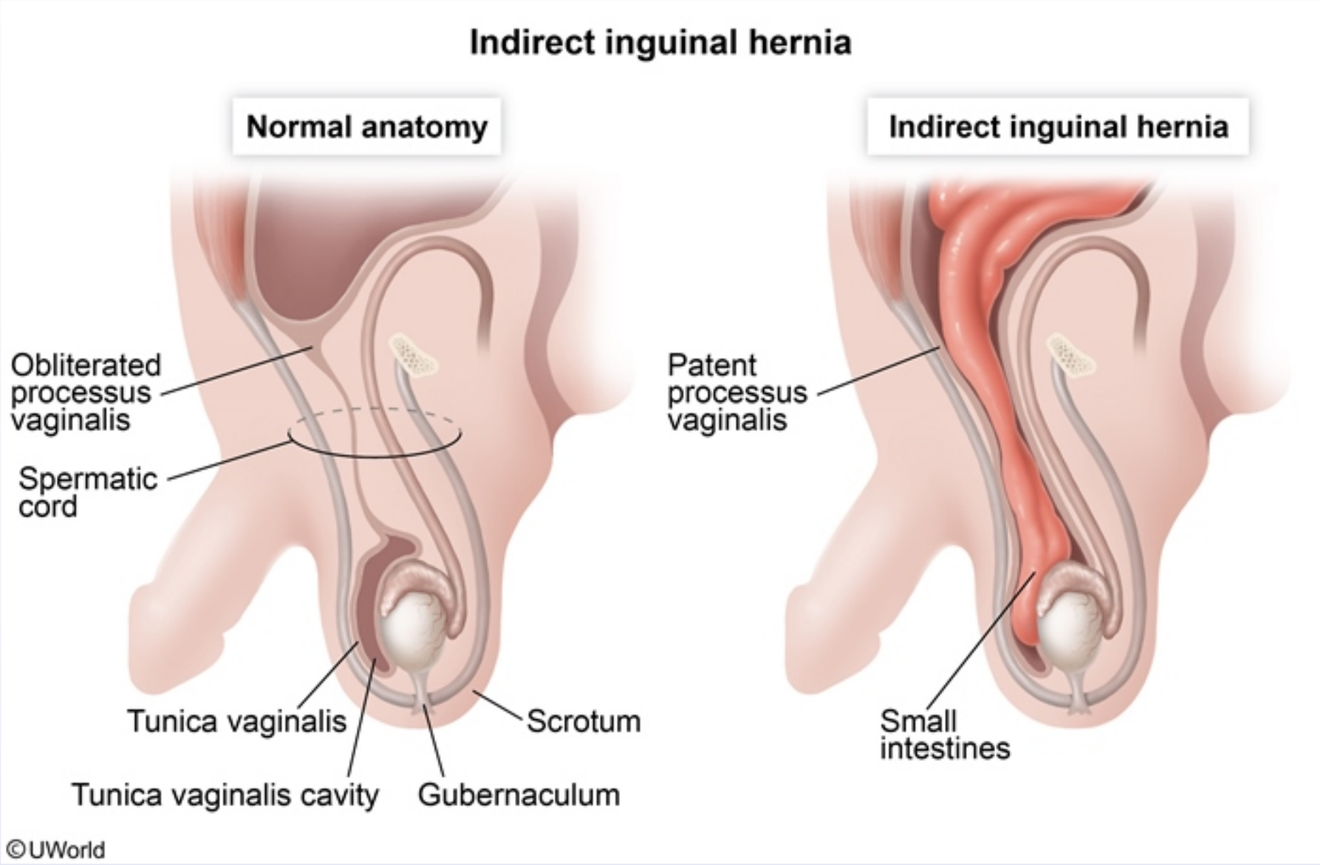

Early in normal gestation, the testes are located in the retroperitoneal region and subsequently descend into the scrotum before birth. During descent, they are accompanied by an evagination of the peritoneum called the processus vaginalis, which then obliterates after descent is complete.

Failure of obliteration of the **processus vaginalis** leads to a persistent connection between the scrotum and the peritoneal cavity through the inguinal canal. If the opening is small and allows for **fluid leakage** only, a communicating hydrocele develops. Diagnosis is made clinically through transillumination of the scrotum; a scrotal ultrasound would reveal fluid surrounding the affected testicle.

Early in normal gestation, the testes are located in the retroperitoneal region and subsequently descend into the scrotum before birth. During descent, they are accompanied by an evagination of the peritoneum called the processus vaginalis, which then obliterates after descent is complete.

Failure of obliteration of the **processus vaginalis** leads to a persistent connection between the scrotum and the peritoneal cavity through the inguinal canal. If the opening is small and allows for **fluid leakage** only, a communicating hydrocele develops. Diagnosis is made clinically through transillumination of the scrotum; a scrotal ultrasound would reveal fluid surrounding the affected testicle.

If the communication between the peritoneal cavity and the scrotum is large enough to allow for the **passage of abdominal organs**, an **indirect inguinal hernia** develops. Indirect inguinal hernias are common in children. They pass through the deep inguinal ring, are covered by internal spermatic fascia, and are located lateral to the inferior epigastric blood vessels. Hydroceles and indirect inguinal hernias both can present as an asymptomatic scrotal mass that increases in size during Valsalva maneuvers.

(Choice A) Direct inguinal hernias are an acquired protrusion of abdominal contents through a weakness of the abdominal wall (Hesselbach triangle). Direct inguinal hernias do not pass through the inguinal canal and are located medial to the inferior epigastric blood vessels.

(Choice B) Femoral hernias are an acquired protrusion of abdominal contents through a weakness of the femoral canal. They are the least common type of hernia.

(Choice C) Hypospadias occurs due to incomplete fusion of the urethral folds and presents as a ventrally located urethra.

(Choice E) Orchitis is a non-specific inflammation of the testes that is classically associated with mumps. In young adults and adolescents, it is commonly caused by *Chlamydia trachomatis* and *Neisseria gonorrhoeae*. In older patients, *Escherichia coli* is the most common causative agent.

(Choice F) Testicular torsion is a rotation of the testes around the spermatic cord leading to acute testicular pain. Trauma or a congenitally-horizontal positioning of the testes ("bell clapper deformity") facilitates torsion.

Educational objective:
Communicating hydroceles and indirect inguinal hernias are caused by an incomplete obliteration of the processus vaginalis. The resultant connection between the scrotum and abdominal cavity can allow for fluid leakage (hydrocele) or the passage of abdominal contents (indirect inguinal hernia).

Settings

1 2 3 4 5 6 7 8 9 10 11 12 13 14 15 16 17 18 19 20 21 22 23 24 25 26 27 28 29 30

Item 22 of 40
Question Id: 419

Mark | Previous | Next | Full Screen | Tutorial | Lab Values | Notes | Calculator | Reverse Color | Text Zoom | Settings

Early in normal gestation, the testes are located in the retroperitoneal region and subsequently descend into the scrotum before birth. During

Exhibit Display

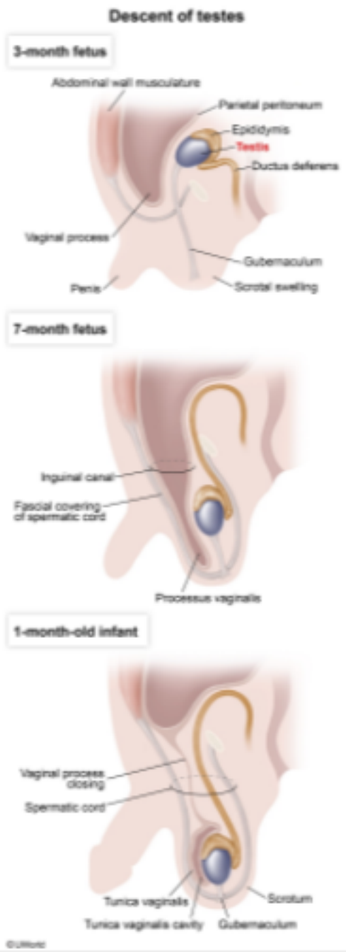

Zoom In | Zoom Out | Reset | Add To New Card | Existing Card

Block Time Remaining: 00:00:57
TUTOR

5 | Feedback | Suspend | End Block

Early in normal gestation, the testes are located in the retroperitoneal region and subsequently descend into the scrotum before birth. During

Exhibit Display

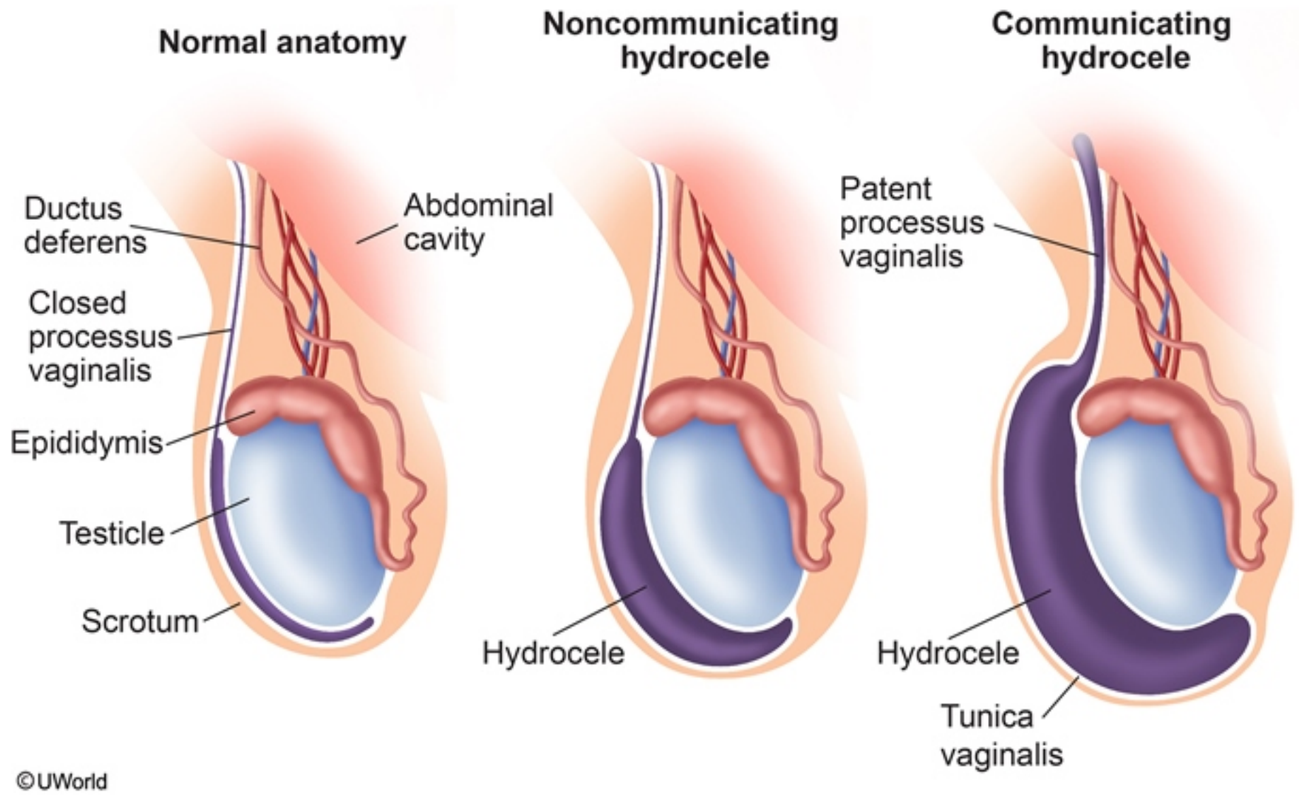

Zoom In | Zoom Out | Reset | Add To New Card | Existing Card

Early in normal gestation, the testes are located in the retroperitoneal region and subsequently descend into the scrotum before birth. During

Exhibit Display

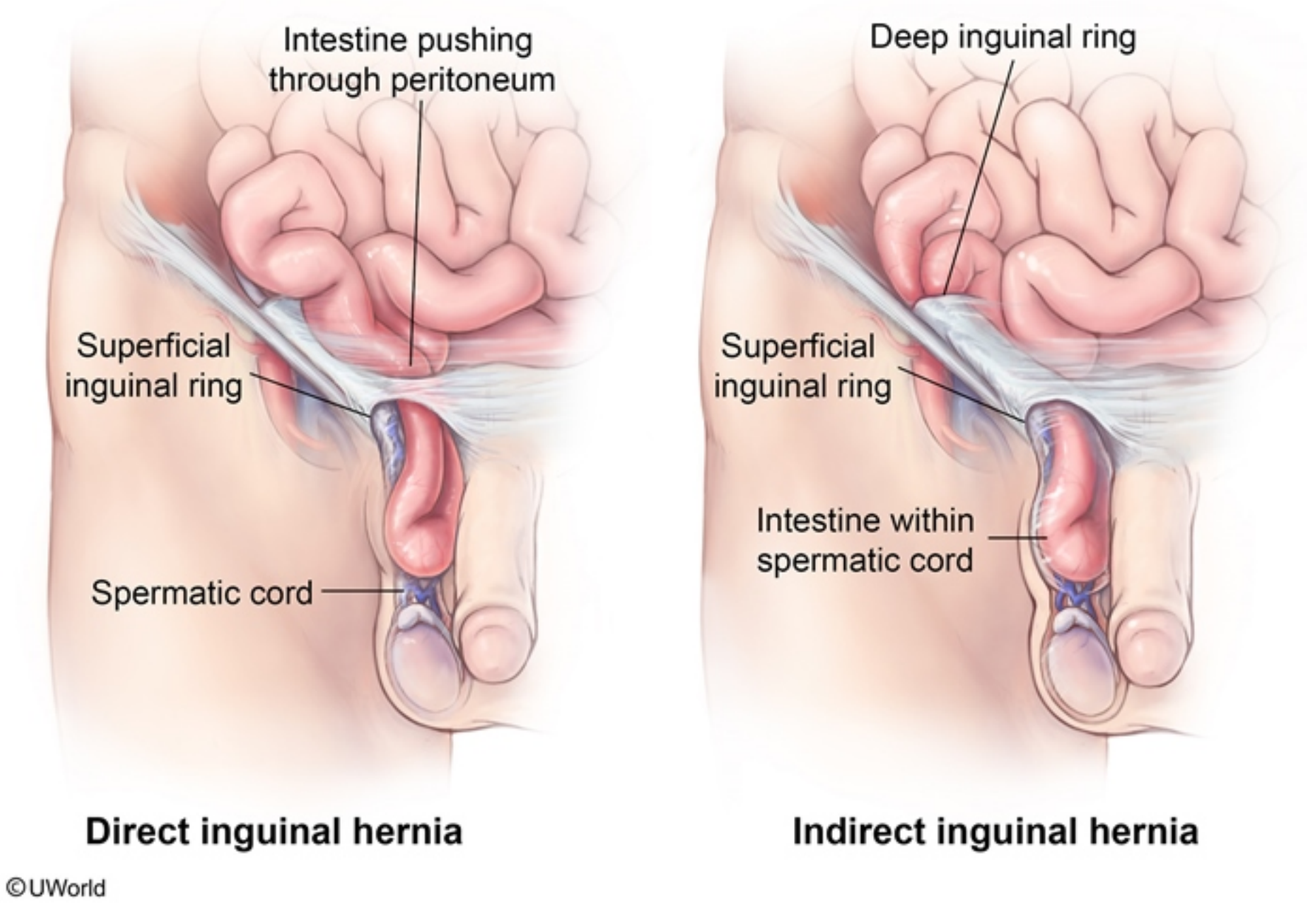

Zoom In | Zoom Out | Reset | Add To New Card | Existing Card

inguinal hernia develops. Indirect inguinal hernias are common in children. They pass through the deep inguinal ring, are covered by internal spermatic fascia, and are located lateral to the inferior epigastric blood vessels. Hydroceles and indirect inguinal hernias both can present as an asymptomatic scrotal mass that increases in size during Valsalva maneuvers.

(Choice A) Direct inguinal hernias are an acquired protrusion of abdominal contents through a weakness of the abdominal wall (Hesselbach triangle). Direct inguinal hernias do not pass through the inguinal canal and are located medial to the inferior epigastric blood vessels.

(Choice B) Femoral hernias are an acquired protrusion of abdominal contents through a weakness of the femoral canal. They are the least common type of hernia.

(Choice C) Hypospadias occurs due to incomplete fusion of the urethral folds and presents as a ventrally located urethra.

(Choice E) Orchitis is a non-specific inflammation of the testes that is classically associated with mumps. In young adults and adolescents, it is commonly caused by *Chlamydia trachomatis* and *Neisseria gonorrhoeae*. In older patients, *Escherichia coli* is the most common causative agent.

(Choice F) Testicular torsion is a rotation of the testes around the spermatic cord leading to acute testicular pain. Trauma or a congenitally-horizontal positioning of the testes ("bell clapper deformity") facilitates torsion.

Educational objective:
Communicating hydroceles and indirect inguinal hernias are caused by an incomplete obliteration of the processus vaginalis. The resultant connection between the scrotum and abdominal cavity can allow for fluid leakage (hydrocele) or the passage of abdominal contents (indirect inguinal hernia).

References

- Hernias and hydroceles.

Embryology	Male Reproductive System	Hydrocele
Subject	System	Topic

Copyright © UWorld. All rights reserved.

A 13-year-old boy is brought to the clinic due to progressive difficulty breathing, hoarseness, and dysphagia. The symptoms began insidiously 6 months ago but have rapidly become worse in the last 4 weeks. The patient has no associated skin rash, pharyngeal pain, fever, weight loss, or loss of appetite. Medical history is unremarkable, and the patient takes no medications. He is up to date on scheduled vaccinations. The patient's parents and siblings have no history of significant health problems. Vital signs are normal, and he is at 70th percentile for height and weight. Oropharyngeal examination reveals a large, red lingual mass. The patient subsequently undergoes excision of the mass; histopathologic preparation of the recovered tissue is shown in the image below.

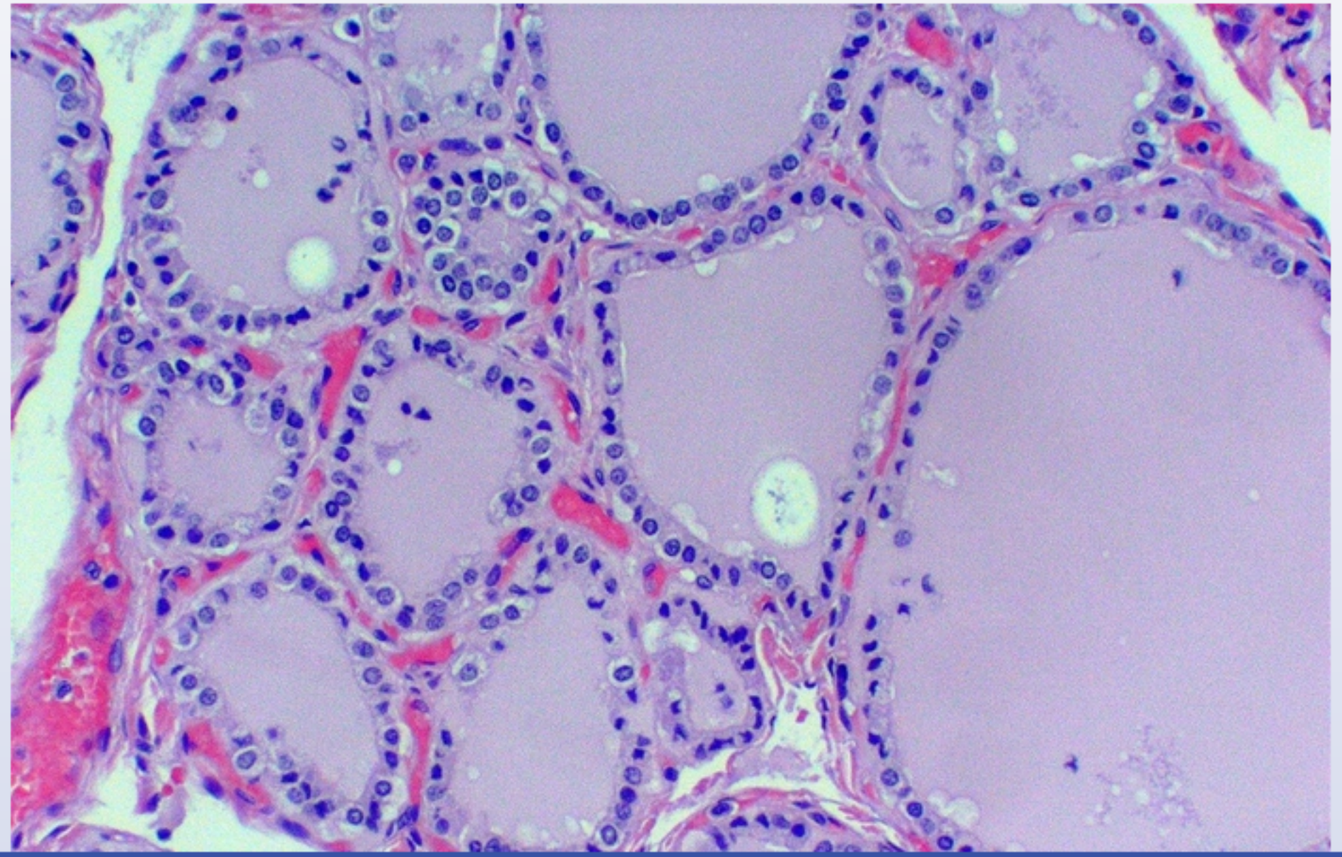

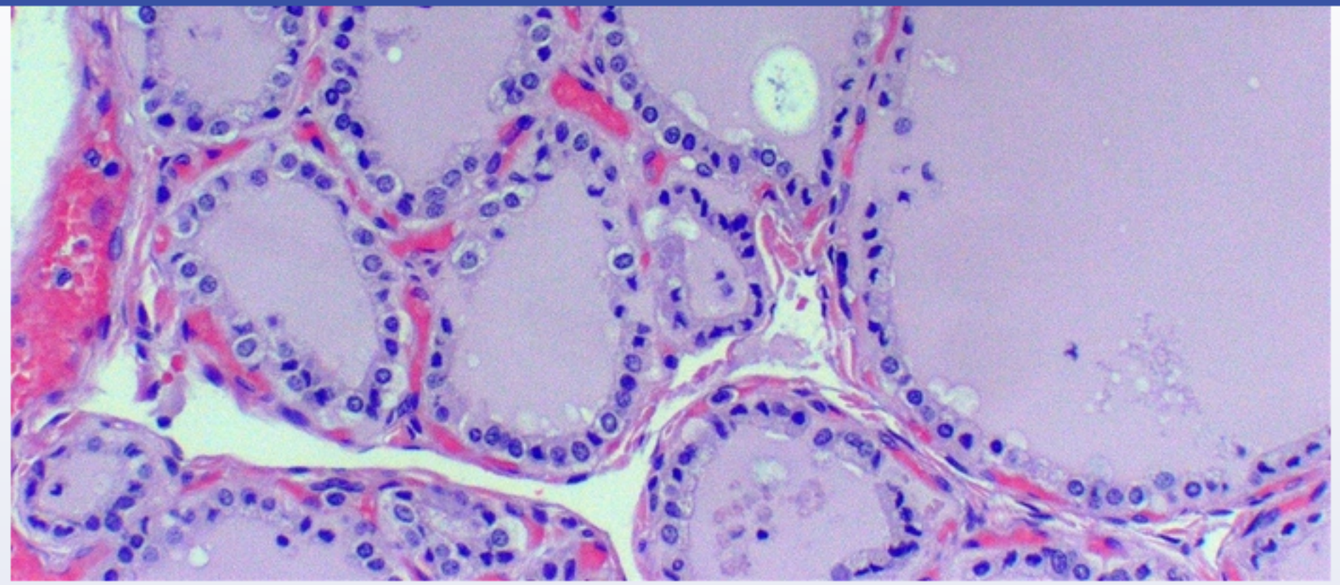

Failure of which of the following embryologic processes is most likely responsible for this patient's lesion?

- A. Apoptosis
- B. Differentiation
- C. Fusion
- D. Migration
- E. Proliferation

Submit

1 2 3 4 5 6 7 8 9 10 11 12 13 14 15 16 17 18 19 20 21 22 23 24 25 26 27 28 29 30

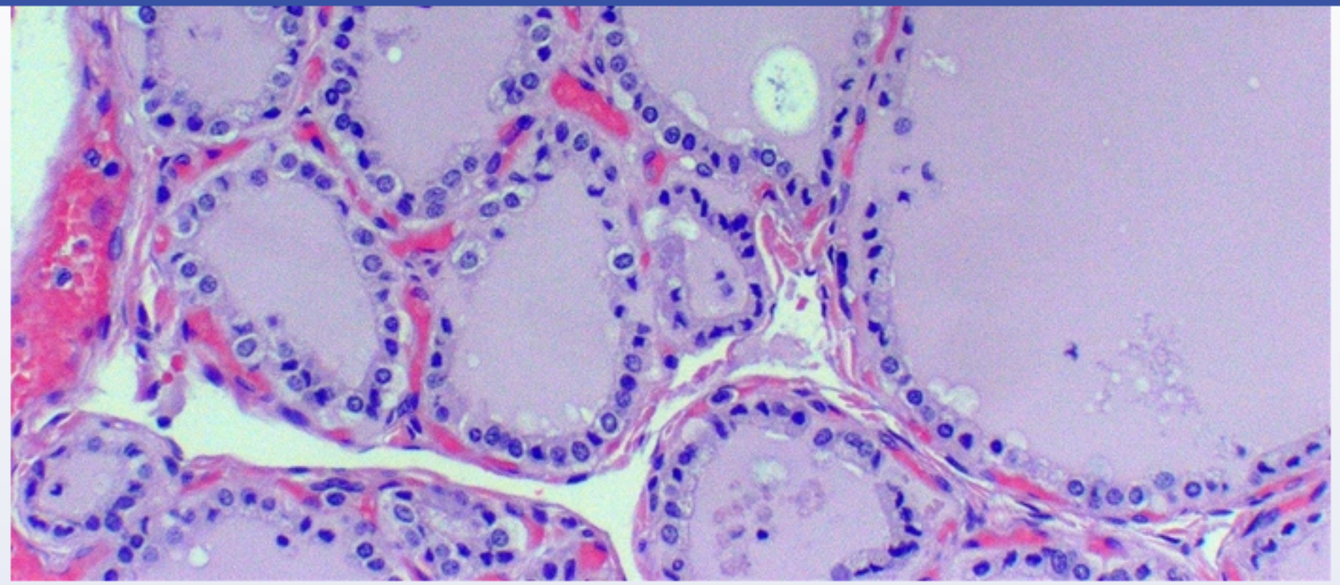

Failure of which of the following embryologic processes is most likely responsible for this patient's lesion?

A. Apoptosis (16%)

B. Differentiation (2%)

C. Fusion (1%)

✓ D. Migration (76%)

E. Proliferation (2%)

Omitted
Correct answer

76%
Answered correctly

04 secs
Time Spent

03/10/2020
Last Updated

1 2 3 4 5 6 7 8 9 10 11 12 13 14 15 16 17 18 19 20 21 22 23 24 25 26 27 28 29 30

Thyroid migration

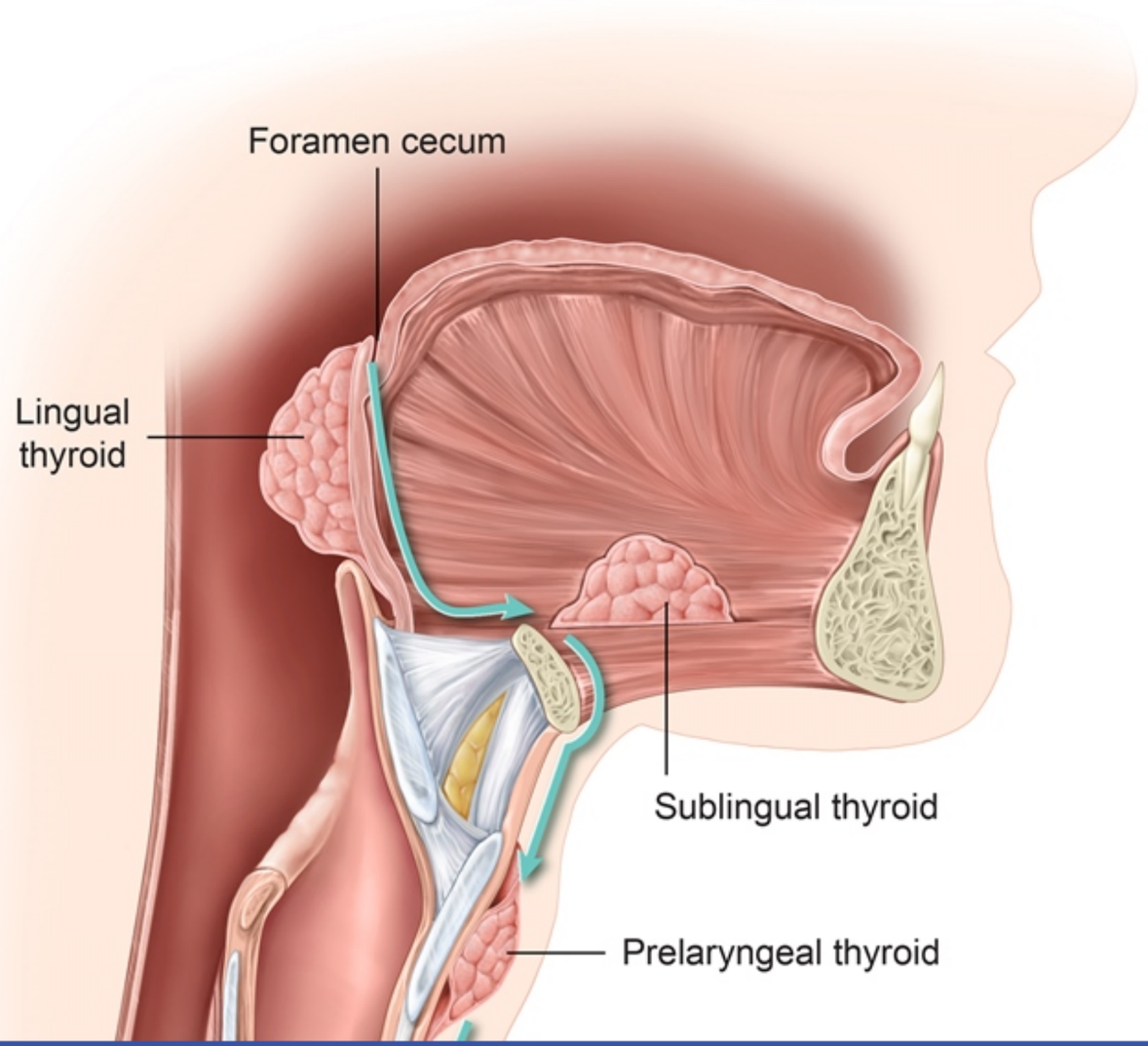

Settings

1 2 3 4 5 6 7 8 9 10 11 12 13 14 15 16 17 18 19 20 21 22 23 24 25 26 27 28 29 30

Item 23 of 40
Question Id: 763

Mark | Previous | Next | Full Screen | Tutorial | Lab Values | Notes | Calculator | Reverse Color | Text Zoom | Settings

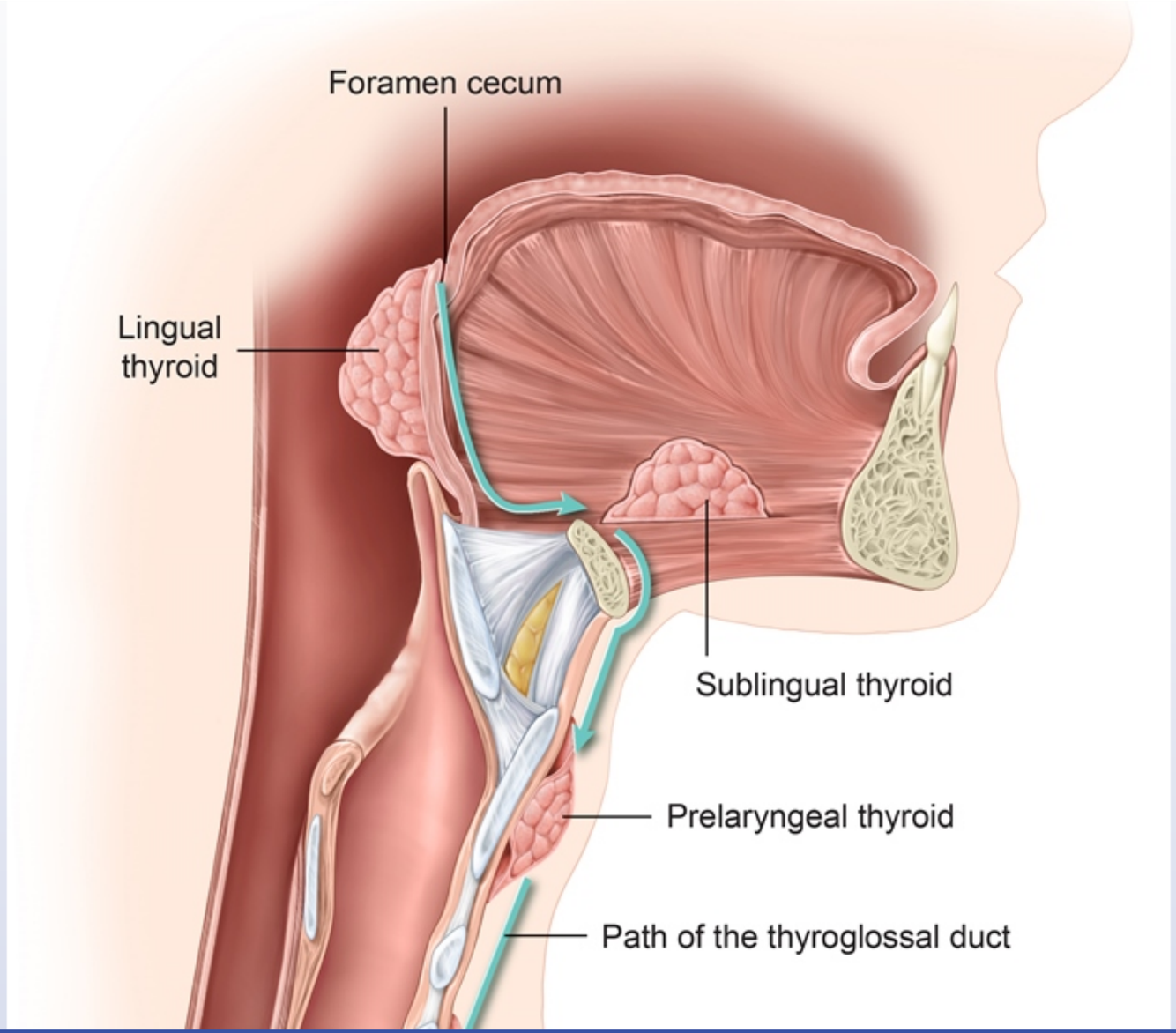

Block Time Remaining: 00:01:01
TUTOR

4 | Feedback | Suspend | End Block

1 2 3 4 5 6 7 8 9 10 11 12 13 14 15 16 17 18 19 20 21 22 23 24 25 26 27 28 29 30

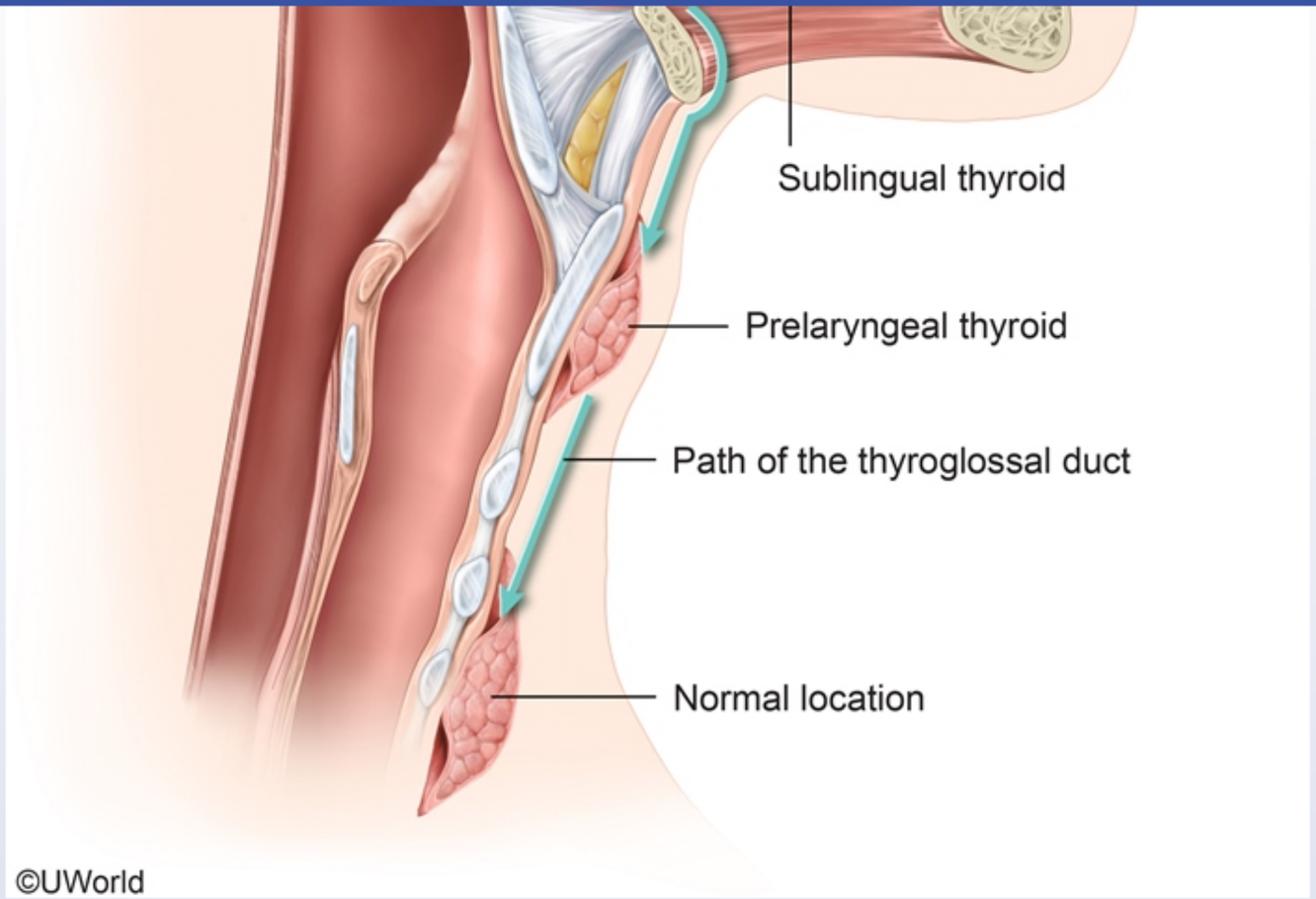

This patient's pathologic specimen shows normal thyroid follicles containing colloid, consistent with a **lingual thyroid**. The thyroid gland is formed from an outpouching (evagination) of the pharyngeal epithelium and subsequently descends to the lower neck anterior to the upper trachea and larynx. The lowest part of the evagination forms the thyroid gland and the remaining portion forms the **thyroglossal duct**, which extends from the foramen cecum on the dorsal surface of the tongue to the superior border of the thyroid isthmus.

Due to **failure of migration**, the thyroid can reside anywhere along the thyroglossal duct's usual path, including the tongue (lingual thyroid).

This patient's pathologic specimen shows normal thyroid follicles containing colloid, consistent with a **lingual thyroid**. The thyroid gland is formed from an outpouching (evagination) of the pharyngeal epithelium and subsequently descends to the lower neck anterior to the upper trachea and larynx. The lowest part of the evagination forms the thyroid gland and the remaining portion forms the **thyroglossal duct**, which extends from the foramen cecum on the dorsal surface of the tongue to the superior border of the thyroid isthmus.

Due to **failure of migration**, the thyroid can reside anywhere along the thyroglossal duct's usual path, including the tongue (lingual thyroid). Enlargement of a lingual thyroid can lead to **obstructive symptoms** (eg, dysphagia, dysphonia, dyspnea), typically during times of heightened thyroid stimulation (eg, puberty, pregnancy). Sometimes, this lingual thyroid is the only thyroid tissue in the body, so significant hypothyroidism occurs if it is removed.

(Choice A) Apoptosis is a process of programmed cell death and is important in regulating the turnover of cells. Inappropriate apoptosis is responsible for a number of endocrine diseases, including type 1 diabetes mellitus, in which beta cells undergo pathologic apoptosis.

(Choice B) Differentiation is the formation of mature cells from undifferentiated precursor cells (eg, formation of red blood cells, white blood cells, and platelets from bone marrow stem cells). Although thyroid cells do differentiate after their descent from the pharynx, defective differentiation is not responsible for a lingual thyroid.

(Choice C) Fusion is the joining of cell lines from different origins to form a single organ system. The mature thyroid is formed by fusion of thyroid follicular cells (derived from the pharyngeal epithelium) and parafollicular C cells (originating in ultimobranchial bodies) as the thyroid descends through the neck. As a result, a lingual thyroid contains no C cells due to failure of migration.

(Choice E) Proliferation denotes an increase in the number of cells by mitosis. Some organs (eg, liver, gastrointestinal epithelium, bone marrow) require high proliferative rates, whereas cardiac and neuronal cells have a low proliferative capacity. Failure of proliferation in bone marrow leads to aplastic anemia.

Educational objective:
The thyroid gland is formed from evagination of the pharyngeal epithelium and descends to the lower neck. Due to failure of migration, the thyroid can reside anywhere along the thyroglossal duct's usual path, including the tongue (lingual thyroid).

References

- Morphological, diagnostic and surgical features of ectopic thyroid gland: a review of literature

Enlargement of a lingual thyroid can lead to **obstructive symptoms** (eg, dysphagia, dysphonia, dyspnea), typically during times of heightened thyroid stimulation (eg, puberty, pregnancy). Sometimes, this lingual thyroid is the only thyroid tissue in the body, so significant hypothyroidism occurs if it is removed.

(Choice A) Apoptosis is a process of programmed cell death and is important in regulating the turnover of cells. Inappropriate apoptosis is responsible for a number of endocrine diseases, including type 1 diabetes mellitus, in which beta cells undergo pathologic apoptosis.

(Choice B) Differentiation is the formation of mature cells from undifferentiated precursor cells (eg, formation of red blood cells, white blood cells, and platelets from bone marrow stem cells). Although thyroid cells do differentiate after their descent from the pharynx, defective differentiation is not responsible for a lingual thyroid.

(Choice C) Fusion is the joining of cell lines from different origins to form a single organ system. The mature thyroid is formed by fusion of thyroid follicular cells (derived from the pharyngeal epithelium) and parafollicular C cells (originating in ultimobranchial bodies) as the thyroid descends through the neck. As a result, a lingual thyroid contains no C cells due to failure of migration.

(Choice E) Proliferation denotes an increase in the number of cells by mitosis. Some organs (eg, liver, gastrointestinal epithelium, bone marrow) require high proliferative rates, whereas cardiac and neuronal cells have a low proliferative capacity. Failure of proliferation in bone marrow leads to aplastic anemia.

Educational objective:
The thyroid gland is formed from evagination of the pharyngeal epithelium and descends to the lower neck. Due to failure of migration, the thyroid can reside anywhere along the thyroglossal duct's usual path, including the tongue (lingual thyroid).

References

- Morphological, diagnostic and surgical features of ectopic thyroid gland: a review of literature.

Embryology	Endocrine, Diabetes & Metabolism	Ectopic thyroid
Subject	System	Topic

Copyright © UWorld. All rights reserved.

A 4-week-old boy is hospitalized with persistent vomiting, fussiness, and feeding intolerance. The emesis was initially clear but became bilious in the last few hours. The infant had been breastfeeding exclusively. His temperature is 37.2 C (99.0 F). Blood pressure and pulse are normal. Physical examination shows a normal abdomen with no rebound or guarding. An upper gastrointestinal series is obtained urgently to evaluate for malrotation and volvulus and shows normal rotation but constriction of the duodenum. An abdominal CT scan reveals pancreatic tissue encircling the duodenum. Which of the following is the most likely cause of this patient's condition?

A. Aberrant differentiation of the midgut structures

B. Abnormal migration of the ventral pancreatic bud

C. Ectopic rests not connected to the pancreas

D. Failure of apoptosis in the dorsal pancreatic bud

E. Failure of the ventral and dorsal pancreatic bud to fuse

Submit

A 4-week-old boy is hospitalized with persistent vomiting, fussiness, and feeding intolerance. The emesis was initially clear but became bilious in the last few hours. The infant had been breastfeeding exclusively. His temperature is 37.2 C (99.0 F). Blood pressure and pulse are normal. Physical examination shows a normal abdomen with no rebound or guarding. An upper gastrointestinal series is obtained urgently to evaluate for malrotation and volvulus and shows normal rotation but constriction of the duodenum. An abdominal CT scan reveals pancreatic tissue encircling the duodenum. Which of the following is the most likely cause of this patient's condition?

- A. Aberrant differentiation of the midgut structures (0%)
- ✓ B. Abnormal migration of the ventral pancreatic bud (74%)
- C. Ectopic rests not connected to the pancreas (1%)
- D. Failure of apoptosis in the dorsal pancreatic bud (6%)
- E. Failure of the ventral and dorsal pancreatic bud to fuse (16%)

Omitted
Correct answer
B

74%
Answered correctly

02 secs
Time Spent

06/27/2020
Last Updated

Explanation

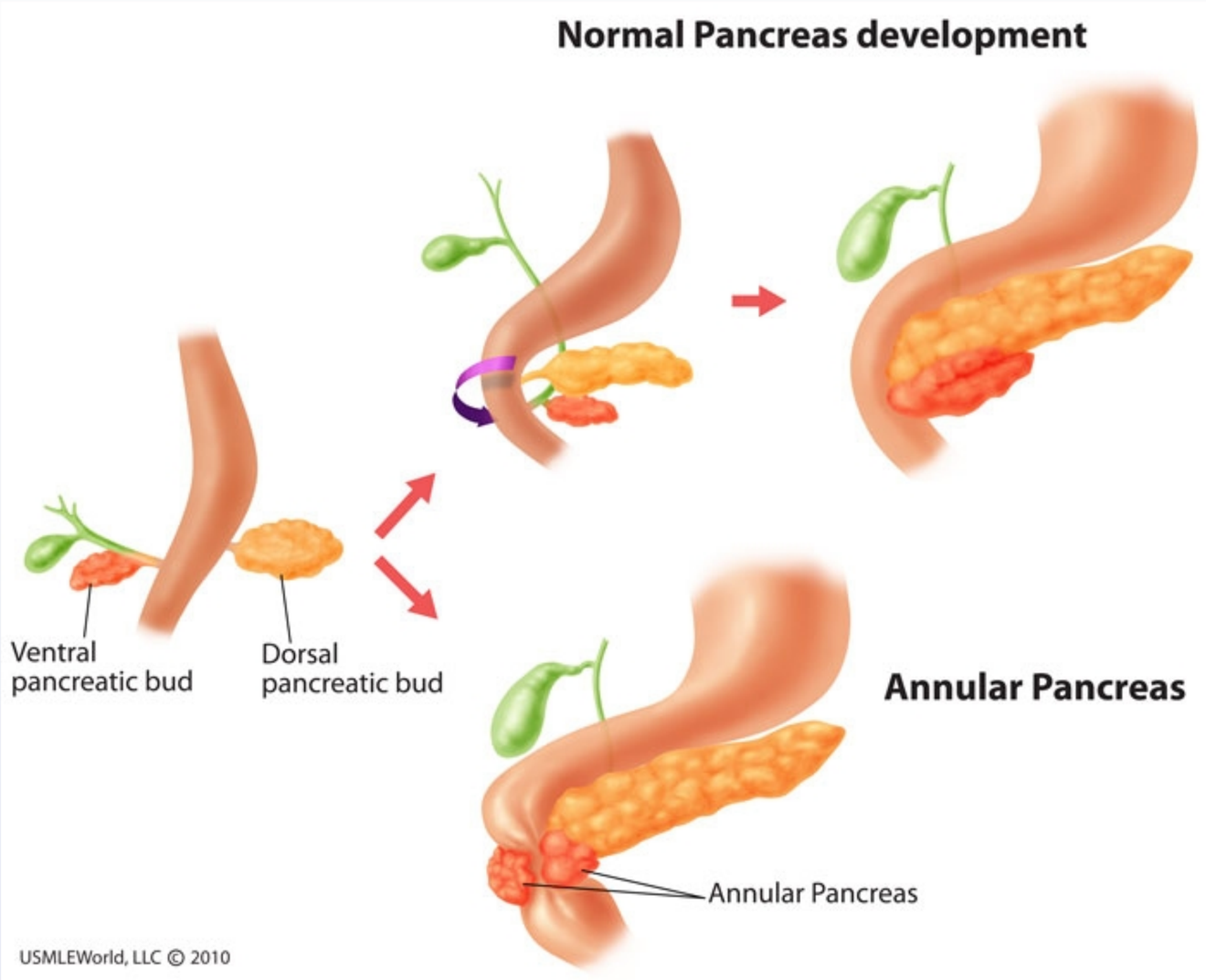

This patient has acute pancreatitis and radiographic evidence of **annular pancreas**, which results from abnormal migration of the ventral pancreatic bud. This bud is a **foregut** derivative that appears by the fifth week of gestation and **rotates behind** the duodenum during the seventh

This patient has acute pancreatitis and radiographic evidence of **annular pancreas**, which results from abnormal migration of the ventral pancreatic bud. This bud is a **foregut** derivative that appears by the fifth week of gestation and **rotates behind** the duodenum during the seventh week of fetal development. The ventral bud moves toward the midline, where it fuses with the dorsal pancreatic bud during the eighth week. The ventral pancreatic bud gives rise to the **uncinate process** portion of the head and the **main pancreatic duct** (of Wirsung). The pancreatic tail, body, and the remainder of head derive from the dorsal bud.

Abnormal migration of the ventral pancreatic bud can be caused by adherence to either the dorsal bud or duodenum before the rotation begins. This abnormal migration leads to **annular pancreas**, a rare congenital anomaly in which pancreatic tissue completely surrounds the second part of the duodenum. Annular pancreas can compress the duodenal lumen (causing **obstruction**) or result in obstructed pancreatic drainage (acute or chronic **pancreatitis**). However, the majority of patients with annular pancreas are **asymptomatic**.

(Choice A) The pancreas is not derived from the midgut. Both ventral and dorsal pancreatic buds form from the duodenal portion of the foregut.

(Choice C) Ectopic rests, or fragments of embryonic tissue that persist beyond the fetal period, can be found throughout the gastrointestinal tract. However, the pancreatic tissue in annular pancreas is contiguous with the rest of the pancreas by definition.

(Choice D) Neither the dorsal nor ventral pancreatic bud undergoes apoptosis in normal development.

(Choice E) Incomplete fusion of the ventral and dorsal pancreatic buds (pancreas divisum) is usually asymptomatic and much more common than annular pancreas. Pancreas divisum does not cause obstruction as the duodenum is not completely encircled but may predispose to the development of acute or chronic pancreatitis.

Educational objective:
Annular pancreas, or pancreatic tissue encircling the descending duodenum, is caused by failure of the ventral pancreatic bud to properly migrate and fuse with the dorsal bud during the seventh and eighth week of fetal development. Annular pancreas is usually asymptomatic but may present with duodenal obstruction or pancreatitis.

References

- Annular pancreas in adults: a report of two cases and review of literature.
- Disorders of the pediatric pancreas: imaging features

Abnormal migration of the ventral pancreatic bud can be caused by adherence to either the dorsal bud or duodenum before the rotation begins. This abnormal migration leads to **annular pancreas**, a rare congenital anomaly in which pancreatic tissue completely surrounds the second part of the duodenum. Annular pancreas can compress the duodenal lumen (causing **obstruction**) or result in obstructed pancreatic drainage (acute or chronic **pancreatitis**). However, the majority of patients with annular pancreas are **asymptomatic**.

(Choice A) The pancreas is not derived from the midgut. Both ventral and dorsal pancreatic buds form from the duodenal portion of the foregut.

(Choice C) Ectopic rests, or fragments of embryonic tissue that persist beyond the fetal period, can be found throughout the gastrointestinal tract. However, the pancreatic tissue in annular pancreas is contiguous with the rest of the pancreas by definition.

(Choice D) Neither the dorsal nor ventral pancreatic bud undergoes apoptosis in normal development.

(Choice E) Incomplete fusion of the ventral and dorsal pancreatic buds (pancreas divisum) is usually asymptomatic and much more common than annular pancreas. Pancreas divisum does not cause obstruction as the duodenum is not completely encircled but may predispose to the development of acute or chronic pancreatitis.

Educational objective:
Annular pancreas, or pancreatic tissue encircling the descending duodenum, is caused by failure of the ventral pancreatic bud to properly migrate and fuse with the dorsal bud during the seventh and eighth week of fetal development. Annular pancreas is usually asymptomatic but may present with duodenal obstruction or pancreatitis.

References

- Annular pancreas in adults: a report of two cases and review of literature.
- Disorders of the pediatric pancreas: imaging features.

Embryology	Gastrointestinal & Nutrition	Acute pancreatitis
Subject	System	Topic

Copyright © UWorld. All rights reserved.

1 2 3 4 5 6 7 8 9 10 11 12 13 14 15 16 17 18 19 20 21 22 23 24 25 26 27 28 29 30

A 1-hour-old boy is in the neonatal intensive care unit with tachypnea and hypoxia. The infant was born at 39 weeks gestation via cesarean delivery due to variable decelerations. The pregnancy was complicated by a lack of prenatal care. The infant weighs 3.2 kg (7 lb 1 oz). Physical examination shows a flattened nose and bilateral club feet. Breath sounds are markedly diminished bilaterally. The infant is intubated and mechanically ventilated, but his oxygen levels do not improve. The infant dies 1 hour later. Which of the following is most likely to be found during autopsy?

- A. Congenital diaphragmatic hernia
- B. Duodenal atresia
- C. Renal agenesis
- D. Surfactant deficiency
- E. Tracheoesophageal fistula

Submit

A 1-hour-old boy is in the neonatal intensive care unit with tachypnea and hypoxia. The infant was born at 39 weeks gestation via cesarean delivery due to variable decelerations. The pregnancy was complicated by a lack of prenatal care. The infant weighs 3.2 kg (7 lb 1 oz). Physical examination shows a flattened nose and bilateral club feet. Breath sounds are markedly diminished bilaterally. The infant is intubated and mechanically ventilated, but his oxygen levels do not improve. The infant dies 1 hour later. Which of the following is most likely to be found during autopsy?

- A. Congenital diaphragmatic hernia (5%)
- B. Duodenal atresia (3%)
- ✓ C. Renal agenesis (71%)
- D. Surfactant deficiency (11%)
- E. Tracheoesophageal fistula (7%)

Omitted
Correct answer
C

71%
Answered correctly

02 secs
Time Spent

02/06/2020
Last Updated

Explanation

Potter sequence

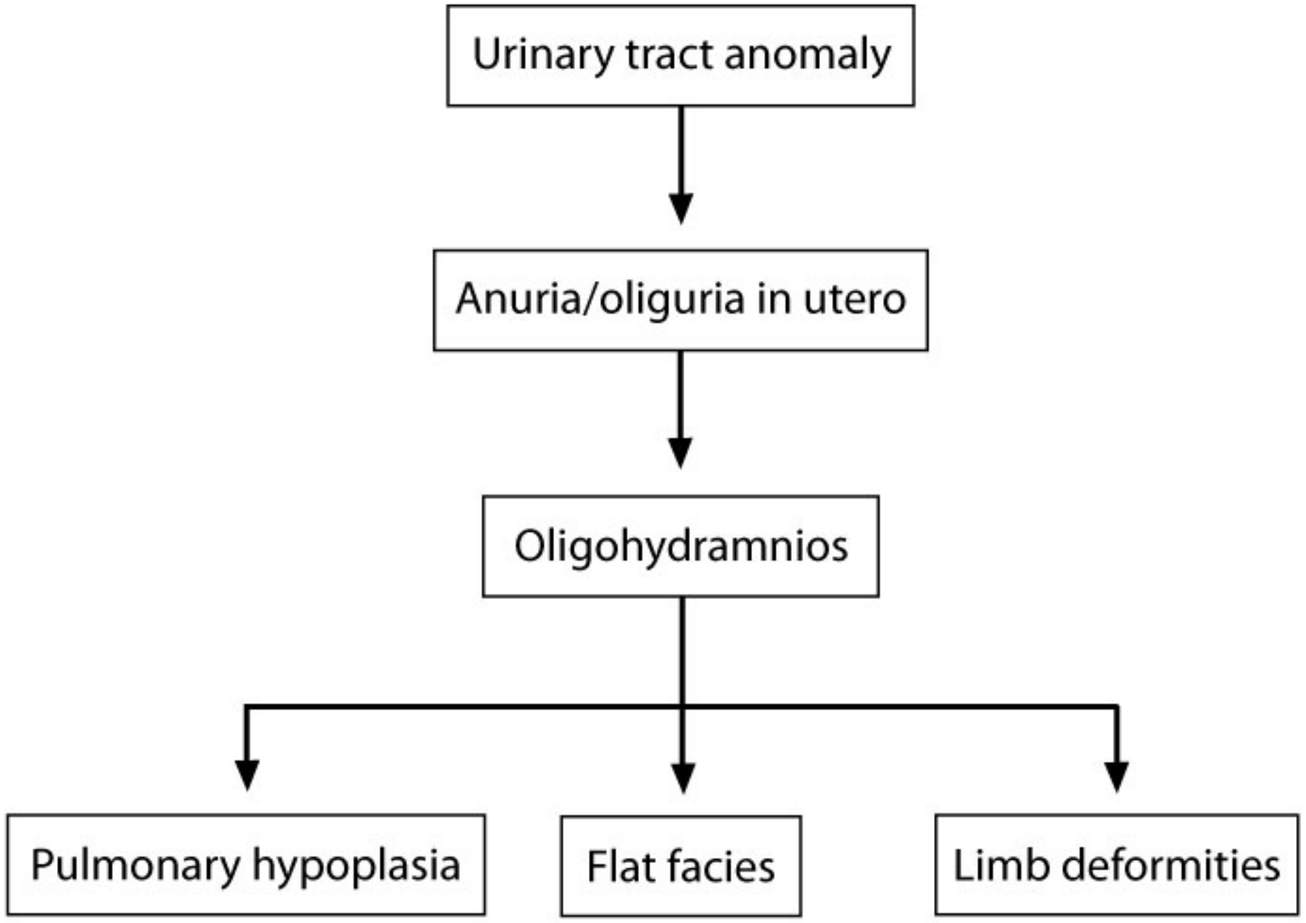

© USMLEWorld, LLC

© USMLEWorld, LLC

The infant described has features consistent with **Potter sequence** (**pulmonary hypoplasia** along with **facial** and **lower limb** deformities). Potter sequence is caused by a **renal anomaly** that leads to **decreased urine output** by the fetus. Bilateral renal agenesis is the classic finding, but other lesions such as posterior urethral valves or autosomal recessive polycystic kidney disease can be the cause. Because the volume of amniotic fluid depends on fetal urine production, affected infants have severely reduced (**oligohydramnios**) or absent amniotic fluid (anhydramnios). The lack of amniotic fluid causes external compression of the face (Potter facies) and lower extremities (club feet). In addition, the umbilical cord is often compressed and fetal heart rate anomalies are common during labor. Pulmonary hypoplasia results due to the lack of normal alveolar distension by aspirated amniotic fluid. Respiratory failure due to severe pulmonary hypoplasia is the most common cause of death among infants with Potter sequence.

(Choice A) Congenital diaphragmatic hernia causes severe respiratory disease, pulmonary hypertension, and absent breath sounds unilaterally but would not cause this infant's facial or lower limb findings.

(Choices B and E) Infants with gastrointestinal obstruction proximal to the small bowel (eg, esophageal or duodenal atresia) cannot absorb swallowed amniotic fluid, resulting in polyhydramnios.

(Choice D) Although surfactant deficiency (respiratory distress syndrome) can cause hypoxia and respiratory distress, it is most commonly associated with prematurity and would not cause facial or lower limb deformities.

Educational objective:
Potter sequence results from a renal anomaly that causes decreased fetal urine output leading to oligohydramnios. The lack of amniotic fluid causes compression of the fetus (characteristic facies and limb abnormalities) and pulmonary hypoplasia, which is the most common cause of death in affected infants.

Embryology	Renal, Urinary Systems & Electrolytes	Potter sequence
Subject	System	Topic

Copyright © UWorld. All rights reserved.

© USMLEWorld, LLC

The infant described has features consistent with **Potter sequence** (**pulmonary hypoplasia** along with **facial** and **lower limb** deformities). Potter sequence is caused by a **renal anomaly** that leads to **decreased urine output** by the fetus. Bilateral renal agenesis is the classic finding, but other lesions such as posterior urethral valves or autosomal recessive polycystic kidney disease can be the cause. Because the volume of amniotic fluid depends on fetal urine production, affected infants have severely reduced (**oligohydramnios**) or absent amniotic fluid (anhydramnios). The lack of amniotic fluid causes external compression of the face (Potter facies) and lower extremities (club feet). In addition, the umbilical cord is often compressed and fetal heart rate anomalies are common during labor. Pulmonary hypoplasia results due to the lack of normal alveolar distension by aspirated amniotic fluid. Respiratory failure due to severe pulmonary hypoplasia is the most common cause of death among infants with Potter sequence.

(Choice A) Congenital diaphragmatic hernia causes severe respiratory disease, pulmonary hypertension, and absent breath sounds unilaterally but would not cause this infant's facial or lower limb findings.

(Choices B and E) Infants with gastrointestinal obstruction proximal to the small bowel (eg, esophageal or duodenal atresia) cannot absorb swallowed amniotic fluid, resulting in polyhydramnios.

(Choice D) Although surfactant deficiency (respiratory distress syndrome) can cause hypoxia and respiratory distress, it is most commonly associated with prematurity and would not cause facial or lower limb deformities.

Educational objective:
Potter sequence results from a renal anomaly that causes decreased fetal urine output leading to oligohydramnios. The lack of amniotic fluid causes compression of the fetus (characteristic facies and limb abnormalities) and pulmonary hypoplasia, which is the most common cause of death in affected infants.

Embryology	Renal, Urinary Systems & Electrolytes	Potter sequence
Subject	System	Topic

Copyright © UWorld. All rights reserved.

Settings

1 2 3 4 5 6 7 8 9 10 11 12 13 14 15 16 17 18 19 20 21 22 23 24 25 26 27 28 29 30

Item 25 of 40
Question Id: 1752

Mark | Previous | Next | Full Screen | Tutorial | Lab Values | Notes | Calculator | Reverse Color | Text Zoom | Settings

© USMLEWorld, LLC

Exhibit Display

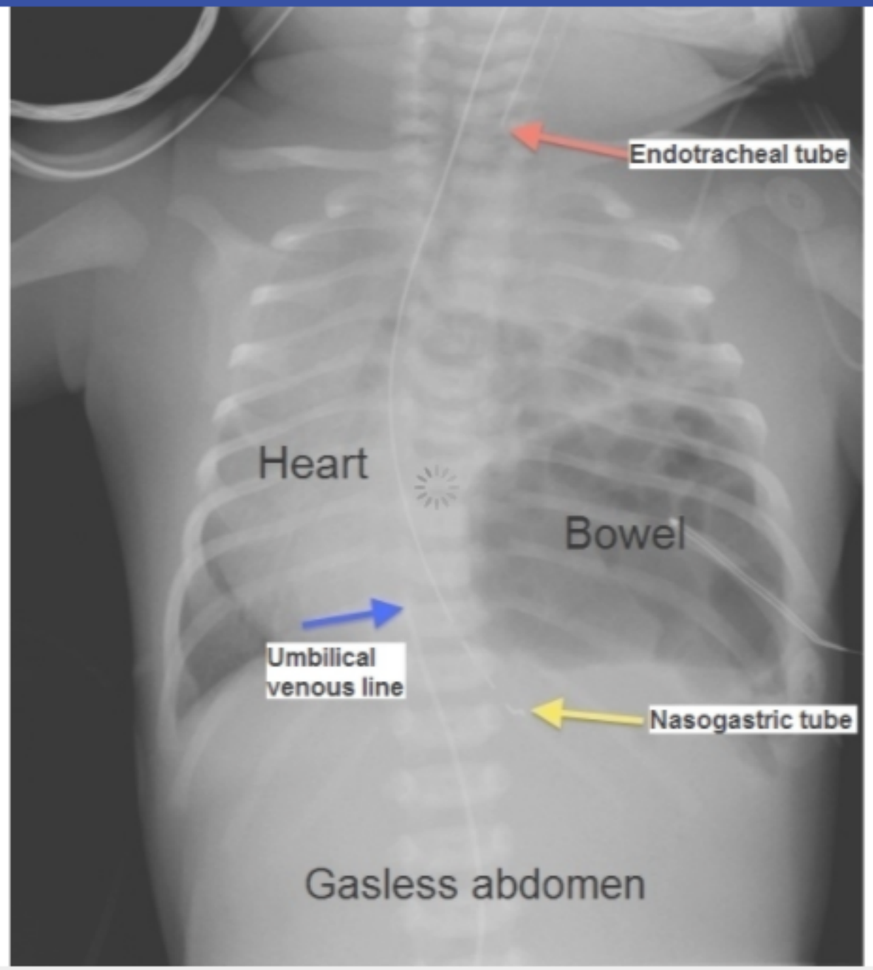

Zoom In | Zoom Out | Reset | Add To New Card | Existing Card

Block Time Remaining: 00:01:05
TUTOR

4 | Feedback | Suspend | End Block

Settings

1 2 3 4 5 6 7 8 9 10 11 12 13 14 15 16 17 18 19 20 21 22 23 24 25 26 27 28 29 30

Item 25 of 40
Question Id: 1752

Mark | Previous | Next | Full Screen | Tutorial | Lab Values | Notes | Calculator | Reverse Color | Text Zoom | Settings

© USMLEWorld, LLC

Exhibit Display

Esophageal atresia & tracheoesophageal fistula

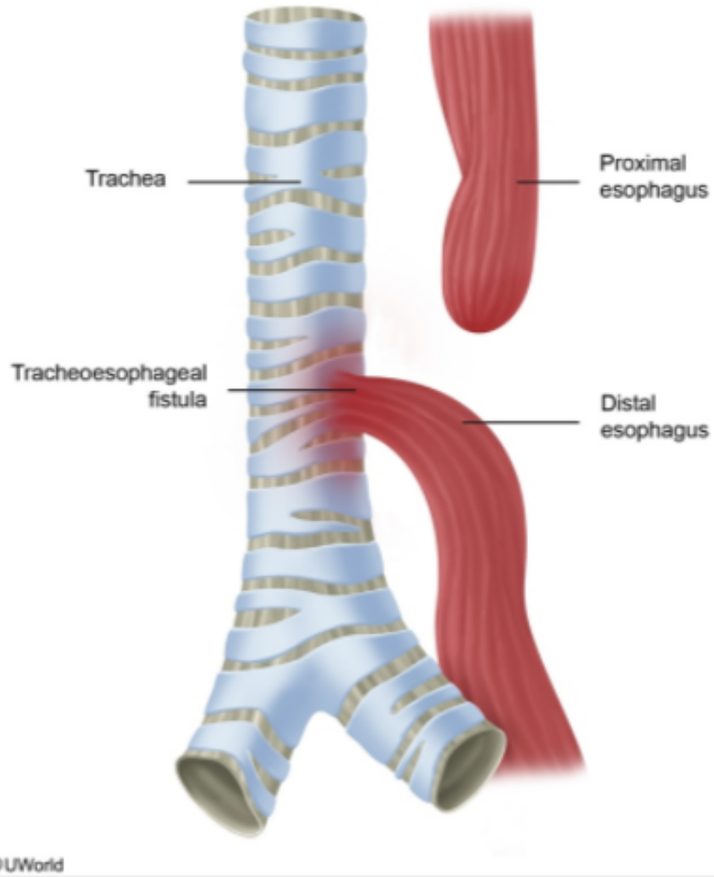

Zoom In | Zoom Out | Reset | Add To New Card | Existing Card

Block Time Remaining: 00:01:05
TUTOR

4 | Feedback | Suspend | End Block

Settings

1 2 3 4 5 6 7 8 9 10 11 12 13 14 15 16 17 18 19 20 21 22 23 24 25 26 27 28 29 30

Item 25 of 40
Question Id: 1752

Mark | Previous | Next | Full Screen | Tutorial | Lab Values | Notes | Calculator | Reverse Color | Text Zoom | Settings

© USMLEWorld, LLC

Exhibit Display

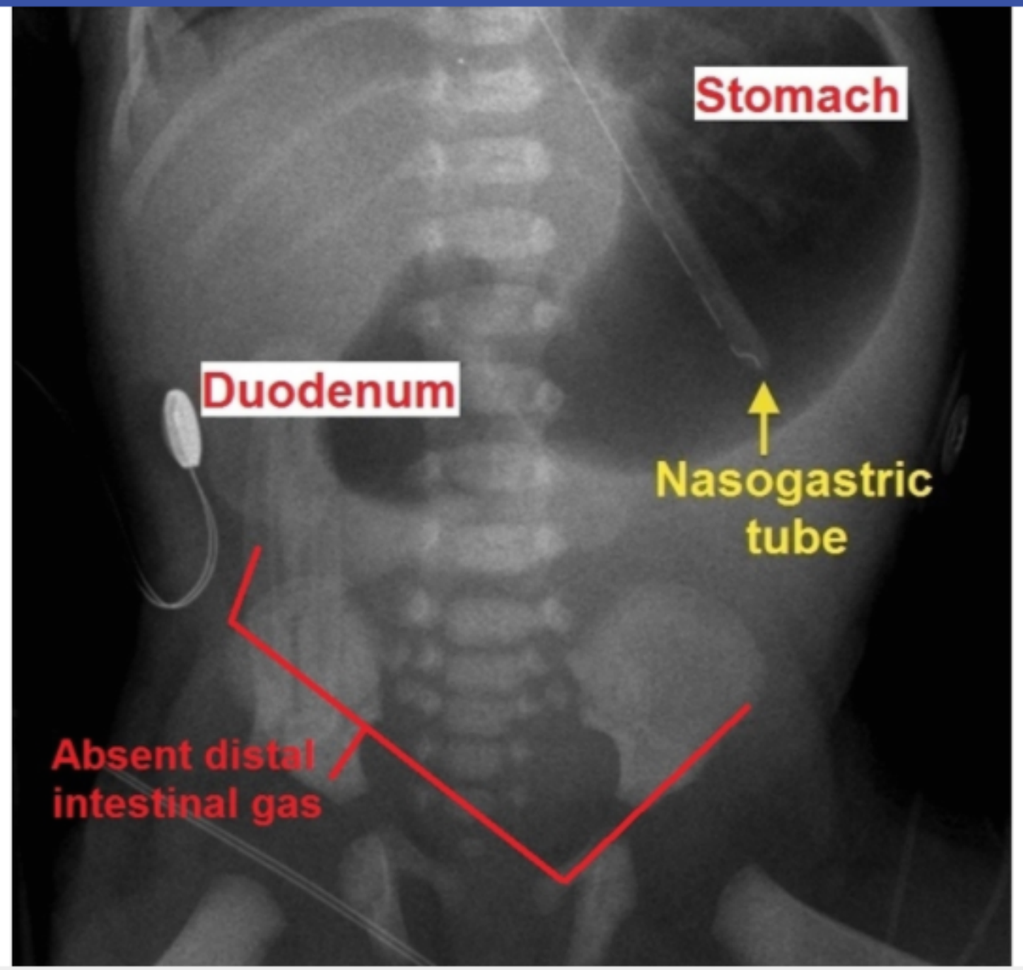

Zoom In | Zoom Out | Reset | Add To New Card | Existing Card

Block Time Remaining: 00:01:05
TUTOR

4 | Feedback | Suspend | End Block

1 2 3 4 5 6 7 8 9 10 11 12 13 14 15 16 17 18 19 20 21 22 23 24 25 26 27 28 29 30

A 32-year-old woman at 28 weeks gestation has an ultrasound that shows markedly elevated amniotic fluid levels. She has been feeling short of breath when she is supine but has no other symptoms. The patient has a history of epilepsy that is well-controlled with medication. She lives with her husband who is healthy. The patient does not use tobacco, alcohol, or illicit drugs. Her immunizations are up to date, and she has no allergies. Physical examination shows an abdominal circumference that is larger than expected for gestational age. Which of the following fetal anomalies would most likely account for this patient's polyhydramnios?

A. Anencephaly

B. Atrial septal defect

C. Posterior urethral valves

D. Pulmonary hypoplasia

E. Renal agenesis

F. Spina bifida occulta

Submit

1 2 3 4 5 6 7 8 9 10 11 12 13 14 15 16 17 18 19 20 21 22 23 24 25 26 27 28 29 30

A 32-year-old woman at 28 weeks gestation has an ultrasound that shows markedly elevated amniotic fluid levels. She has been feeling short of breath when she is supine but has no other symptoms. The patient has a history of epilepsy that is well-controlled with medication. She lives with her husband who is healthy. The patient does not use tobacco, alcohol, or illicit drugs. Her immunizations are up to date, and she has no allergies. Physical examination shows an abdominal circumference that is larger than expected for gestational age. Which of the following fetal anomalies would most likely account for this patient's polyhydramnios?

- ✓ A. Anencephaly (62%)
- B. Atrial septal defect (1%)
- C. Posterior urethral valves (4%)
- D. Pulmonary hypoplasia (10%)
- E. Renal agenesis (14%)
- F. Spina bifida occulta (6%)

Omitted
Correct answer
A

62%
Answered correctly

02 secs
Time Spent

06/28/2020
Last Updated

Explanation

Polyhydramnios

Fetal gastrointestinal

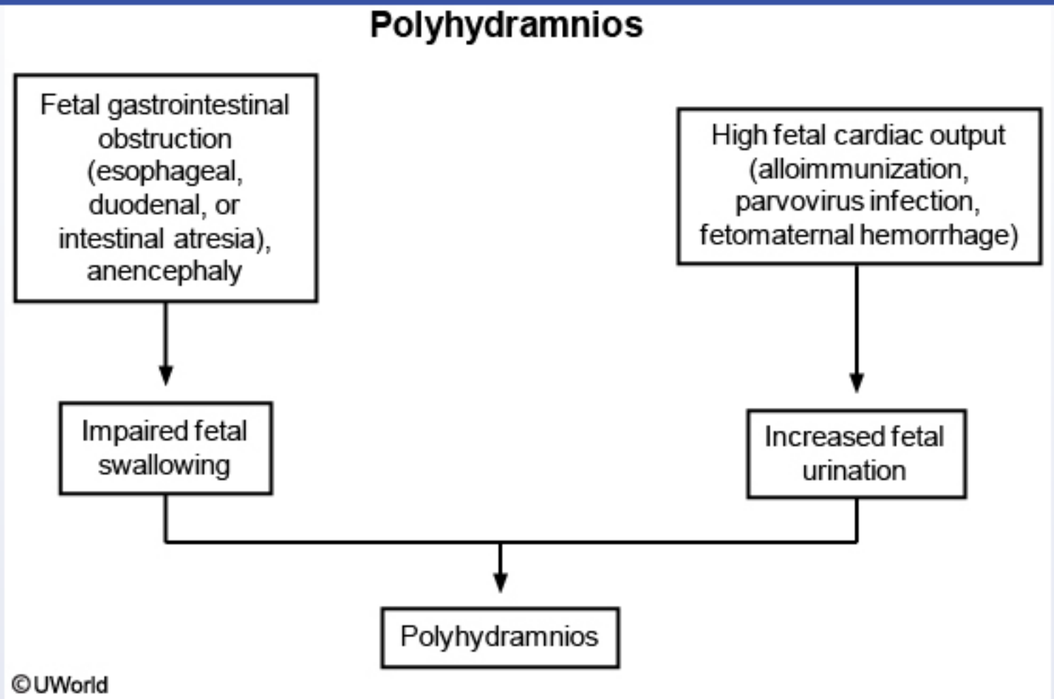

Polyhydramnios is the excessive accumulation of amniotic fluid. Moderate-to-severe polyhydramnios causes uterine enlargement (eg, increased abdominal circumference) out of proportion to gestational age. Potential complications include preterm labor, placental abruption, and uterine atony due to uterine overdistention. Polyhydramnios also increases the risk of maternal respiratory compromise as the abdominal cavity impairs lung expansion.

Polyhydramnios can be due to decreased fetal swallowing or increased fetal urination. Fetal anomalies associated with **impaired swallowing** include **gastrointestinal obstruction** (eg, duodenal, esophageal, or intestinal atresia) and **anencephaly** (a defect of the cranial neural tube). Causes of **increased fetal urination** include high cardiac output due to anemia or twin-to-twin transfusion syndrome. **Maternal diabetes** and **multiple gestations** tend to cause milder polyhydramnios compared to the aforementioned major fetal anomalies.

This patient's prenatal use of anti-epileptic therapy (eg, valproate, carbamazepine, phenytoin) is a substantial risk factor for fetal neural tube defects such as anencephaly. Like anencephaly, spina bifida **(Choice E)** is a group of neural tube defects (eg, occulta, meningocele

Polyhydramnios is the excessive accumulation of amniotic fluid. Moderate-to-severe polyhydramnios causes uterine enlargement (eg, increased abdominal circumference) out of proportion to gestational age. Potential complications include preterm labor, placental abruption, and uterine atony due to uterine overdistention. Polyhydramnios also increases the risk of maternal respiratory compromise as the abdominal cavity impairs lung expansion.

Polyhydramnios can be due to decreased fetal swallowing or increased fetal urination. Fetal anomalies associated with **impaired swallowing** include **gastrointestinal obstruction** (eg, duodenal, esophageal, or intestinal atresia) and **anencephaly** (a defect of the cranial neural tube). Causes of **increased fetal urination** include high cardiac output due to anemia or twin-to-twin transfusion syndrome. **Maternal diabetes** and **multiple gestations** tend to cause milder polyhydramnios compared to the aforementioned major fetal anomalies.

This patient's prenatal use of anti-epileptic therapy (eg, valproate, carbamazepine, phenytoin) is a substantial risk factor for fetal neural tube defects such as anencephaly. Like anencephaly, spina bifida **(Choice F)** is a group of neural tube defects (eg, occulta, meningocele, myelomeningocele) that can result from maternal folic acid deficiency and use of folic acid antagonists (anti-epileptic drugs, trimethoprim). However, spina bifida occulta, the mildest form, is not associated with polyhydramnios as fetal swallowing of amniotic fluid should be normal.

(Choice B) Atrial septal defects (ASDs) are one of the most common congenital heart diseases. ASDs are usually asymptomatic in utero. The diagnosis is usually made after birth based on wide fixed splitting of S2 on physical examination. ASDs are not associated with polyhydramnios.

(Choices C, D, and E) Renal agenesis is associated with severe oligohydramnios (too little amniotic fluid) after 16 weeks of gestation when the majority of the amniotic fluid is fetal urine. Posterior urethral valves in male fetuses can also result in decreased fetal urine output and oligohydramnios. Oligohydramnios, in turn, can lead to fetal compression by the uterus and Potter sequence. Pulmonary hypoplasia is a consequence of oligohydramnios and is not associated with polyhydramnios.

Educational objective:
Polyhydramnios (excessive accumulation of amniotic fluid) presents with increased abdominal circumference out of proportion to gestational age. The etiology is decreased fetal swallowing or increased fetal urination. Fetal anomalies associated with impaired swallowing include gastrointestinal obstruction (eg, duodenal, esophageal, or intestinal atresia) and anencephaly.

References

- Polyhydramnios: a warning sign in the prenatal ultrasound diagnosis of foetal malformation?

Causes of **increased fetal urination** include high cardiac output due to anemia or twin-to-twin transfusion syndrome. **Maternal diabetes** and **multiple gestations** tend to cause milder polyhydramnios compared to the aforementioned major fetal anomalies.

This patient's prenatal use of anti-epileptic therapy (eg, valproate, carbamazepine, phenytoin) is a substantial risk factor for fetal neural tube defects such as anencephaly. Like anencephaly, spina bifida **(Choice F)** is a group of neural tube defects (eg, occulta, meningocele, myelomeningocele) that can result from maternal folic acid deficiency and use of folic acid antagonists (anti-epileptic drugs, trimethoprim). However, spina bifida occulta, the mildest form, is not associated with polyhydramnios as fetal swallowing of amniotic fluid should be normal.

(Choice B) Atrial septal defects (ASDs) are one of the most common congenital heart diseases. ASDs are usually asymptomatic in utero. The diagnosis is usually made after birth based on wide fixed splitting of S2 on physical examination. ASDs are not associated with polyhydramnios.

(Choices C, D, and E) Renal agenesis is associated with severe oligohydramnios (too little amniotic fluid) after 16 weeks of gestation when the majority of the amniotic fluid is fetal urine. Posterior urethral valves in male fetuses can also result in decreased fetal urine output and oligohydramnios. Oligohydramnios, in turn, can lead to fetal compression by the uterus and Potter sequence. Pulmonary hypoplasia is a consequence of oligohydramnios and is not associated with polyhydramnios.

Educational objective:
Polyhydramnios (excessive accumulation of amniotic fluid) presents with increased abdominal circumference out of proportion to gestational age. The etiology is decreased fetal swallowing or increased fetal urination. Fetal anomalies associated with impaired swallowing include gastrointestinal obstruction (eg, duodenal, esophageal, or intestinal atresia) and anencephaly.

References

- Polyhydramnios: a warning sign in the prenatal ultrasound diagnosis of foetal malformation?
- Intrauterine exposure to carbamazepine and specific congenital malformations: systematic review and case-control study.

Embryology	Pregnancy, Childbirth & Puerperium	Polyhydramnios
Subject	System	Topic

Copyright © UWorld. All rights reserved.

Causes of **increased fetal urination** include high cardiac output due to anemia or twin-to-twin transfusion syndrome. **Maternal diabetes** and

Exhibit Display

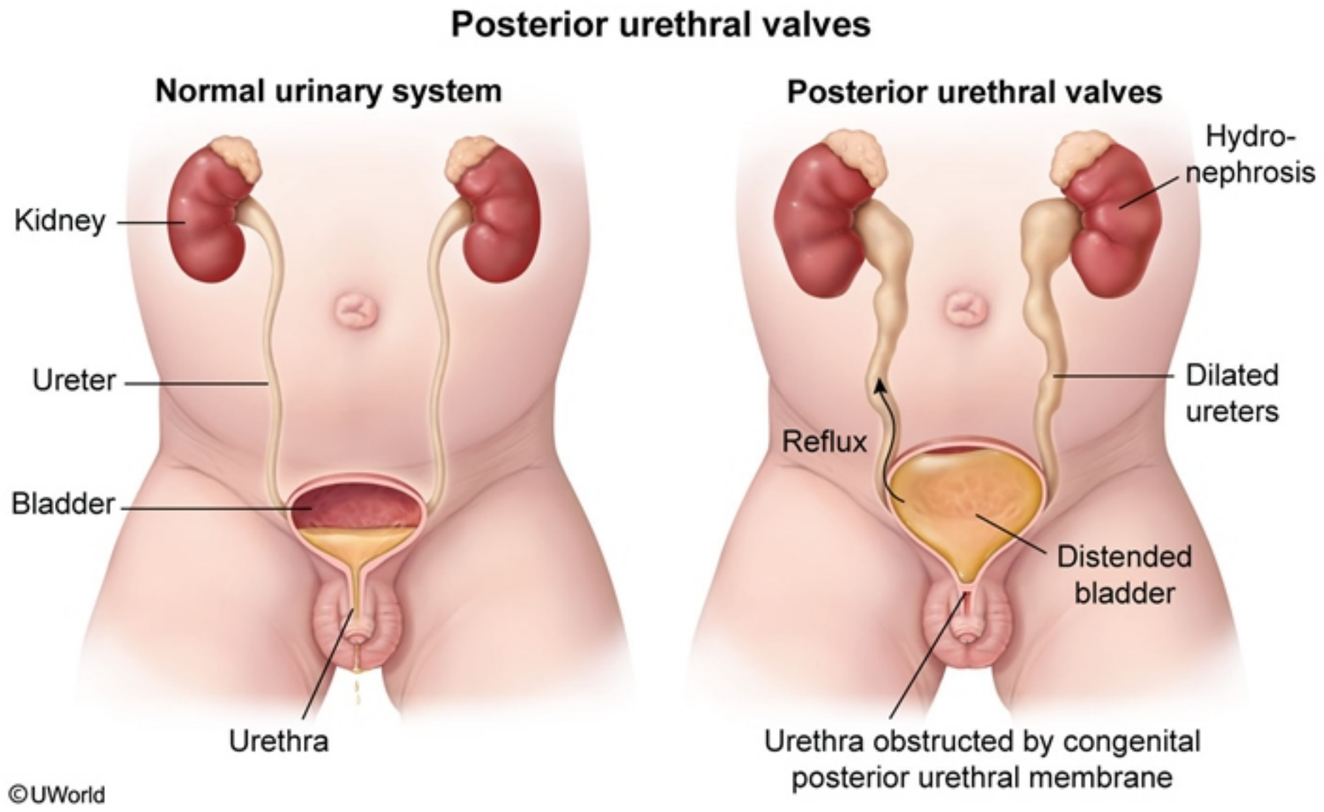

Zoom In | Zoom Out | Reset | Add To New Card | Existing Card

Causes of **increased fetal urination** include high cardiac output due to anemia or twin-to-twin transfusion syndrome. **Maternal diabetes** and

Exhibit Display

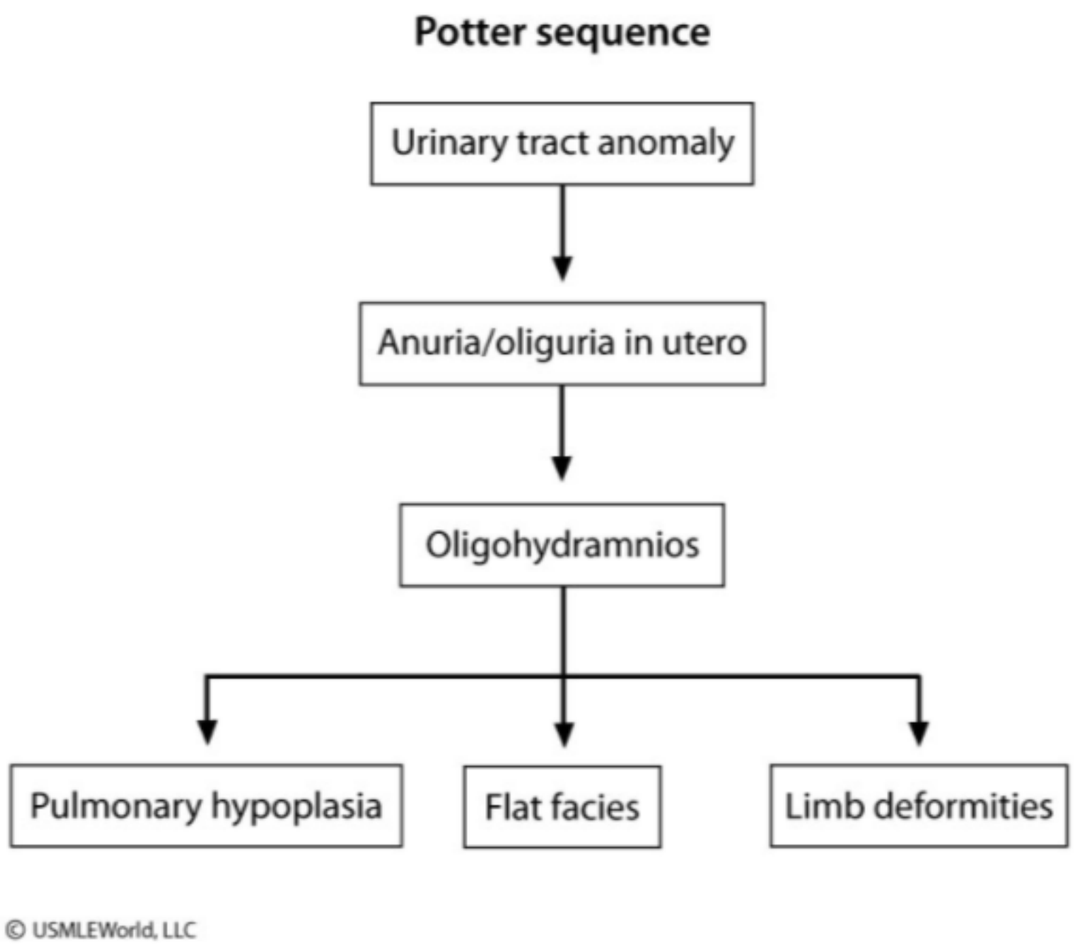

Zoom In | Zoom Out | Reset | Add To New Card | Existing Card

A previously healthy 4-year-old girl is brought to the office because her parents noticed dark red blood on her toilet tissue. She has no abdominal pain or discomfort with stooling. Her temperature is 36.7 C (98 F), blood pressure is 100/40 mm Hg, and pulse is 112/min. Physical examination shows a soft and nontender abdomen, and bowel sounds are present. Her hemoglobin is 8 g/dL and platelet count is 215,000/mm^3. Coagulation profile is normal. Sequential imaging using ^{99m}Tc-pertechnetate scintigraphy demonstrates focal radiotracer accumulation in the right lower quadrant. Which of the following embryologic processes most likely failed in this patient?

A. Ascent of the kidneys into the abdomen

B. Closure of lateral body folds at the umbilicus

C. Hindgut descent along the inferior mesenteric artery

D. Midgut rotation around the superior mesenteric artery

E. Neural crest cell migration into the bowel wall

F. Obliteration of the omphalomesenteric (vitelline) duct

Submit

A previously healthy 4-year-old girl is brought to the office because her parents noticed dark red blood on her toilet tissue. She has no abdominal pain or discomfort with stooling. Her temperature is 36.7 C (98 F), blood pressure is 100/40 mm Hg, and pulse is 112/min. Physical examination shows a soft and nontender abdomen, and bowel sounds are present. Her hemoglobin is 8 g/dL and platelet count is 215,000/mm^3. Coagulation profile is normal. Sequential imaging using ^{99m}Tc-pertechnetate scintigraphy demonstrates focal radiotracer accumulation in the right lower quadrant. Which of the following embryologic processes most likely failed in this patient?

- A. Ascent of the kidneys into the abdomen (4%)
- B. Closure of lateral body folds at the umbilicus (1%)
- C. Hindgut descent along the inferior mesenteric artery (6%)
- D. Midgut rotation around the superior mesenteric artery (13%)
- E. Neural crest cell migration into the bowel wall (6%)
- ✓ F. Obliteration of the omphalomesenteric (vitelline) duct (66%)

Omitted
Correct answer
F

66%
Answered correctly

02 secs
Time Spent

03/12/2020
Last Updated

Explanation

Vitelline duct abnormalities

Settings

1 2 3 4 5 6 7 8 9 10 11 12 13 14 15 16 17 18 19 20 21 22 23 24 25 26 27 28 29 30

Item 27 of 40
Question Id: 329

Mark | Previous | Next | Full Screen | Tutorial | Lab Values | Notes | Calculator | Reverse Color | Text Zoom | Settings

Vitelline duct abnormalities

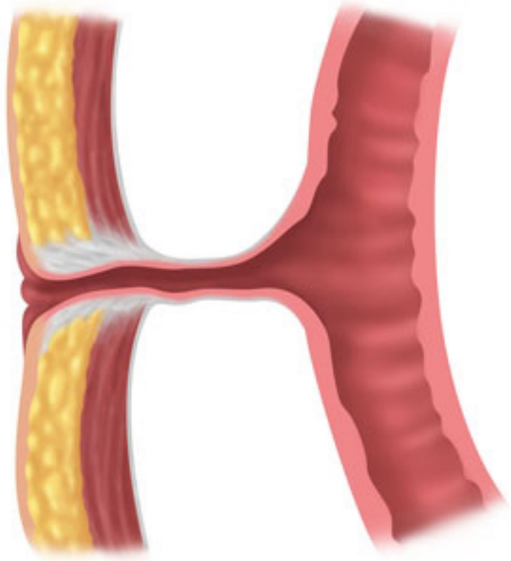

Persistent vitelline duct

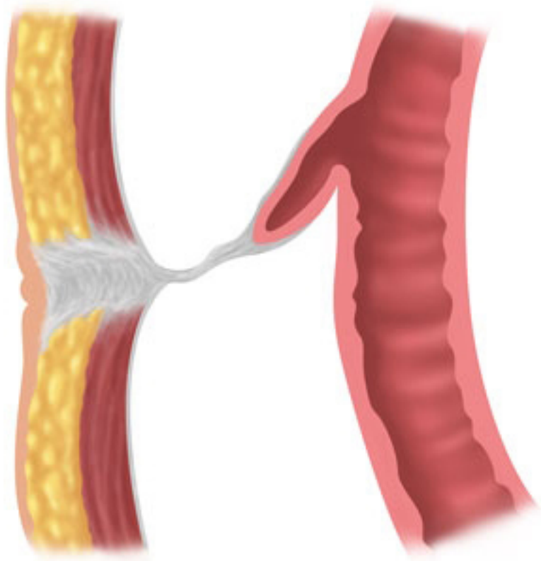

Meckel diverticulum

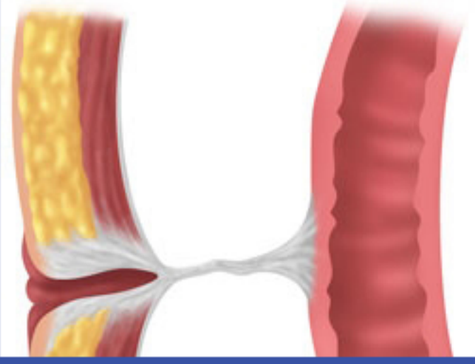

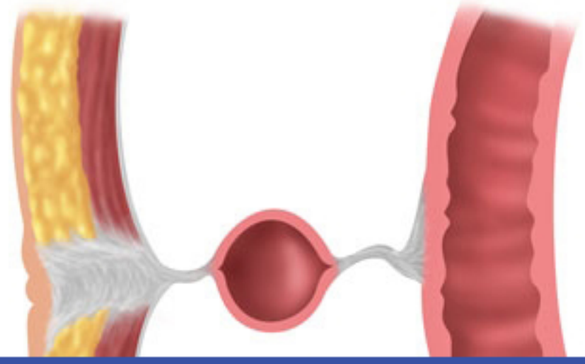

Block Time Remaining: 00:01:09
TUTOR

5 | Feedback | Suspend | End Block

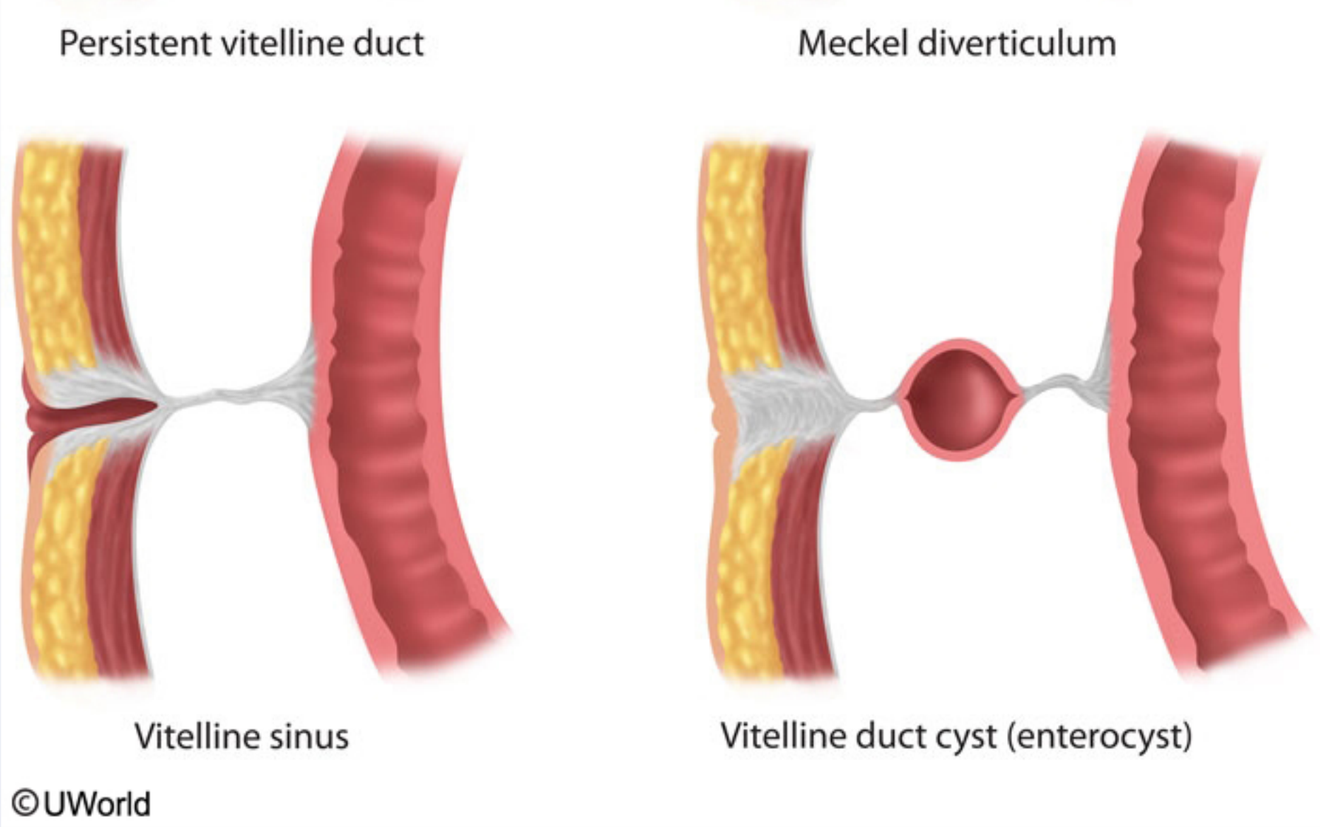

Meckel diverticulum is an ileal outgrowth that results from failed obliteration of the vitelline (omphalomesenteric) duct. When patients are symptomatic, the most common manifestation of Meckel diverticulum is spontaneous but **painless** lower gastrointestinal (GI) **bleeding**. Meckel diverticulum is also a potential lead point for intussusception, which can present with colicky abdominal pain and "**currant jelly**" (strawberry jam appearance) stools.

Ectopic gastric mucosa in the Meckel diverticulum secretes acid and causes local ulceration and bleeding. The radioisotope ^{99m}Tc-pertechnetate has an affinity for **parietal cells** of the gastric mucosa (including ectopic sites) and is used in a nuclear medicine procedure called the ^{99m}Tc-pertechnetate scan. Increased uptake of ^{99m}Tc-pertechnetate in the periumbilical/right lower quadrant (RLQ) is characteristic of Meckel

Meckel diverticulum is an ileal outgrowth that results from failed obliteration of the vitelline (omphalomesenteric) duct. When patients are symptomatic, the most common manifestation of Meckel diverticulum is spontaneous but **painless** lower gastrointestinal (GI) **bleeding**. Meckel diverticulum is also a potential lead point for intussusception, which can present with colicky abdominal pain and "**currant jelly**" (strawberry jam appearance) stools.

Ectopic gastric mucosa in the Meckel diverticulum secretes acid and causes local ulceration and bleeding. The radioisotope ^{99m}Tc-pertechnetate has an affinity for **parietal cells** of the gastric mucosa (including ectopic sites) and is used in a nuclear medicine procedure called the ^{99m}Tc-pertechnetate scan. Increased uptake of ^{99m}Tc-pertechnetate in the periumbilical/right lower quadrant (RLQ) is characteristic of Meckel diverticulum.

(Choice A) If the lower poles of the kidney fuse, a horseshoe kidney forms and is unable to ascend past the inferior mesenteric artery from the pelvis to the abdomen. Some patients may have hematuria but most are asymptomatic.

(Choice B) The midgut normally herniates into the yolk sac during the 6th week of gestation and returns to the abdominal cavity in the 10th week. If lateral body folds do not develop and close, abdominal contents herniate through the ventral wall defect. Omphalocele and gastroschisis do not commonly present with GI bleeding.

(Choice C) The hindgut gives rise to the distal third of the transverse colon, descending and sigmoid colon, rectum, and upper part of the anal canal. Failure of proper descent during development can lead to imperforate anus, which does not bleed.

(Choice D) Abnormal midgut rotation around the superior mesenteric artery leads to intestinal malrotation. The intestine is fixed by fibrous adhesive bands and can cause obstruction and painful bilious emesis in the newborn.

(Choice E) Neural crest cells migrate in a craniocaudal direction to the internal anal sphincter. If this process fails, then the myenteric plexus does not form, and the aganglionic sigmoid colon/rectum segments become inactive and narrow. Hirschsprung disease manifests as intestinal obstruction in the neonate and presents with delayed passage of meconium, bilious vomiting, and abdominal distension.

Educational objective:
Meckel diverticulum results from failed obliteration of the vitelline (omphalomesenteric) duct and usually presents with spontaneous but painless lower gastrointestinal bleeding. ^{99m}Tc-pertechnetate localizes ectopic gastric mucosa, and its increased uptake is diagnostic for Meckel diverticulum.

1 2 3 4 5 6 7 8 9 10 11 12 13 14 15 16 17 18 19 20 21 22 23 24 25 26 27 28 29 30

Exhibit Display

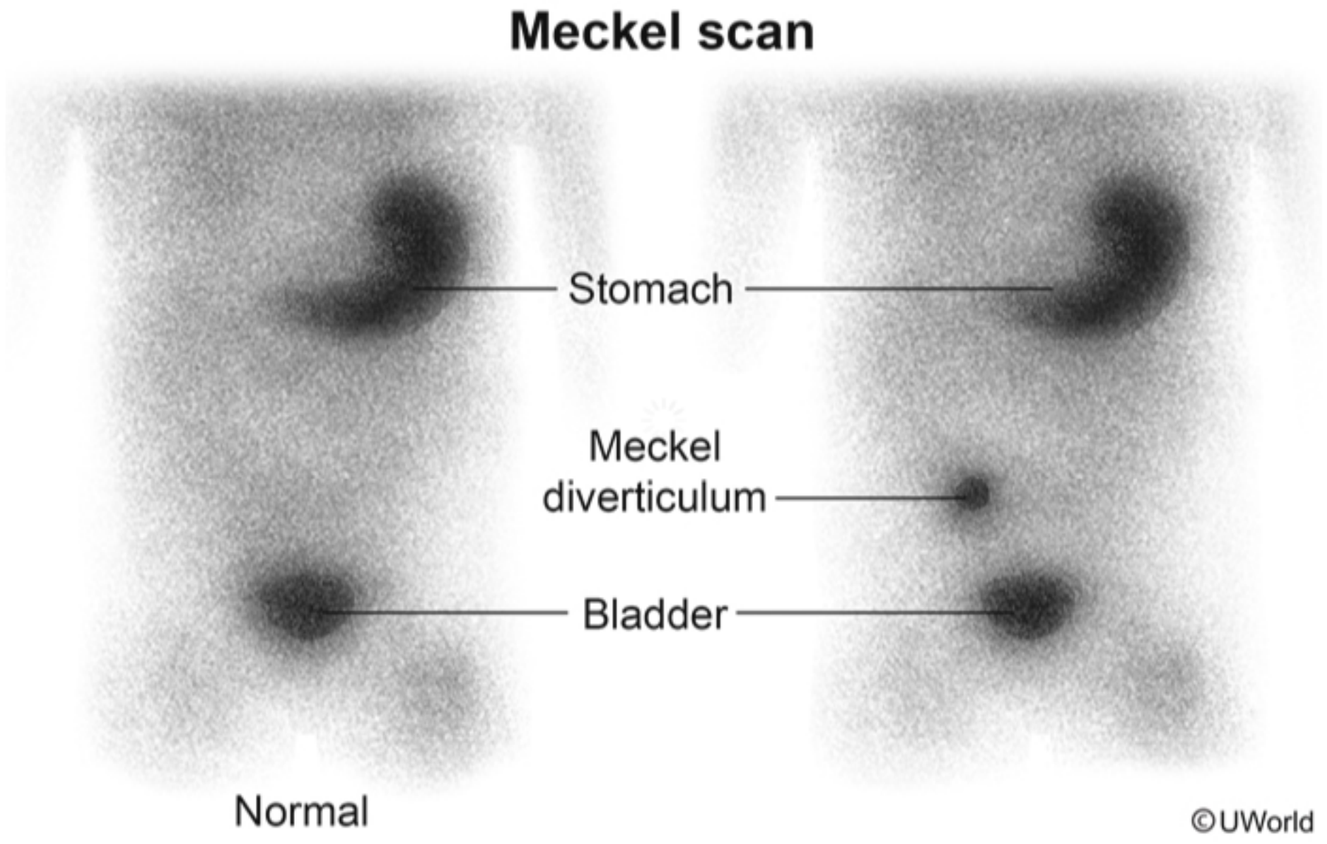

Zoom In | Zoom Out | Reset | Add To New Card | Existing Card

Exhibit Display

Gastroschisis vs. omphalocele

Gastroschisis
Eviscerated bowel with no covering membrane

Omphalocele
Sac containing multiple organs

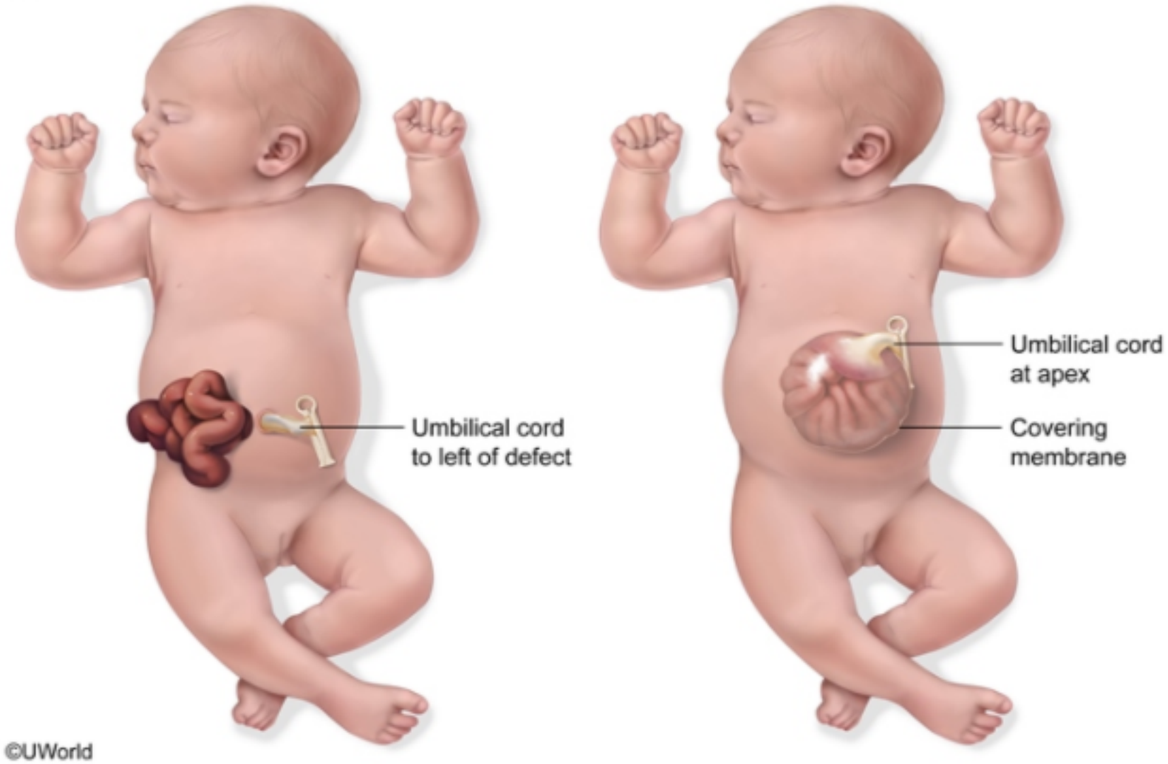

Zoom In | Zoom Out | Reset | Add To New Card | Existing Card

Exhibit Display

Hirschsprung disease

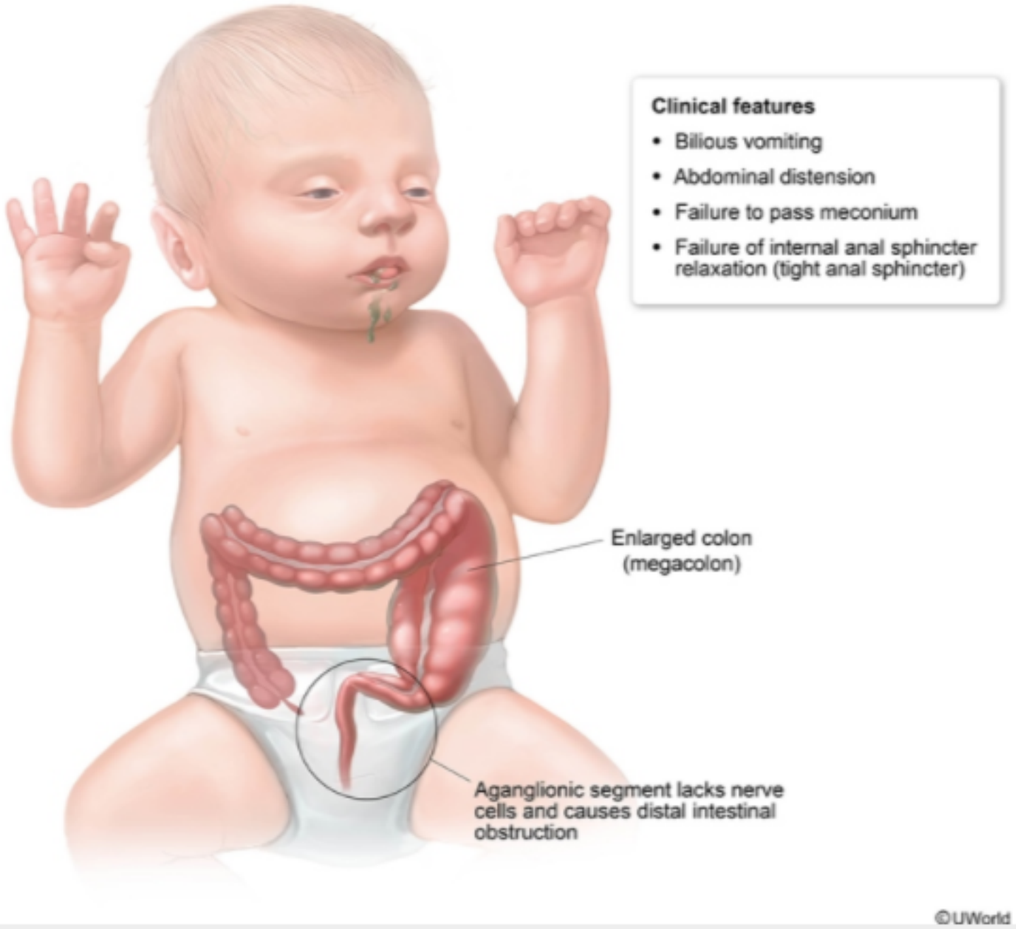

Zoom In | Zoom Out | Reset | Add To New Card | Existing Card

Laparotomy performed in a 4-year-old Caucasian girl with abdominal pain reveals a blind pouch connected to the ileum. The pouch is removed; under microscopy, it demonstrates pancreatic acini in the mucosa. The latter finding would be best described as which of the following?

A. Hypoplasia

B. Hyperplasia

C. Metaplasia

D. Dysplasia

E. Ectopy

Submit

Laparotomy performed in a 4-year-old Caucasian girl with abdominal pain reveals a blind pouch connected to the ileum. The pouch is removed; under microscopy, it demonstrates pancreatic acini in the mucosa. The latter finding would be best described as which of the following?

A. Hypoplasia (1%)

B. Hyperplasia (1%)

C. Metaplasia (13%)

D. Dysplasia (3%)

✓ E. Ectopy (79%)

Omitted
Correct answer
E

79%
Answered correctly

02 secs
Time Spent

02/03/2020
Last Updated

Explanation

Meckel diverticulum is the most common congenital anomaly of the small intestine, being present in 2% of the population. It forms due to incomplete obliteration of the omphalomesenteric duct that connects the midgut lumen and yolk sac cavity early in fetal life. Meckel diverticulum is connected to the ileum, and is located approximately 2 feet proximal to the ileocecal valve.

A variety of tissues have been found in Meckel diverticulum, including gastric, pancreatic, colonic, jejunal, duodenal and endometrial. The most common of these is gastric tissue, which is significant because gastric epithelium produces acid that can cause ulceration of adjacent tissues and lower GI bleeding. Meckel diverticulum most often presents with painless melena. The diverticulum may also become inflamed and simulate the

Meckel diverticulum is the most common congenital anomaly of the small intestine, being present in 2% of the population. It forms due to incomplete obliteration of the omphalomesenteric duct that connects the midgut lumen and yolk sac cavity early in fetal life. Meckel diverticulum is connected to the ileum, and is located approximately 2 feet proximal to the ileocecal valve.

A variety of tissues have been found in Meckel diverticulum, including gastric, pancreatic, colonic, jejunal, duodenal and endometrial. The most common of these is gastric tissue, which is significant because gastric epithelium produces acid that can cause ulceration of adjacent tissues and lower GI bleeding. Meckel diverticulum most often presents with painless melena. The diverticulum may also become inflamed and simulate the clinical presentation of acute appendicitis.

Gastric, pancreatic, and other types of mucosa found in Meckel diverticulum are examples of ectopy (also called heterotopy). "Ectopy" is a term that identifies microscopically and functionally normal cells/tissues found in an abnormal location due to embryonic maldevelopment.

(Choice A) Hypoplasia is an embryologically-associated decrease in the number of cells resulting in decreased volume or size of the organ or tissue. Renal hypoplasia is an example of this abnormality.

(Choice B) Hyperplasia is a compensatory increase in the number of cells with a subsequent increase in the size of an organ. Endometrial hyperplasia due to estrogen hypersecretion is an example of this process.

(Choice C) Replacement of one type of epithelium with another type not typical for location is called metaplasia. Unlike ectopia, which is the result of congenital malformation, metaplasia occurs during adult life and is initially a compensatory process. Metaplasia increases cancer risk in varying degrees.

(Choice D) Dysplasia includes a number of changes, such as pleomorphism, increased size of the nucleus, loss of cellular orientation, and loss of characteristics of the original tissue. Dysplasia is a sign of malignant transformation.

Educational Objective:
A number of ectopic tissues are found in Meckel diverticulum−most commonly, gastric epithelium. Gastric mucosa is present in 80% of cases of symptomatic Meckel diverticulum. Gastric acid production leads to ulceration and subsequent bleeding.

connected to the ileum, and is located approximately 2 feet proximal to the ileocecal valve.

A variety of tissues have been found in Meckel diverticulum, including gastric, pancreatic, colonic, jejunal, duodenal and endometrial. The most common of these is gastric tissue, which is significant because gastric epithelium produces acid that can cause ulceration of adjacent tissues and lower GI bleeding. Meckel diverticulum most often presents with painless melena. The diverticulum may also become inflamed and simulate the clinical presentation of acute appendicitis.

Gastric, pancreatic, and other types of mucosa found in Meckel diverticulum are examples of ectopy (also called heterotopy). "Ectopy" is a term that identifies microscopically and functionally normal cells/tissues found in an abnormal location due to embryonic maldevelopment.

(Choice A) Hypoplasia is an embryologically-associated decrease in the number of cells resulting in decreased volume or size of the organ or tissue. Renal hypoplasia is an example of this abnormality.

(Choice B) Hyperplasia is a compensatory increase in the number of cells with a subsequent increase in the size of an organ. Endometrial hyperplasia due to estrogen hypersecretion is an example of this process.

(Choice C) Replacement of one type of epithelium with another type not typical for location is called metaplasia. Unlike ectopia, which is the result of congenital malformation, metaplasia occurs during adult life and is initially a compensatory process. Metaplasia increases cancer risk in varying degrees.

(Choice D) Dysplasia includes a number of changes, such as pleomorphism, increased size of the nucleus, loss of cellular orientation, and loss of characteristics of the original tissue. Dysplasia is a sign of malignant transformation.

Educational Objective:
A number of ectopic tissues are found in Meckel diverticulum−most commonly, gastric epithelium. Gastric mucosa is present in 80% of cases of symptomatic Meckel diverticulum. Gastric acid production leads to ulceration and subsequent bleeding.

Embryology	Gastrointestinal & Nutrition	Meckel diverticulum
Subject	System	Topic

Copyright © UWorld. All rights reserved.

1 2 3 4 5 6 7 8 9 10 11 12 13 14 15 16 17 18 19 20 21 22 23 24 25 26 27 28 29 30

A 6-hour-old boy is in the newborn nursery with feeding difficulties. The patient was born at 39 weeks gestation to a 33-year-old primigravida via cesarean delivery due to failure to progress and late decelerations seen on fetal heart tracing. Apgar scores were 8 and 9, but examination shows an infant with excessive drooling and coughing. Cardiac, respiratory, and abdominal examinations are otherwise normal at rest. When the infant attempts to breastfeed, however, several bouts of coughing and perioral cyanosis develop with oxygen saturation of 85% on room air. Which of the following is the most likely cause of this patient's condition?

A. Atresia of small intestine

B. Collapse of supraglottic structures during respiration

C. Failure of primitive foregut to separate from airway

D. Obstruction of posterior nasal passages

E. Thoracic herniation of abdominal viscera

Submit

1 2 3 4 5 6 7 8 9 10 11 12 13 14 15 16 17 18 19 20 21 22 23 24 25 26 27 28 29 30

A 6-hour-old boy is in the newborn nursery with feeding difficulties. The patient was born at 39 weeks gestation to a 33-year-old primigravida via cesarean delivery due to failure to progress and late decelerations seen on fetal heart tracing. Apgar scores were 8 and 9, but examination shows an infant with excessive drooling and coughing. Cardiac, respiratory, and abdominal examinations are otherwise normal at rest. When the infant attempts to breastfeed, however, several bouts of coughing and perioral cyanosis develop with oxygen saturation of 85% on room air. Which of the following is the most likely cause of this patient's condition?

- A. Atresia of small intestine (2%)
- B. Collapse of supraglottic structures during respiration (5%)
- ✓ C. Failure of primitive foregut to separate from airway (83%)
- D. Obstruction of posterior nasal passages (6%)
- E. Thoracic herniation of abdominal viscera (1%)

Omitted
Correct answer
C

83%
Answered correctly

02 secs
Time Spent

01/08/2020
Last Updated

Explanation

Esophageal atresia & tracheoesophageal fistula

Esophageal atresia & tracheoesophageal fistula

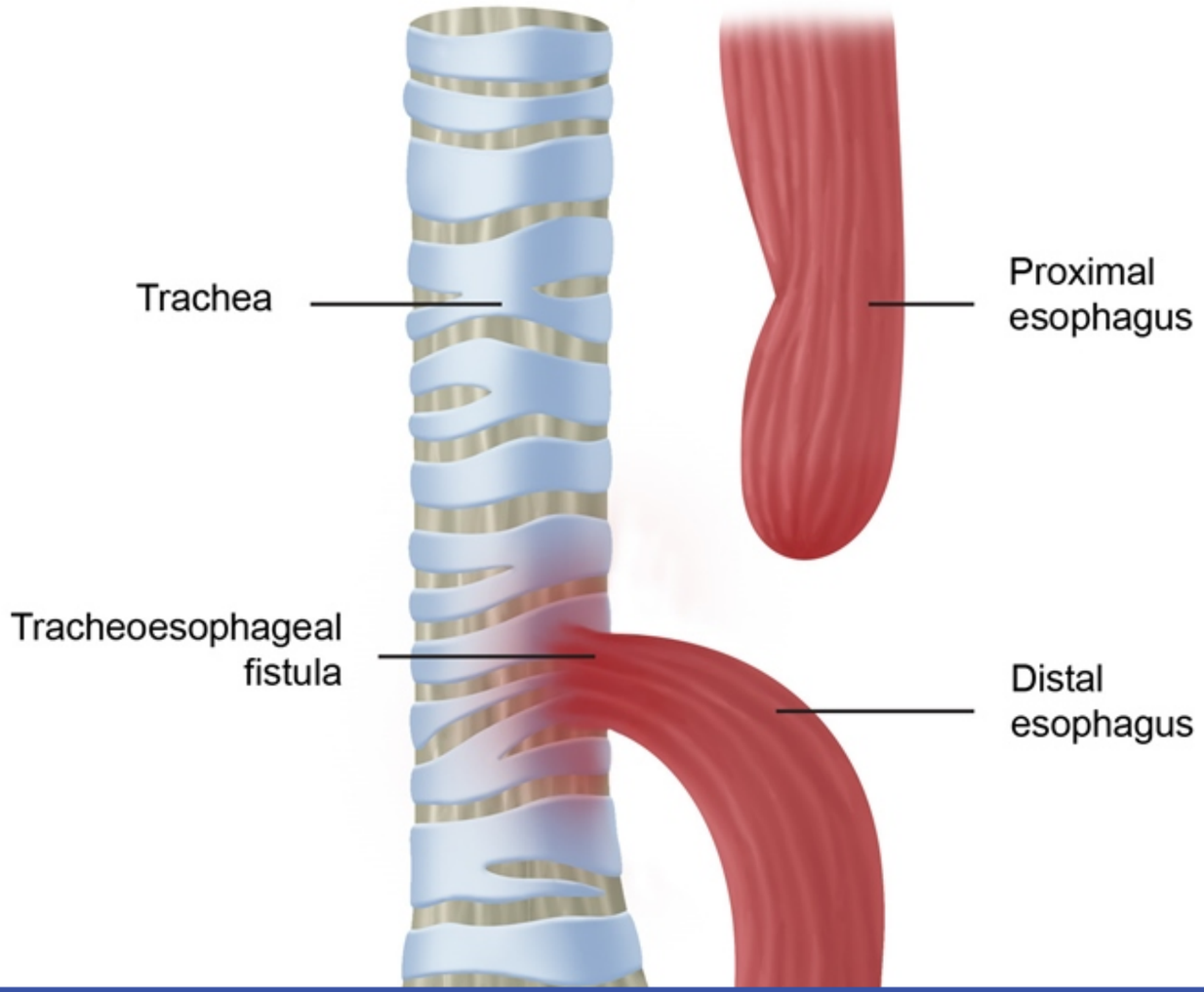

1 2 3 4 5 6 7 8 9 10 11 12 13 14 15 16 17 18 19 20 21 22 23 24 25 26 27 28 29 30

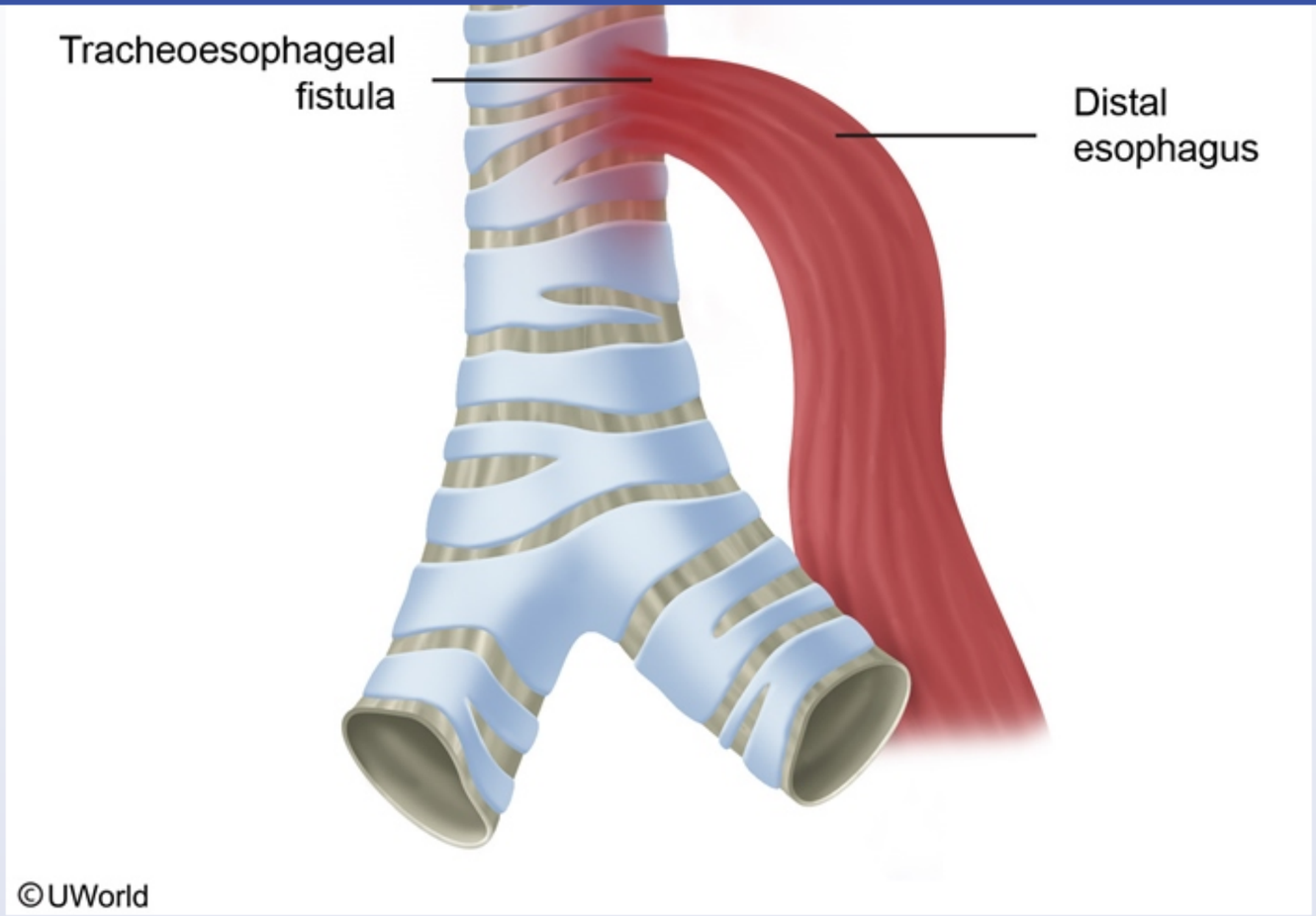

This infant's presentation is concerning for **tracheoesophageal fistula with esophageal atresia (TEF/EA)**. Normally, the trachea develops from a diverticulum that forms from the **primitive foregut**. The tracheobronchial diverticulum lengthens and separates to form the respiratory tract, while the foregut becomes the esophagus. Failure to separate most commonly leads to esophageal atresia with a remaining fistula between the trachea and esophagus.

Prenatal ultrasounds may demonstrate **polyhydramnios** due to the inability of the fetus to swallow amniotic fluid. After birth, infants typically

This infant's presentation is concerning for **tracheoesophageal fistula with esophageal atresia (TEF/EA)**. Normally, the trachea develops from a diverticulum that forms from the **primitive foregut**. The tracheobronchial diverticulum lengthens and separates to form the respiratory tract, while the foregut becomes the esophagus. Failure to separate most commonly leads to esophageal atresia with a remaining fistula between the trachea and esophagus.

Prenatal ultrasounds may demonstrate **polyhydramnios** due to the inability of the fetus to swallow amniotic fluid. After birth, infants typically present with significant **drooling** (due to inability to swallow saliva) and choking, **coughing**, and **cyanosis with feeds** (due to reflux of breastmilk/formula and aspiration into the trachea/lungs). The diagnosis of TEF/EA is confirmed by x-ray showing positioning of the nasogastric tube in the atretic esophageal pouch after an attempt to pass the tube into the stomach. X-ray will also show a **stomach bubble**, which results from air flow from the trachea through the fistula to the distal esophagus.

(Choice A) Atresia of the small intestine is a congenital defect that leads to complete obstruction of the gastrointestinal tract at the site of atresia. Neonates present with abdominal distension and bilious emesis.

(Choice B) Laryngomalacia presents with inspiratory stridor during infancy due to collapse of supraglottic structures during inspiration. Stridor is classically worse in the supine position and improves with upright positioning.

(Choice D) Choanal atresia is characterized by congenital obstruction of the posterior nasal passages. Infants with bilateral choanal atresia can present with upper airway obstruction and cyanosis with feeding, but not excessive drooling and coughing. Inability to pass a nasogastric tube through the nares is suggestive of the diagnosis.

(Choice E) Herniation of abdominal viscera into the thoracic cavity occurs in congenital diaphragmatic hernia. Infants typically exhibit respiratory distress shortly after birth due to pulmonary hypoplasia. The presence of abdominal viscera in the thorax results in a scaphoid abdomen and bowel sounds heard over the chest.

Educational objective:
Tracheoesophageal fistula with esophageal atresia results from failure of the primitive foregut to appropriately divide into separate trachea and esophageal structures. Infants present shortly after birth with excessive secretions and choking/cyanosis during feeds.

References

from air flow from the trachea through the fistula to the distal esophagus.

(Choice A) Atresia of the small intestine is a congenital defect that leads to complete obstruction of the gastrointestinal tract at the site of atresia. Neonates present with abdominal distension and bilious emesis.

(Choice B) Laryngomalacia presents with inspiratory stridor during infancy due to collapse of supraglottic structures during inspiration. Stridor is classically worse in the supine position and improves with upright positioning.

(Choice D) Choanal atresia is characterized by congenital obstruction of the posterior nasal passages. Infants with bilateral choanal atresia can present with upper airway obstruction and cyanosis with feeding, but not excessive drooling and coughing. Inability to pass a nasogastric tube through the nares is suggestive of the diagnosis.

(Choice E) Herniation of abdominal viscera into the thoracic cavity occurs in congenital diaphragmatic hernia. Infants typically exhibit respiratory distress shortly after birth due to pulmonary hypoplasia. The presence of abdominal viscera in the thorax results in a scaphoid abdomen and bowel sounds heard over the chest.

Educational objective:
Tracheoesophageal fistula with esophageal atresia results from failure of the primitive foregut to appropriately divide into separate trachea and esophageal structures. Infants present shortly after birth with excessive secretions and choking/cyanosis during feeds.

References

- Oesophageal atresia and tracheo-oesophageal fistula.
- Current knowledge on esophageal atresia.
- Tracheo-oesophageal fistula (TOF) and oesophageal atresia (OA).

Embryology	Gastrointestinal & Nutrition	Tracheoesophageal fistula
Subject	System	Topic

Copyright © UWorld. All rights reserved.

from air flow from the trachea through the fistula to the distal esophagus.

Exhibit Display

Choanal atresia

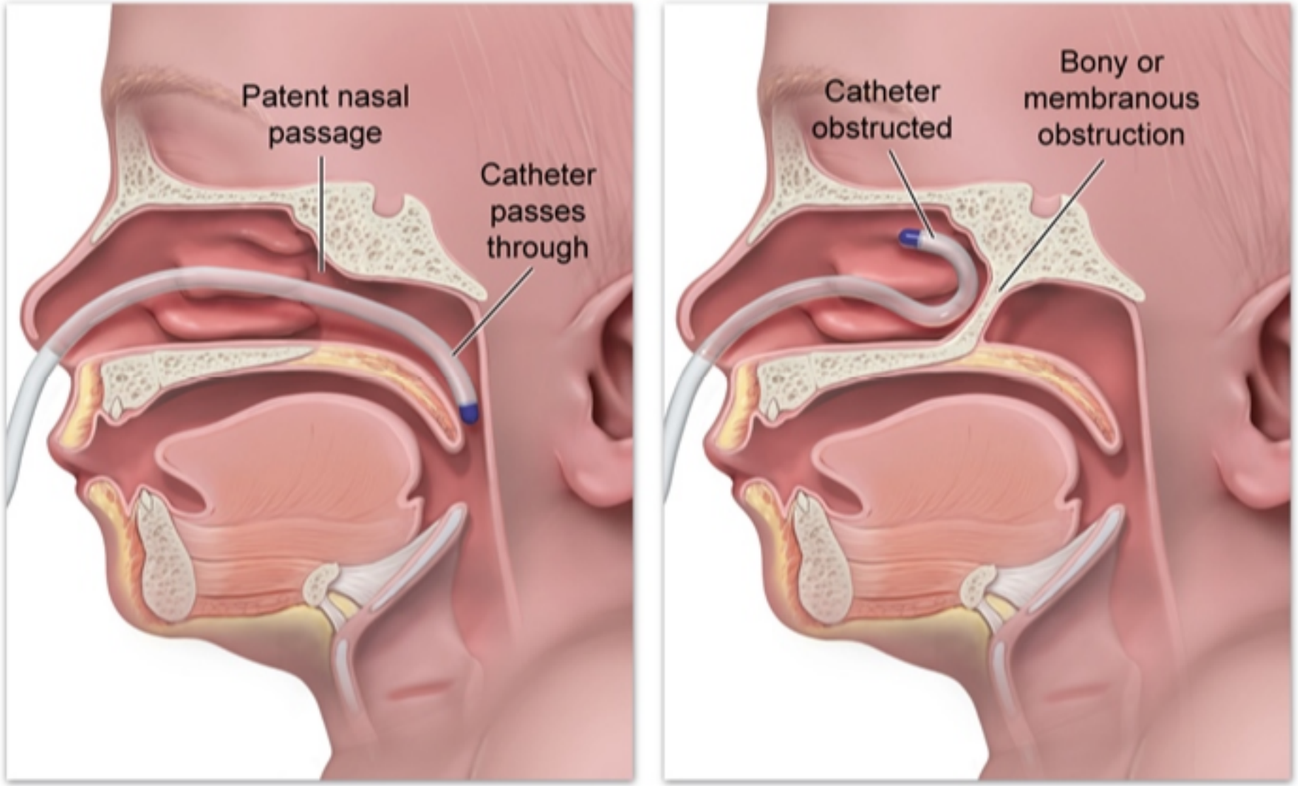

Normal anatomy

Choanal atresia

©UWorld

Zoom In | Zoom Out | Reset | Add To New Card | Existing Card

Settings

1 2 3 4 5 6 7 8 9 10 11 12 13 14 15 16 17 18 19 20 21 22 23 24 25 26 27 28 29 30

Item 30 of 40
Question Id: 328

Mark | Previous | Next | Full Screen | Tutorial | Lab Values | Notes | Calculator | Reverse Color | Text Zoom | Settings

A 3-year-old boy is brought to the physician's office by his parents because of abdominal pain. Physical examination reveals rectal bleeding, and the patient undergoes an appropriate diagnostic workup. Laparotomy is then performed. Surgical findings include a blind pouch connected to the ileum, with a fibrous band seen attaching the end of the pouch to the umbilicus. The walls of this pouch are most likely composed of which of the following?

A. Fibrous tissue

B. Granulation tissue and peritoneum

C. Mucosa and submucosa layers

D. Omentum and adipose tissue

E. Mucosa, submucosa, and muscular layers

Submit

Block Time Remaining: 00:01:14
TUTOR

2 | Feedback | Suspend | End Block

A 3-year-old boy is brought to the physician's office by his parents because of abdominal pain. Physical examination reveals rectal bleeding, and the patient undergoes an appropriate diagnostic workup. Laparotomy is then performed. Surgical findings include a blind pouch connected to the ileum, with a fibrous band seen attaching the end of the pouch to the umbilicus. The walls of this pouch are most likely composed of which of the following?

- A. Fibrous tissue (3%)
- B. Granulation tissue and peritoneum (3%)
- C. Mucosa and submucosa layers (17%)
- D. Omentum and adipose tissue (2%)
- ✓ E. Mucosa, submucosa, and muscular layers (72%)

Omitted
Correct answer
E

72%
Answered correctly

02 secs
Time Spent

06/23/2020
Last Updated

Explanation

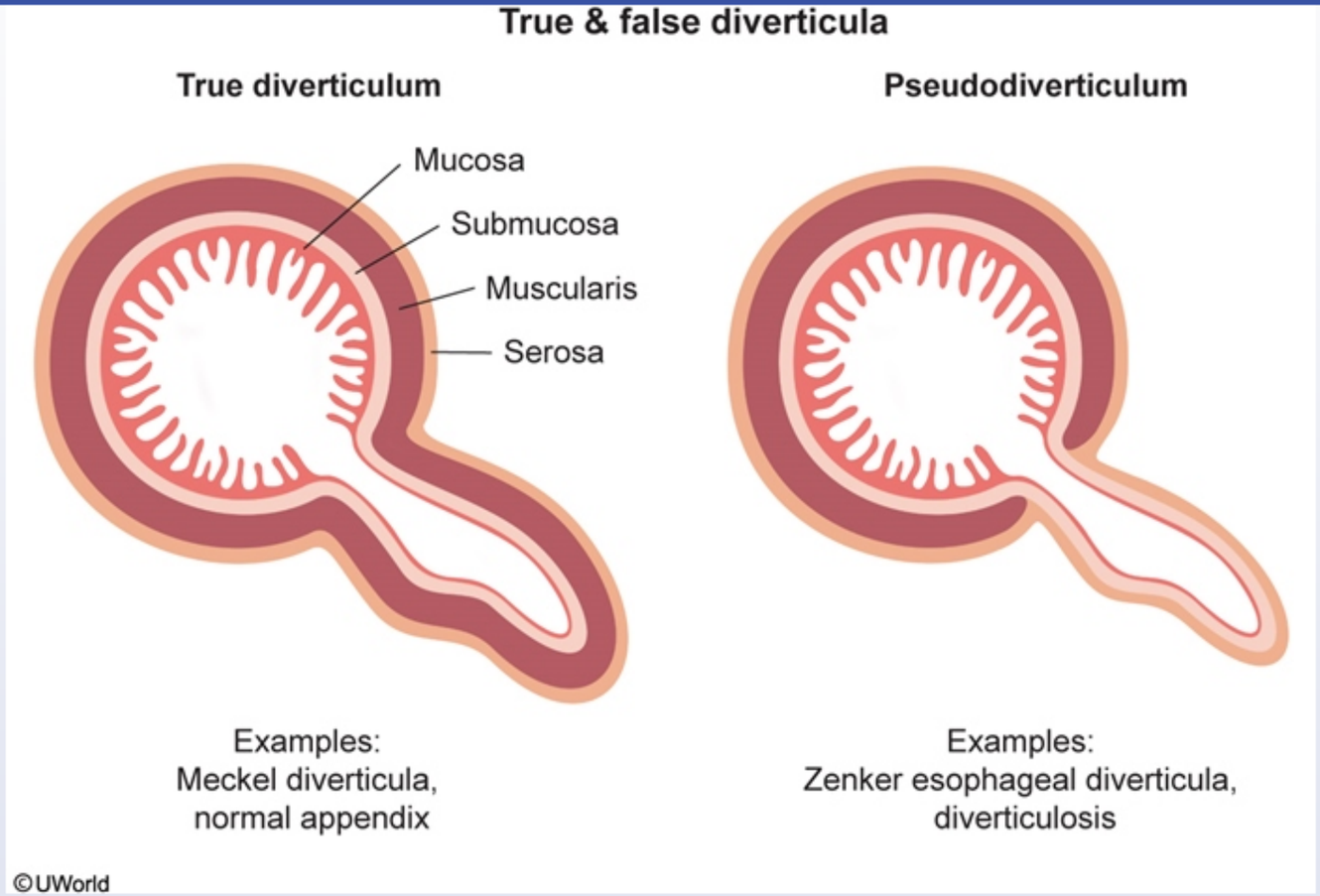

During early embryogenesis, the lumen of the midgut and yolk sac cavity are connected via the omphalomesenteric (vitelline) duct. This duct normally obliterates during the 7th week of fetal life. Partial failure of this duct to obliterate leads to the formation of Meckel's diverticulum. Meckel's diverticulum may present with rectal bleeding or intestinal obstruction; however, most cases are asymptomatic. Remember the rule of 2's with Meckel's diverticulum: 2% of the population, 2 feet from the ileocecal valve, 2 inches in length, 2% are symptomatic, and males are 2 times more likely to be affected.

In contrast to false diverticula, which contain mucosa and submucosa only, Meckel's diverticulum is a true diverticulum, consisting of all three parts

©UWorld

During early embryogenesis, the lumen of the midgut and yolk sac cavity are connected via the omphalomesenteric (vitelline) duct. This duct normally obliterates during the 7th week of fetal life. Partial failure of this duct to obliterate leads to the formation of Meckel's diverticulum. Meckel's diverticulum may present with rectal bleeding or intestinal obstruction; however, most cases are asymptomatic. Remember the rule of 2's with Meckel's diverticulum: 2% of the population, 2 feet from the ileocecal valve, 2 inches in length, 2% are symptomatic, and males are 2 times more likely to be affected.

In contrast to false diverticula, which contain mucosa and submucosa only, Meckel's diverticulum is a true diverticulum, consisting of all three parts of the intestinal wall: mucosa, submucosa, and muscularis. It also often contains ectopic mucosa–gastric epithelium being the most common (pancreatic tissue is the next most common). This ectopic gastric tissue secretes gastric acid that can cause ulceration of adjacent mucosa and lower GI bleeding (melena/hematochezia).

(Choice C) False diverticula contain only mucosa and submucosa. These layers herniate through defects in the muscular layer. Colonic and Zenker (upper esophageal) diverticula are examples of false (pulsion) diverticula.

(Choices A, B,& D) Fibrous tissue, granulation tissue, and omentum are not histologically present in Meckel's diverticulum. In addition to containing all three portions of the intestinal wall, Meckel's diverticulum may also contain ectopic tissue, such as gastric or pancreatic tissue.

Educational objective:
Meckel's diverticulum is a remnant of the omphalomesenteric (vitelline) duct. It is connected to the ileum and is located 2 feet proximal to the ileocecal valve. It often contains acid-secreting ectopic gastric tissue, which may cause ulceration of the adjacent mucosa and lower GI bleeding (melena/hematochezia). Meckel's diverticulum is a true diverticulum and consists of all parts of the intestinal wall.

References

- Meckel diverticulum: the Mayo Clinic experience with 1476 patients (1950-2002).

Embryology	Gastrointestinal & Nutrition	Meckel diverticulum
Subject	System	Topic

A 23-year-old woman, gravida 2 para 1, with poorly controlled type 1 diabetes and hypothyroidism comes to the hospital with preterm, premature rupture of membrane at 30 weeks' gestation. Her medications include prenatal vitamins and insulin. Vital signs are normal and examination shows clear vaginal discharge. The patient's cervix is closed and she has no uterine contractions. Laboratory results are as follows:

Hemoglobin	11.8 g/dL
Glucose	200 mg/dL
Hemoglobin A1c	7.2%

Which of the following medications has the greatest positive impact on fetal survival?

A. Dexamethasone

B. Insulin

C. Magnesium

D. Nifedipine

E. Terbutaline

Submit

A 23-year-old woman, gravida 2 para 1, with poorly controlled type 1 diabetes and hypothyroidism comes to the hospital with preterm, premature rupture of membrane at 30 weeks' gestation. Her medications include prenatal vitamins and insulin. Vital signs are normal and examination shows clear vaginal discharge. The patient's cervix is closed and she has no uterine contractions. Laboratory results are as follows:

Hemoglobin	11.8 g/dL
Glucose	200 mg/dL
Hemoglobin A1c	7.2%

Which of the following medications has the greatest positive impact on fetal survival?

- ✓ A. Dexamethasone (61%)
- B. Insulin (20%)
- C. Magnesium (5%)
- D. Nifedipine (4%)
- E. Terbutaline (8%)

Omitted
Correct answer
A

61%
Answered correctly

02 secs
Time Spent

02/27/2020
Last Updated

Explanation

In the terminal saccular stage of lung development, the type II pneumocytes produce pulmonary surfactant, a lipoprotein complex rich in phospholipids, most notably **dipalmitoylphosphatidylcholine** (DPPC, a type of lecithin). This surfactant **decreases** alveolar **surface tension** by creating a lipid-rich monolayer that separates alveolar gas from the underlying aqueous fluid. The phenomenon prevents atelectasis and end-expiratory collapse and increases pulmonary compliance.

In a fetus, efflux of lung fluid into amniotic fluid enables testing of markers of lung maturity. Until 33 weeks gestation, the lecithin and sphingomyelin levels are about equal. After 33 weeks, the lecithin levels rise dramatically compared to sphingomyelin. A lecithin-to-sphingomyelin ratio >1.9 is indicative of mature fetal lungs.

Premature infants born at <32 weeks gestation are at significant risk of surfactant deficiency. Corticosteroids (eg, **betamethasone, dexamethasone**) have the greatest effect on increasing surfactant production by accelerating **maturation of type II pneumocytes**. They are administered to patients at risk for preterm labor (eg, preterm premature rupture of membranes) to decrease the risk of respiratory distress syndrome and mortality.

(Choice B) Uncontrolled maternal hyperglycemia causes fetal hyperinsulinemia and inhibits the maturational effects of cortisol and the production of surfactant proteins. Infants of these mothers can develop respiratory distress syndrome. Although corticosteroids cause temporary hyperglycemia, the beneficial effects of maternal steroid administration on surfactant production and eventual reduction of mortality far outweigh this side effect.

(Choice C) In pregnancies at risk for preterm delivery, antenatal administration of magnesium sulfate has been shown to decrease the risk for cerebral palsy. While cerebral palsy can result in permanent neurologic disability, impaired lung function is a more common cause of death in premature infants.

(Choices D and E) Nifedipine and terbutaline are medications used for inhibition of preterm labor (tocolysis). Nifedipine is a calcium channel blocker and results in myometrial relaxation by inhibition of myosin light-chain kinase-mediated phosphorylation. Terbutaline is a β-sympathomimetic that increases intracellular cAMP formation in myometrial cells. This inhibits myosin light-chain kinase and relaxes the smooth muscle. Neither drug directly affects fetal lung maturity.

Educational objective:

administered to patients at risk for preterm labor (eg, preterm premature rupture of membranes) to decrease the risk of respiratory distress syndrome and mortality.

(Choice B) Uncontrolled maternal hyperglycemia causes fetal hyperinsulinemia and inhibits the maturational effects of cortisol and the production of surfactant proteins. Infants of these mothers can develop respiratory distress syndrome. Although corticosteroids cause temporary hyperglycemia, the beneficial effects of maternal steroid administration on surfactant production and eventual reduction of mortality far outweigh this side effect.

(Choice C) In pregnancies at risk for preterm delivery, antenatal administration of magnesium sulfate has been shown to decrease the risk for cerebral palsy. While cerebral palsy can result in permanent neurologic disability, impaired lung function is a more common cause of death in premature infants.

(Choices D and E) Nifedipine and terbutaline are medications used for inhibition of preterm labor (tocolysis). Nifedipine is a calcium channel blocker and results in myometrial relaxation by inhibition of myosin light-chain kinase-mediated phosphorylation. Terbutaline is a β-sympathomimetic that increases intracellular cAMP formation in myometrial cells. This inhibits myosin light-chain kinase and relaxes the smooth muscle. Neither drug directly affects fetal lung maturity.

Educational objective:
Both maternal and fetal cortisol help to accelerate fetal lung maturation by stimulating surfactant production. Betamethasone or dexamethasone is administered to pregnant women at risk of premature delivery to prevent neonatal respiratory distress syndrome.

References

- Prevention of preterm delivery.
- Antenatal corticosteroids for accelerating fetal lung maturation for women at risk of preterm birth.

Embryology	Pulmonary & Critical Care	Neonatal respiratory distress syndrome
Subject	System	Topic

Copyright © UWorld. All rights reserved.

A 1-week-old boy is brought to the emergency department with poor feeding, lethargy, and unusual "muscle movements" involving the left thumb and hand over the last 2 days. The patient's mother had appropriate prenatal care, a normal pregnancy, and took no medications other than prenatal vitamins. The infant's vital signs are normal, but unusual flexion of the left wrist and thumb and extension of the fingers are observed with cuff blood pressure measurement. Physical examination reveals a hypoplastic mandible, low-set ears, bifid uvula, and cleft palate. A chest x-ray reveals decreased soft-tissue attenuation in the right anterior mediastinum. These findings most likely suggest impaired development of which of the following embryonic structures?

- A. Anterior neuropore
- B. Foramen cecum
- C. Rathke pouch
- D. Second pharyngeal cleft
- E. Third pharyngeal pouch

Submit

A 1-week-old boy is brought to the emergency department with poor feeding, lethargy, and unusual "muscle movements" involving the left thumb and hand over the last 2 days. The patient's mother had appropriate prenatal care, a normal pregnancy, and took no medications other than prenatal vitamins. The infant's vital signs are normal, but unusual flexion of the left wrist and thumb and extension of the fingers are observed with cuff blood pressure measurement. Physical examination reveals a hypoplastic mandible, low-set ears, bifid uvula, and cleft palate. A chest x-ray reveals decreased soft-tissue attenuation in the right anterior mediastinum. These findings most likely suggest impaired development of which of the following embryonic structures?

- A. Anterior neuropore (3%)
- B. Foramen cecum (1%)
- C. Rathke pouch (5%)
- D. Second pharyngeal cleft (12%)
- ✓ E. Third pharyngeal pouch (77%)

Omitted
Correct answer
E

77%
Answered correctly

01 sec
Time Spent

03/16/2020
Last Updated

Explanation

Settings

Item 32 of 40
Question Id: 543

Mark | Previous | Next | Full Screen | Tutorial | Lab Values | Notes | Calculator | Reverse Color | Text Zoom | Settings

Exhibit Display

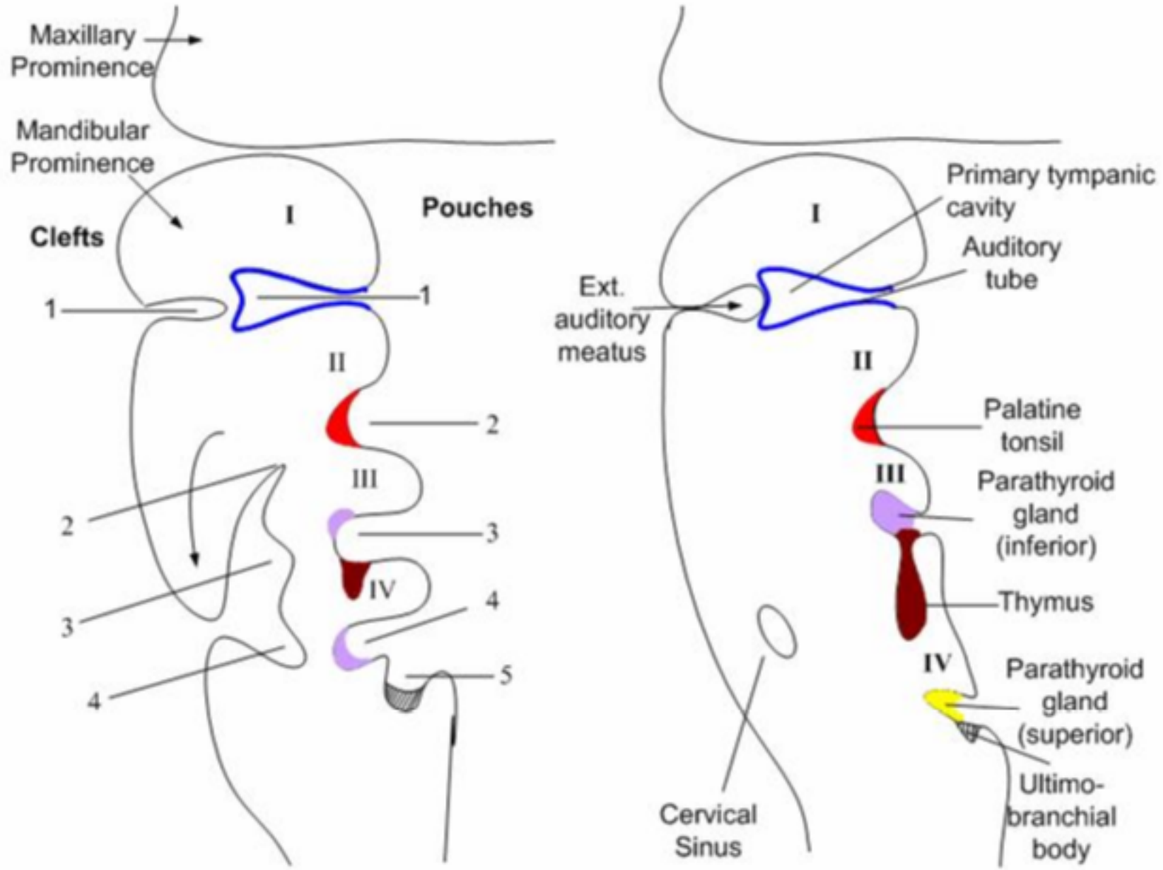

Zoom In | Zoom Out | Reset | Add To New Card | Existing Card

Block Time Remaining: 00:01:18
TUTOR

6 | Feedback | Suspend | End Block

A **22q11.2 microdeletion** underlies the spectrum of physical features seen in DiGeorge syndrome (DGS). Embryologically, the neural crest fails to migrate into the derivatives of the **third** (affects inferior **parathyroid** and thymus) and fourth (affects superior parathyroid) pharyngeal/branchial pouches. The consequent parathyroid and thymic hypoplasia results in **hypocalcemia** and T cell deficiency, respectively.

The hypocalcemia in DGS leads to increased neuromuscular excitability, which manifests as tetany, carpopedal spasms, or seizures. Tapping on the facial nerve usually elicits **twitching of the nose and lips (Chvostek sign)**, and inflation of the blood pressure cuff leads to **carpal spasm (Trousseau sign)**. Normally, the thymic shadow is visible on a newborn's x-ray. Its absence reflects thymic hypoplasia, which leads to T cell dysfunction and results in recurrent viral, fungal, and protozoan infections.

Conotruncal cardiac anomalies (eg, interrupted aortic arch, truncus arteriosus) may also result from failure of neural crest migration. If there is additional involvement of the first and second pharyngeal/branchial pouches, patients with DGS may have features such as hypertelorism, short palpebral fissures, micrognathia, bifid uvula, and cleft palate.

(Choice A) Failure of the anterior neuropore to close leads to neural tube defects such as anencephaly. Neural tube defects can be prevented with maternal folic acid supplementation.

(Choice B) The foramen cecum is a depression on the tongue that represents the embryological remnant of the superior end of the obliterated thyroglossal duct. A persistent duct results in a thyroglossal cyst that presents as a midline neck mass.

(Choice C) Rathke pouch represents an invaginated oral ectoderm that eventually develops into the anterior pituitary. Craniopharyngiomas arise from remnants of this pouch and can result in hypopituitarism, hydrocephalus, and diabetes insipidus, but not hypocalcemia.

(Choice D) The second branchial cleft (ie, second pharyngeal groove) is normally obliterated in utero. Persistence leads to a branchial cleft cyst between the angle of the mandible and sternocleidomastoid muscle.

Educational objective:
DiGeorge syndrome results from maldevelopment of the third (inferior parathyroid and thymus) and fourth (superior parathyroid) pharyngeal/branchial pouches. Subsequent parathyroid and thymic hypoplasia results in hypocalcemia and T cell deficiency.

References

the facial nerve usually elicits **twitching of the nose and lips (Chvostek sign)**, and inflation of the blood pressure cuff leads to **carpal spasm (Trousseau sign)**. Normally, the thymic shadow is visible on a newborn's x-ray. Its absence reflects thymic hypoplasia, which leads to T cell dysfunction and results in recurrent viral, fungal, and protozoan infections.

Conotruncal cardiac anomalies (eg, interrupted aortic arch, truncus arteriosus) may also result from failure of neural crest migration. If there is additional involvement of the first and second pharyngeal/branchial pouches, patients with DGS may have features such as hypertelorism, short palpebral fissures, micrognathia, bifid uvula, and cleft palate.

(Choice A) Failure of the anterior neuropore to close leads to neural tube defects such as anencephaly. Neural tube defects can be prevented with maternal folic acid supplementation.

(Choice B) The foramen cecum is a depression on the tongue that represents the embryological remnant of the superior end of the obliterated thyroglossal duct. A persistent duct results in a thyroglossal cyst that presents as a midline neck mass.

(Choice C) Rathke pouch represents an invaginated oral ectoderm that eventually develops into the anterior pituitary. Craniopharyngiomas arise from remnants of this pouch and can result in hypopituitarism, hydrocephalus, and diabetes insipidus, but not hypocalcemia.

(Choice D) The second branchial cleft (ie, second pharyngeal groove) is normally obliterated in utero. Persistence leads to a branchial cleft cyst between the angle of the mandible and sternocleidomastoid muscle.

Educational objective:
DiGeorge syndrome results from maldevelopment of the third (inferior parathyroid and thymus) and fourth (superior parathyroid) pharyngeal/branchial pouches. Subsequent parathyroid and thymic hypoplasia results in hypocalcemia and T cell deficiency.

References

- Velocardiofacial syndrome, DiGeorge syndrome: the chromosome 22q11.2 deletion syndromes.

Embryology	Endocrine, Diabetes & Metabolism	Digeorge syndrome
Subject	System	Topic

Copyright © UWorld. All rights reserved.

Settings

1 2 3 4 5 6 7 8 9 10 11 12 13 14 15 16 17 18 19 20 21 22 23 24 25 26 27 28 29 30

Item 32 of 40
Question Id: 543

Mark | Previous | Next | Full Screen | Tutorial | Lab Values | Notes | Calculator | Reverse Color | Text Zoom | Settings

the facial nerve usually elicits **twitching of the nose and lips (Chvostek sign)**; and inflation of the blood pressure cuff leads to **carpal spasm (Trousseau sign)**. Normally, the thymic shadow is visible on a newborn's x-ray. Its absence reflects thymic hypoplasia, which leads to T cell

Exhibit Display

Zoom In | Zoom Out | Reset | Add To New Card | Existing Card

Block Time Remaining: 00:01:18
TUTOR

6 | Feedback | Suspend | End Block

Settings

1 2 3 4 5 6 7 8 9 10 11 12 13 14 15 16 17 18 19 20 21 22 23 24 25 26 27 28 29 30

Item 32 of 40
Question Id: 543

Mark | Previous | Next | Full Screen | Tutorial | Lab Values | Notes | Calculator | Reverse Color | Text Zoom | Settings

the facial nerve usually elicits twitching of the nose and lips (Chvostek sign), and inflation of the blood pressure cuff leads to carpal spasm (Trousseau sign). Normally, the thymic shadow is visible on a newborn's x-ray. Its absence reflects thymic hypoplasia, which leads to T cell

Exhibit Display

Thymus x-ray Thymus x-ray

Zoom In | Zoom Out | Reset | Add To New Card | Existing Card

Block Time Remaining: 00:01:18
TUTOR

6 | Feedback | Suspend | End Block

Settings

1 2 3 4 5 6 7 8 9 10 11 12 13 14 15 16 17 18 19 20 21 22 23 24 25 26 27 28 29 30

Item 32 of 40
Question Id: 543

Mark | Previous | Next | Full Screen | Tutorial | Lab Values | Notes | Calculator | Reverse Color | Text Zoom | Settings

the facial nerve usually elicits twitching of the nose and lips (Chvostek sign), and inflation of the blood pressure cuff leads to carpal spasm (Trousseau sign). Normally, the thymic shadow is visible on a newborn's x-ray. Its absence reflects thymic hypoplasia, which leads to T cell

Exhibit Display

Thymus x-ray Thymus x-ray

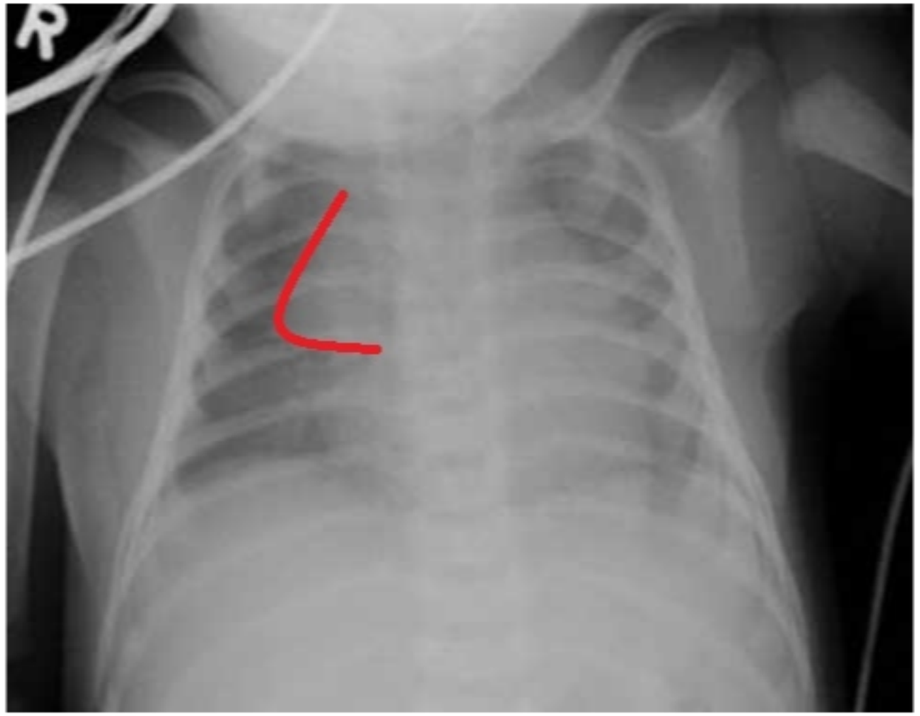

Zoom In | Zoom Out | Reset | Add To New Card | Existing Card

Block Time Remaining: 00:01:18
TUTOR

6 | Feedback | Suspend | End Block

Settings

1 2 3 4 5 6 7 8 9 10 11 12 13 14 15 16 17 18 19 20 21 22 23 24 25 26 27 28 29 30

Item 32 of 40
Question Id: 543

Mark | Previous | Next | Full Screen | Tutorial | Lab Values | Notes | Calculator | Reverse Color | Text Zoom | Settings

Exhibit Display

Pituitary embryology

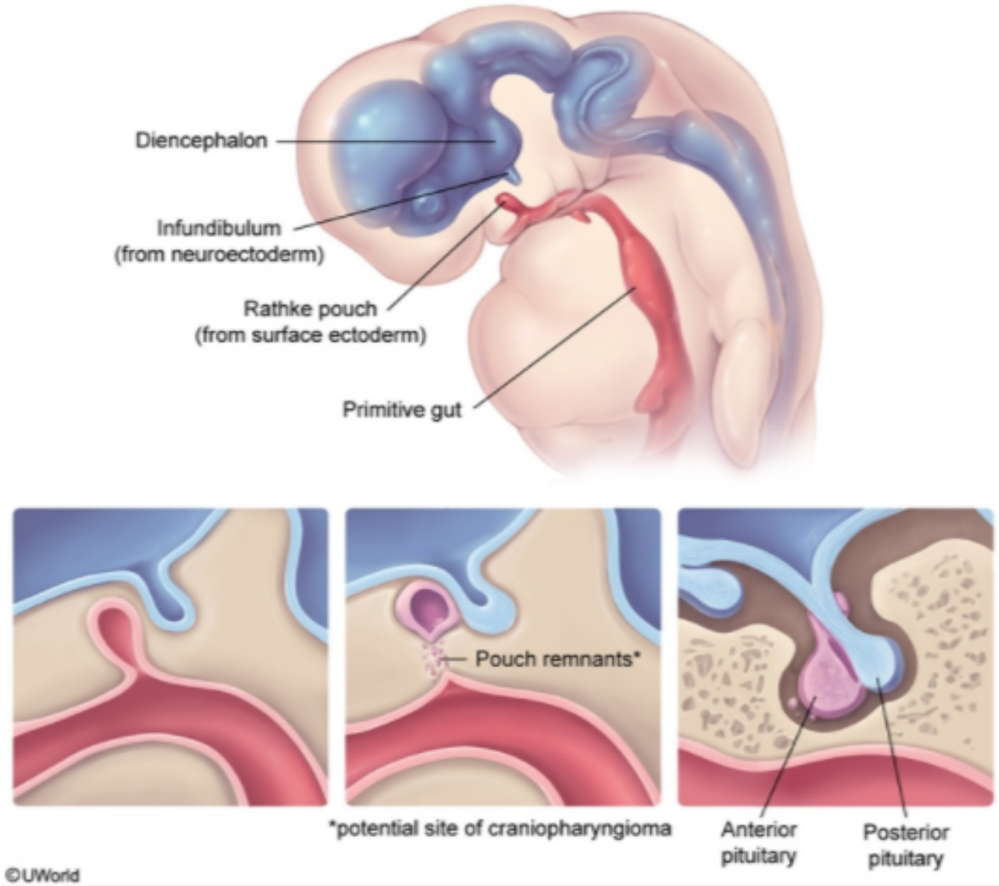

Zoom In | Zoom Out | Reset | Add To New Card | Existing Card

Block Time Remaining: 00:01:18
TUTOR

6 | Feedback | Suspend | End Block

A 3-year-old boy is brought to the emergency department by his parents after he develops acute abdominal pain and vomiting. Imaging studies reveal a foreign body lodged within his intestine causing a small bowel obstruction. Laparotomy is performed to remove the foreign body; during the procedure, an incidental abdominal cyst is discovered and removed. The cyst is connected by a fibrous band to the ileum and the umbilicus. Which of the following conditions is also caused by the same embryologic defect responsible for this patient's abdominal cyst?

- A. Duodenal atresia
- B. Hirschsprung disease
- C. Meckel diverticulum
- D. Umbilical hernia
- E. Imperforate anus
- F. Omphalocele
- G. Malrotation

Submit

A 3-year-old boy is brought to the emergency department by his parents after he develops acute abdominal pain and vomiting. Imaging studies reveal a foreign body lodged within his intestine causing a small bowel obstruction. Laparotomy is performed to remove the foreign body; during the procedure, an incidental abdominal cyst is discovered and removed. The cyst is connected by a fibrous band to the ileum and the umbilicus. Which of the following conditions is also caused by the same embryologic defect responsible for this patient's abdominal cyst?

- A. Duodenal atresia (1%)
- B. Hirschsprung disease (0%)
- ✓ C. Meckel diverticulum (79%)
- D. Umbilical hernia (5%)
- E. Imperforate anus (1%)
- F. Omphalocele (8%)
- G. Malrotation (2%)

Omitted
Correct answer
C

79%
Answered correctly

02 secs
Time Spent

05/13/2020
Last Updated

Explanation

Vitelline duct abnormalities

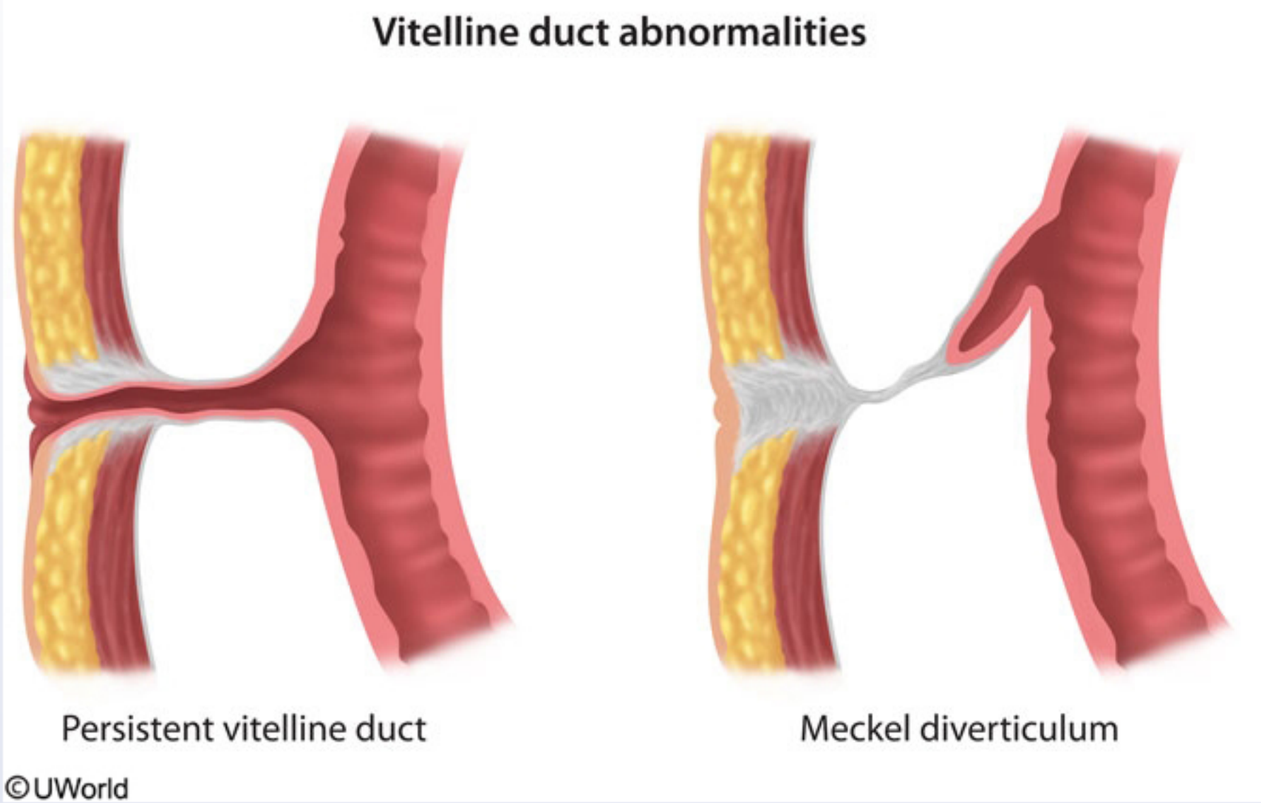

The omphalomesenteric (vitelline) duct connects the midgut lumen with the yolk sac cavity early in embryonic life. It normally obliterates during the 7th week of embryonic development. If its obliteration is incomplete or abnormal, a number of abnormalities can result:

1. A **persistent vitelline duct**, or vitelline fistula, occurs due to complete failure of the vitelline duct to close. A small connection between the intestinal lumen and the outside of the body exists at the umbilicus. Meconium discharge from the umbilicus is seen soon after birth if such a fistula is present.
2. **Meckel diverticulum** is the most common vitelline duct anomaly. It results from a partial closure of the vitelline duct, with the patent portion attached to the ileum. A fibrous band may connect the tip of the Meckel diverticulum with the umbilicus.

The omphalomesenteric (vitelline) duct connects the midgut lumen with the yolk sac cavity early in embryonic life. It normally obliterates during the 7th week of embryonic development. If its obliteration is incomplete or abnormal, a number of abnormalities can result:

1. A **persistent vitelline duct**, or vitelline fistula, occurs due to complete failure of the vitelline duct to close. A small connection between the intestinal lumen and the outside of the body exists at the umbilicus. Meconium discharge from the umbilicus is seen soon after birth if such a fistula is present.
2. **Meckel diverticulum** is the most common vitelline duct anomaly. It results from a partial closure of the vitelline duct, with the patent portion attached to the ileum. A fibrous band may connect the tip of the Meckel diverticulum with the umbilicus.
3. **Vitelline sinus** results from a partial closure of the vitelline duct, with the patent portion open at the umbilicus.
4. **Vitelline duct cyst** (enterocyst) forms if peripheral portions of the vitelline duct (connected to the ileum and umbilicus) obliterate, but the central part remains. This cyst is connected with the ileum and abdominal wall by fibrous bands.

Most vitelline duct abnormalities are asymptomatic and often discovered incidentally. However, Meckel diverticulum may present with rectal bleeding or intestinal obstruction. Remember the rule of 2's with Meckel diverticulum: 2% of the population, 2 feet from the ileocecal valve, 2 inches in length, 2% are symptomatic, and males are 2 times more likely to be affected.

(Choice A) Duodenal atresia results from failure of the duodenum to recanalize in early embryonic life. Although often associated with trisomy 21, it is not associated with any vitelline duct anomalies.

(Choice B) Hirschsprung disease results from the failure of migration of neural crest cells into the intestinal wall.

(Choice D) Umbilical hernias occur due to weakness of the abdominal wall at the umbilicus. These hernias are common in children and usually close spontaneously by 2 years of age. Unlike omphaloceles, umbilical hernias are midline protrusions that are covered by skin.

(Choice E) Imperforate anus occurs due to abnormal development of anorectal structures. This condition manifests during the first days of life, when the newborn fails to pass meconium.

(Choice F) Omphalocele is a midline defect in the abdominal wall due to incomplete closure during fetal life. Abdominal organs protrude through the defect, covered with a peritoneal sac.

(Choice G) Malrotation results from the failure of the midgut to rotate counterclockwise as it returns to the abdominal cavity during early

bleeding or intestinal obstruction. Remember the rule of 2's with Meckel diverticulum: 2% of the population, 2 feet from the ileocecal valve, 2 inches in length, 2% are symptomatic, and males are 2 times more likely to be affected.

(Choice A) Duodenal atresia results from failure of the duodenum to recanalize in early embryonic life. Although often associated with trisomy 21, it is not associated with any vitelline duct anomalies.

(Choice B) Hirschsprung disease results from the failure of migration of neural crest cells into the intestinal wall.

(Choice D) Umbilical hernias occur due to weakness of the abdominal wall at the umbilicus. These hernias are common in children and usually close spontaneously by 2 years of age. Unlike omphaloceles, umbilical hernias are midline protrusions that are covered by skin.

(Choice E) Imperforate anus occurs due to abnormal development of anorectal structures. This condition manifests during the first days of life, when the newborn fails to pass meconium.

(Choice F) Omphalocele is a midline defect in the abdominal wall due to incomplete closure during fetal life. Abdominal organs protrude through the defect, covered with a peritoneal sac.

(Choice G) Malrotation results from the failure of the midgut to rotate counterclockwise as it returns to the abdominal cavity during early embryonic development. Malrotation leads to abnormal positioning of the intestine in the abdominal cavity and sometimes twisting of an intestinal loop (volvulus).

Educational objective:
The omphalomesenteric (vitelline) duct normally obliterates during the 7th week of embryonic development. Both enterocysts and Meckel diverticula result from a failure of obliteration involving the omphalomesenteric duct.

References

- Meckel diverticulum: the Mayo Clinic experience with 1476 patients (1950-2002).

Embryology	Gastrointestinal & Nutrition	Meckel diverticulum
Subject	System	Topic

Copyright © UWorld. All rights reserved.

A 16-year-old obese primigravida girl comes to the emergency department in active labor. In an attempt to conceal the pregnancy from her family, the patient did not receive prenatal care or take prenatal vitamins. A fetal heartbeat is undetectable, and she delivers a stillborn boy via vaginal delivery. Examination of the stillborn shows several dysmorphic features including closely set eyes and a midline mass consistent with a proboscis. A fetal autopsy reveals fused cerebral hemispheres with an absent forebrain fissure and a single intracranial ventricle. Which of the following is the most likely mechanism for these findings?

- A. Agenesis
- B. Association
- C. Deformation
- D. Dysplasia
- E. Field defect

Submit

A 16-year-old obese primigravida girl comes to the emergency department in active labor. In an attempt to conceal the pregnancy from her family, the patient did not receive prenatal care or take prenatal vitamins. A fetal heartbeat is undetectable, and she delivers a stillborn boy via vaginal delivery. Examination of the stillborn shows several dysmorphic features including closely set eyes and a midline mass consistent with a proboscis. A fetal autopsy reveals fused cerebral hemispheres with an absent forebrain fissure and a single intracranial ventricle. Which of the following is the most likely mechanism for these findings?

- A. Agenesis (39%)
- B. Association (6%)
- C. Deformation (27%)
- D. Dysplasia (6%)
- ✓ E. Field defect (19%)

Omitted
Correct answer
E

19%
Answered correctly

01 sec
Time Spent

07/02/2020
Last Updated

Explanation

Holoprosencephaly	
Embryology	Incomplete division of the forebrain (prosencephalon) into

Explanation

Holoprosencephaly	
Embryology	Incomplete division of the forebrain (prosencephalon) into 2 hemispheres
Etiologies	• Genetic (eg, trisomy 13, sonic hedgehog gene mutations) • Environmental (eg, maternal alcohol use)
Clinical features	Range of phenotypic findings: • **Mild:** Closely set eyes (hypotelorism), cleft lip/palate • **Severe:** Single midline eye (cyclopia), primitive nasal structure (proboscis), midfacial clefts

©UWorld

The physical features of the stillborn are consistent with holoprosencephaly (HPE), which is a spectrum of structural abnormalities of the brain and face due to **incomplete division of the forebrain** (prosencephalon) into 2 hemispheres. Cleavage of the prosencephalon into the telencephalon and diencephalon normally occurs at **5 weeks gestation**. Failure of cleavage at different points in division can result in an array of anomalies ranging from mild midline defects (eg, ocular hypotelorism, cleft lip/palate) to severe defects (eg, single midline eye, primitive nasal structure or proboscis, midfacial clefts).

HPE is likely caused by a combination of genetic (eg, trisomy 13, sonic hedgehog gene mutations) and environmental (eg, maternal alcohol use) factors. It is an example of a **developmental field defect**, which is when an initial embryonic disturbance leads to multiple malformations by disrupting the development of adjacent tissues and structures within a particular region.

(Choice A) Agenesis refers to the complete absence of an organ. Renal agenesis, the congenital absence of one or both kidneys, is an example

©UWorld

The physical features of the stillborn are consistent with holoprosencephaly (HPE), which is a spectrum of structural abnormalities of the brain and face due to **incomplete division of the forebrain** (prosencephalon) into 2 hemispheres. Cleavage of the prosencephalon into the telencephalon and diencephalon normally occurs at **5 weeks gestation**. Failure of cleavage at different points in division can result in an array of anomalies ranging from mild midline defects (eg, ocular hypotelorism, cleft lip/palate) to severe defects (eg, single midline eye, primitive nasal structure or proboscis, midfacial clefts).

HPE is likely caused by a combination of genetic (eg, trisomy 13, sonic hedgehog gene mutations) and environmental (eg, maternal alcohol use) factors. It is an example of a **developmental field defect**, which is when an initial embryonic disturbance leads to multiple malformations by disrupting the development of adjacent tissues and structures within a particular region.

(Choice A) Agenesis refers to the complete absence of an organ. Renal agenesis, the congenital absence of one or both kidneys, is an example of this type of abnormality.

(Choice B) An association refers to multiple anomalies without a known unifying cause that occur together more frequently than chance alone would predict. Vertebral defects, anal atresia, cardiac defects, tracheo-esophageal fistula, renal anomalies, and limb abnormalities (VACTERL) are an example of an association of anomalies without a known common etiology.

(Choice C) Deformations are fetal structural anomalies that occur due to extrinsic mechanical forces. The pressure applied by the uterus is one of the most common deforming forces. For example, uterine constraint on a fetus in breech position can cause developmental dysplasia of the hip, a condition marked by abnormal development of the femoral-acetabular junction and subsequent hip instability.

(Choice D) Dysplasia describes abnormal organization of cellular architecture within a tissue. Osteogenesis imperfecta, a skeletal disorder characterized by brittle bones that fracture easily, occurs with dysplasia of connective tissue due to absent or abnormal type I collagen.

Educational objective:
A developmental field defect describes multiple malformations that occur secondary to an embryonic disturbance in an adjoining group of cells. Holoprosencephaly is a developmental field defect characterized by a spectrum of fetal anomalies due to incomplete division of the forebrain (prosencephalon).

References

©UWorld

Exhibit Display

Holoprosencephaly spectrum

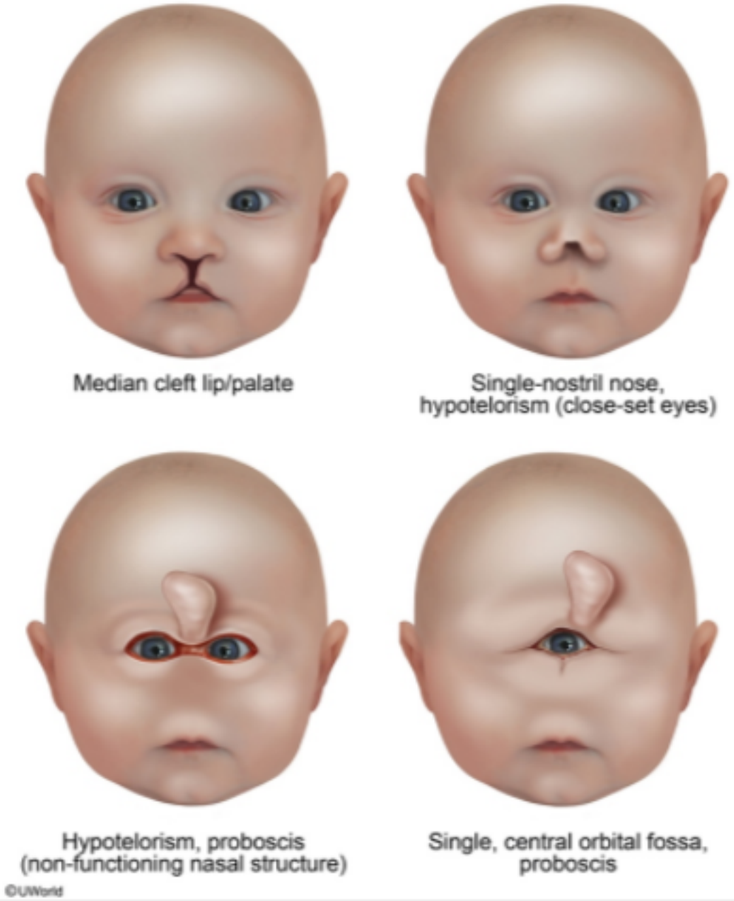

Zoom In | Zoom Out | Reset | Add To New Card | Existing Card

References

proboscis, midfacial clefts).

HPE is likely caused by a combination of genetic (eg, trisomy 13, sonic hedgehog gene mutations) and environmental (eg, maternal alcohol use) factors. It is an example of a **developmental field defect**, which is when an initial embryonic disturbance leads to multiple malformations by disrupting the development of adjacent tissues and structures within a particular region.

(Choice A) Agenesis refers to the complete absence of an organ. Renal agenesis, the congenital absence of one or both kidneys, is an example of this type of abnormality.

(Choice B) An association refers to multiple anomalies without a known unifying cause that occur together more frequently than chance alone would predict. Vertebral defects, anal atresia, cardiac defects, tracheo-esophageal fistula, renal anomalies, and limb abnormalities (VACTERL) are an example of an association of anomalies without a known common etiology.

(Choice C) Deformations are fetal structural anomalies that occur due to extrinsic mechanical forces. The pressure applied by the uterus is one of the most common deforming forces. For example, uterine constraint on a fetus in breech position can cause developmental dysplasia of the hip, a condition marked by abnormal development of the femoral-acetabular junction and subsequent hip instability.

(Choice D) Dysplasia describes abnormal organization of cellular architecture within a tissue. Osteogenesis imperfecta, a skeletal disorder characterized by brittle bones that fracture easily, occurs with dysplasia of connective tissue due to absent or abnormal type I collagen.

Educational objective:
A developmental field defect describes multiple malformations that occur secondary to an embryonic disturbance in an adjoining group of cells. Holoprosencephaly is a developmental field defect characterized by a spectrum of fetal anomalies due to incomplete division of the forebrain (prosencephalon).

References

- Holoprosencephaly: recommendations for diagnosis and management.
- Holoprosencephaly: a survey of the entity, with embryology and fetal imaging.

Embryology Miscellaneous (Multisystem) Holoprosencephaly

It is suggested that some unknown factors may specifically interrupt the normal migration of neural crest cells to the intestine. This migration process is typically complete by the 12th week. If progress is interrupted during the final week of migration, which of the following organs are most likely to be affected?

- A. Duodenum
- B. Jejunum
- C. Ileum
- D. Cecum
- E. Sigmoid colon
- F. Rectum

Submit

It is suggested that some unknown factors may specifically interrupt the normal migration of neural crest cells to the intestine. This migration process is typically complete by the 12th week. If progress is interrupted during the final week of migration, which of the following organs are most likely to be affected?

- A. Duodenum (6%)
- B. Jejunum (2%)
- C. Ileum (8%)
- D. Cecum (5%)
- E. Sigmoid colon (31%)
- ✓ F. Rectum (43%)

Omitted
Correct answer
F

43%
Answered correctly

02 secs
Time Spent

02/03/2020
Last Updated

Explanation

Neural crest cells start migrating to the intestinal wall very early during embryonic development. They give rise to ganglion cells of the submucosal (Meissner) and myenteric (Auerbach) plexi of the bowel wall. These parasympathetic ganglia are responsible for intestinal peristalsis. Neural crest cells move caudally along the vagal nerve fibers. They are present in the wall of proximal colon at 8th week of gestation and in the rectum by 12th week.

Explanation

Neural crest cells start migrating to the intestinal wall very early during embryonic development. They give rise to ganglion cells of the submucosal (Meissner) and myenteric (Auerbach) plexi of the bowel wall. These parasympathetic ganglia are responsible for intestinal peristalsis. Neural crest cells move caudally along the vagal nerve fibers. They are present in the wall of proximal colon at 8th week of gestation and in the rectum by 12th week.

The arrest of migration of neural crest cells causes Hirschsprung disease, in which a segment of colon is deprived of ganglion cells. Since neural crest cells migrate caudally, the rectum is always involved in Hirschsprung disease. The absence of ganglion cells in the colonic wall causes the affected segment to be narrowed because it cannot relax. The passage of intestinal contents through this area is difficult, and compensatory dilatation of proximal areas of the colon occurs.

Newborns with Hirschsprung disease fail to pass meconium within 48 hours of birth. They also demonstrate other symptoms of intestinal obstruction, such as bilious vomiting and abdominal distention. The bowel is filled with stool, but the rectum is empty; the tone of the anal sphincter is usually increased. Rectal biopsy reveals an aganglionic segment of bowel.

(Choices A, B and C) Involvement of the duodenum, jejunum, and ileum is extremely rare, although cases of total intestinal agangliosis have been described.

(Choice D) The cecum is rarely involved in Hirschsprung disease.

(Choice E) The sigmoid colon is involved in Hirschsprung disease in 75% of the cases. The rectum and anus, however, are always involved.

Educational Objective:
Hirschsprung disease is a result of abnormal migration of neural crest cells during embryogenesis. These cells are the precursors of ganglion cells of intestinal wall plexi. Since neural crest cells migrate caudally, the rectum is always affected in Hirschsprung disease.

Embryology	Gastrointestinal & Nutrition	Hirschsprung's disease
Subject	System	Topic

Copyright © UWorld. All rights reserved.

A 3-day-old boy is brought to the emergency department due to poor feeding, emesis, and lethargy over the last 24 hours. The patient was born via uncomplicated spontaneous vaginal delivery to a 30-year-old woman who had a normal pregnancy. The boy was discharged from the newborn nursery yesterday and was breastfeeding exclusively until the onset of symptoms. Stool and urine output were normal while he was in the newborn nursery. The patient is afebrile and normotensive but tachycardic and tachypneic. He appears dehydrated, and the abdomen is distended. The patient vomits during the examination, and the vomitus is shown in the exhibit. On laparotomy, fibrous bands are seen extending from the cecum and right colon to the retroperitoneum, causing extrinsic compression of the duodenum. Which of the following embryologic processes most likely failed in this patient?

A. Failure of gut recanalization

B. Fusion of the ventral and dorsal pancreatic buds

C. Midgut rotation around the superior mesenteric artery

D. Neural crest cell migration into the bowel wall

E. Obliteration of the omphalomesenteric duct

Submit

Settings

1 2 3 4 5 6 7 8 9 10 11 12 13 14 15 16 17 18 19 20 21 22 23 24 25 26 27 28 29 30

Item 36 of 40
Question Id: 318

Mark | Previous | Next | Full Screen | Tutorial | Lab Values | Notes | Calculator | Reverse Color | Text Zoom | Settings

Exhibit Display



Zoom In | Zoom Out | Reset | Add To New Card | Existing Card

Block Time Remaining: 00:01:27
TUTOR

5 | Feedback | Suspend | End Block

A 3-day-old boy is brought to the emergency department due to poor feeding, emesis, and lethargy over the last 24 hours. The patient was born via uncomplicated spontaneous vaginal delivery to a 30-year-old woman who had a normal pregnancy. The boy was discharged from the newborn nursery yesterday and was breastfeeding exclusively until the onset of symptoms. Stool and urine output were normal while he was in the newborn nursery. The patient is afebrile and normotensive but tachycardic and tachypneic. He appears dehydrated, and the abdomen is distended. The patient vomits during the examination, and the vomitus is shown in the exhibit. On laparotomy, fibrous bands are seen extending from the cecum and right colon to the retroperitoneum, causing extrinsic compression of the duodenum. Which of the following embryologic processes most likely failed in this patient?

- A. Failure of gut recanalization (14%)
- B. Fusion of the ventral and dorsal pancreatic buds (9%)
- ✓ C. Midgut rotation around the superior mesenteric artery (53%)
- D. Neural crest cell migration into the bowel wall (4%)
- E. Obliteration of the omphalomesenteric duct (17%)

Omitted
Correct answer
C

53%
Answered correctly

09 secs
Time Spent

03/17/2020
Last Updated

Explanation

Around 6 weeks gestation, the midgut (supplied by the superior mesenteric artery) herniates through the umbilical ring in order to grow rapidly. During this process, the midgut rotates 90 degrees counterclockwise. Following additional growth, the midgut returns to the abdominal cavity at 8-10 weeks gestation and turns an additional 180 degrees counterclockwise (270 degrees total). Subsequently, the gut is fixed to the posterior

Explanation

Around 6 weeks gestation, the midgut (supplied by the superior mesenteric artery) herniates through the umbilical ring in order to grow rapidly. During this process, the midgut rotates 90 degrees counterclockwise. Following additional growth, the midgut returns to the abdominal cavity at 8-10 weeks gestation and turns an additional 180 degrees counterclockwise (270 degrees total). Subsequently, the gut is fixed to the posterior abdomen on a wide-based mesentery.

Incomplete counterclockwise rotation (eg, 180 degrees) will result in **midgut malrotation**. The cecum will rest in the right upper quadrant instead of the right lower quadrant (RLQ). Additionally, **Ladd's (fibrous) bands** connect the retroperitoneum in the RLQ to the right colon/cecum by passing over the second part of the duodenum, causing **intestinal obstruction** in the process. Obstruction manifests as bilious emesis during the first days of life. In addition, because the mesenteric base is abnormally narrowed, the mesentery is vulnerable to twisting around the **superior mesenteric artery**. The twisting, referred to as midgut volvulus, compromises intestinal perfusion and may lead to life-threatening bowel necrosis.

(Choice A) Failure of gut recanalization is a possible mechanism for development of duodenal atresia (distension of stomach and duodenum on X-ray). Ladd's bands are not found in this condition.

(Choice B) Failure of ventral and dorsal pancreatic buds to fuse at 8 weeks gestation results in pancreas divisum. However, this condition is usually asymptomatic and an incidental finding on imaging study or autopsy.

(Choice D) Failure of neural crest cell migration in the gut causes aganglionic sigmoid colon/rectum. The affected bowel segments cannot relax and are therefore narrow and obstructive. Hirschsprung disease presents in the neonatal period with delayed passage of meconium, abdominal distension, and bilious emesis.

(Choice E) The omphalomesenteric duct connects the midgut lumen with the yolk sac. Failed obliteration of the duct causes vitelline fistula (complete failure) or a Meckel diverticulum (partial failure). If symptomatic, Meckel diverticulum most commonly presents with painless lower gastrointestinal bleeding without emesis.

Educational objective:
Intestinal malrotation results when the midgut undergoes incomplete embryological counterclockwise rotation. It can present as intestinal obstruction (due to compression by the adhesive bands) and midgut volvulus (intestinal ischemia due to twisting around the blood vessels).

of the right lower quadrant (RLQ). Additionally, **Ladd's (fibrous) bands** connect the retroperitoneum in the RLQ to the right colon/cecum by passing over the second part of the duodenum, causing **intestinal obstruction** in the process. Obstruction manifests as bilious emesis during the first days of life. In addition, because the mesenteric base is abnormally narrowed, the mesentery is vulnerable to twisting around the **superior mesenteric artery**. The twisting, referred to as midgut volvulus, compromises intestinal perfusion and may lead to life-threatening bowel necrosis.

(Choice A) Failure of gut recanalization is a possible mechanism for development of duodenal atresia (distension of stomach and duodenum on X-ray). Ladd's bands are not found in this condition.

(Choice B) Failure of ventral and dorsal pancreatic buds to fuse at 8 weeks gestation results in pancreas divisum. However, this condition is usually asymptomatic and an incidental finding on imaging study or autopsy.

(Choice D) Failure of neural crest cell migration in the gut causes aganglionic sigmoid colon/rectum. The affected bowel segments cannot relax and are therefore narrow and obstructive. Hirschsprung disease presents in the neonatal period with delayed passage of meconium, abdominal distension, and bilious emesis.

(Choice E) The omphalomesenteric duct connects the midgut lumen with the yolk sac. Failed obliteration of the duct causes vitelline fistula (complete failure) or a Meckel diverticulum (partial failure). If symptomatic, Meckel diverticulum most commonly presents with painless lower gastrointestinal bleeding without emesis.

Educational objective:
Intestinal malrotation results when the midgut undergoes incomplete embryological counterclockwise rotation. It can present as intestinal obstruction (due to compression by the adhesive bands) and midgut volvulus (intestinal ischemia due to twisting around the blood vessels).

References

- Intestinal malrotation and catastrophic volvulus in infancy

Embryology	Gastrointestinal & Nutrition	Intestinal malrotation
Subject	System	Topic

Copyright © UWorld. All rights reserved.

of the right lower quadrant (RLQ). Additionally, **Ladd's (fibrous) bands** connect the retroperitoneum in the RLQ to the right colon/cecum by passing over the second part of the duodenum, causing **intestinal obstruction** in the process. Obstruction manifests as bilious emesis during the first days of life. In addition, because the mesenteric base is abnormally narrowed, the mesentery is vulnerable to twisting around the **superior mesenteric artery**. The twisting, referred to as midgut volvulus, compromises intestinal perfusion and may lead to life-threatening bowel necrosis.

(Choice A) Failure of gut recanalization is a possible mechanism for development of duodenal atresia (distension of stomach and duodenum on X-ray). Ladd's bands are not found in this condition.

(Choice B) Failure of ventral and dorsal pancreatic buds to fuse at 8 weeks gestation results in pancreas divisum. However, this condition is usually asymptomatic and an incidental finding on imaging study or autopsy.

(Choice D) Failure of neural crest cell migration in the gut causes aganglionic sigmoid colon/rectum. The affected bowel segments cannot relax and are therefore narrow and obstructive. Hirschsprung disease presents in the neonatal period with delayed passage of meconium, abdominal distension, and bilious emesis.

(Choice E) The omphalomesenteric duct connects the midgut lumen with the yolk sac. Failed obliteration of the duct causes vitelline fistula (complete failure) or a Meckel diverticulum (partial failure). If symptomatic, Meckel diverticulum most commonly presents with painless lower gastrointestinal bleeding without emesis.

Educational objective:
Intestinal malrotation results when the midgut undergoes incomplete embryological counterclockwise rotation. It can present as intestinal obstruction (due to compression by the adhesive bands) and midgut volvulus (intestinal ischemia due to twisting around the blood vessels).

References

- Intestinal malrotation and catastrophic volvulus in infancy

Embryology	Gastrointestinal & Nutrition	Intestinal malrotation
Subject	System	Topic

Copyright © UWorld. All rights reserved.

Settings

1 2 3 4 5 6 7 8 9 10 11 12 13 14 15 16 17 18 19 20 21 22 23 24 25 26 27 28 29 30

Item 36 of 40
Question Id: 318

Mark | Previous | Next | Full Screen | Tutorial | Lab Values | Notes | Calculator | Reverse Color | Text Zoom | Settings

Omitted

Exhibit Display

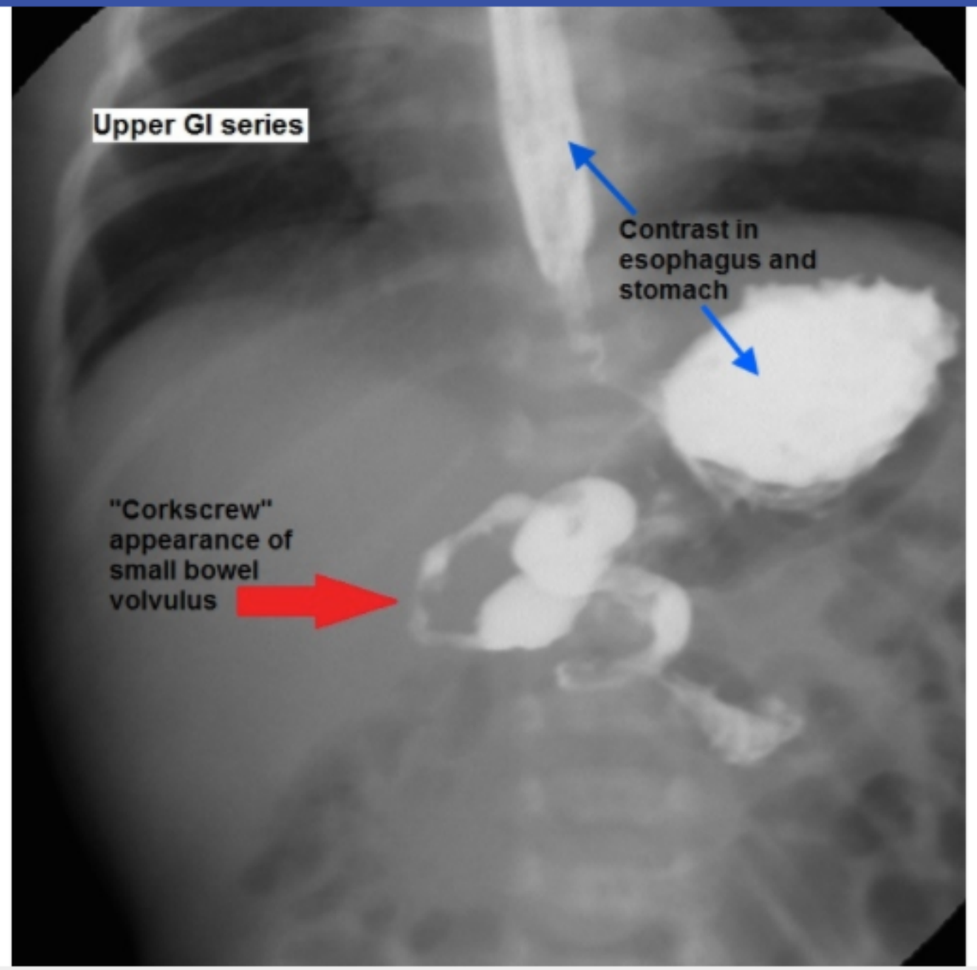

Zoom In | Zoom Out | Reset | Add To New Card | Existing Card

(complete failure) or a Meckel diverticulum (partial failure). If symptomatic, Meckel diverticulum most commonly presents with painless lower

Block Time Remaining: 00:01:32
TUTOR

5 | Feedback | Suspend | End Block

Settings

1 2 3 4 5 6 7 8 9 10 11 12 13 14 15 16 17 18 19 20 21 22 23 24 25 26 27 28 29 30

Item 36 of 40
Question Id: 318

Mark | Previous | Next | Full Screen | Tutorial | Lab Values | Notes | Calculator | Reverse Color | Text Zoom | Settings

Omitted

Exhibit Display

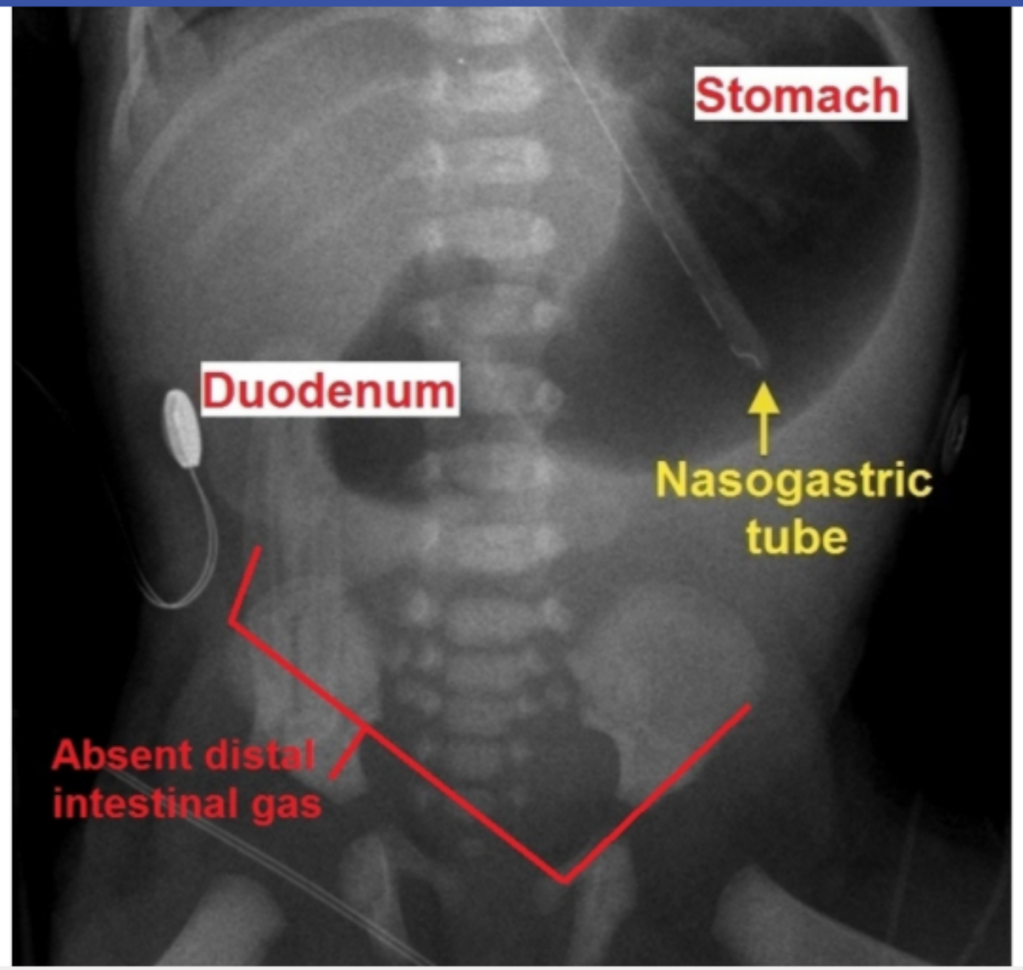

Zoom In | Zoom Out | Reset | Add To New Card | Existing Card

(complete failure) or a Meckel diverticulum (partial failure). If symptomatic, Meckel diverticulum most commonly presents with painless lower

Block Time Remaining: 00:01:32
TUTOR

5 | Feedback | Suspend | End Block

of the right lower quadrant (RLQ). Additionally, **Ladd's (fibrous) bands** connect the retroperitoneum in the RLQ to the right colon/cecum by

Exhibit Display

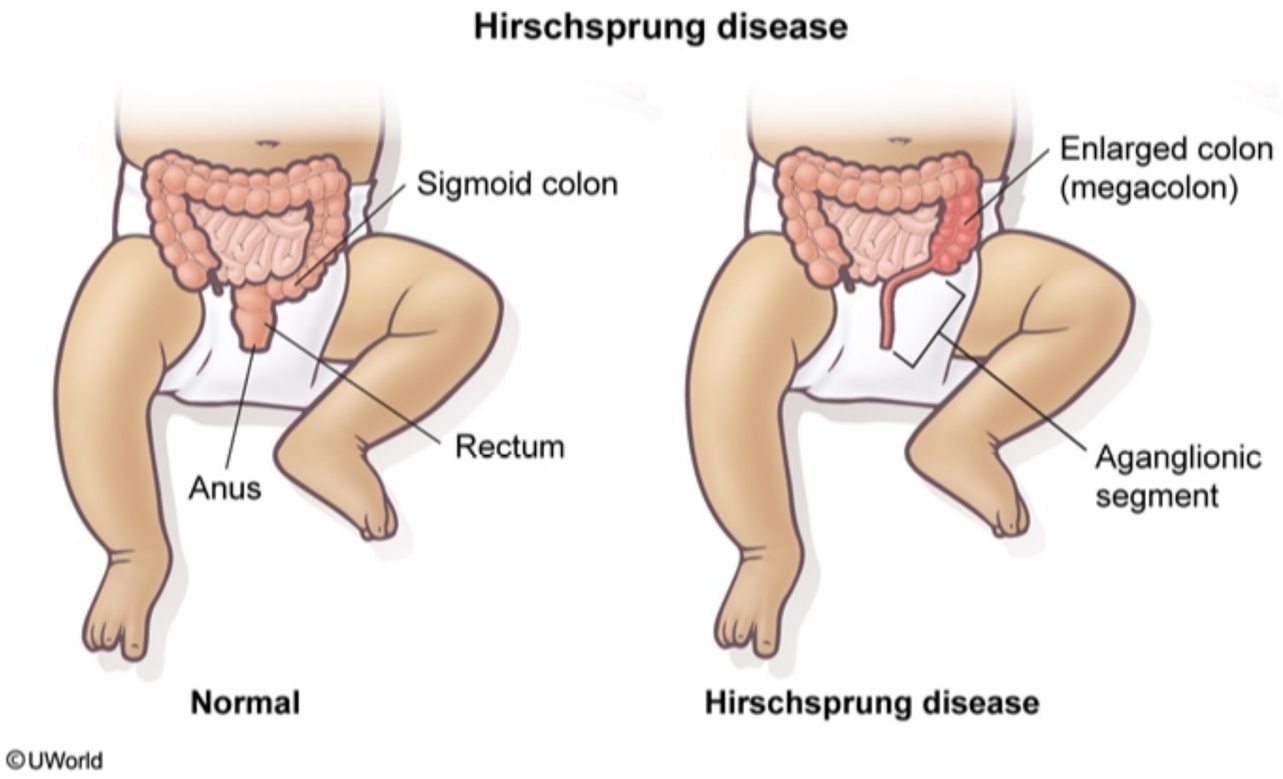

Zoom In | Zoom Out | Reset | Add To New Card | Existing Card

of the right lower quadrant (RLQ). Additionally, **Ladd's (fibrous) bands** connect the retroperitoneum in the RLQ to the right colon/cecum by

Exhibit Display

Vitelline duct abnormalities

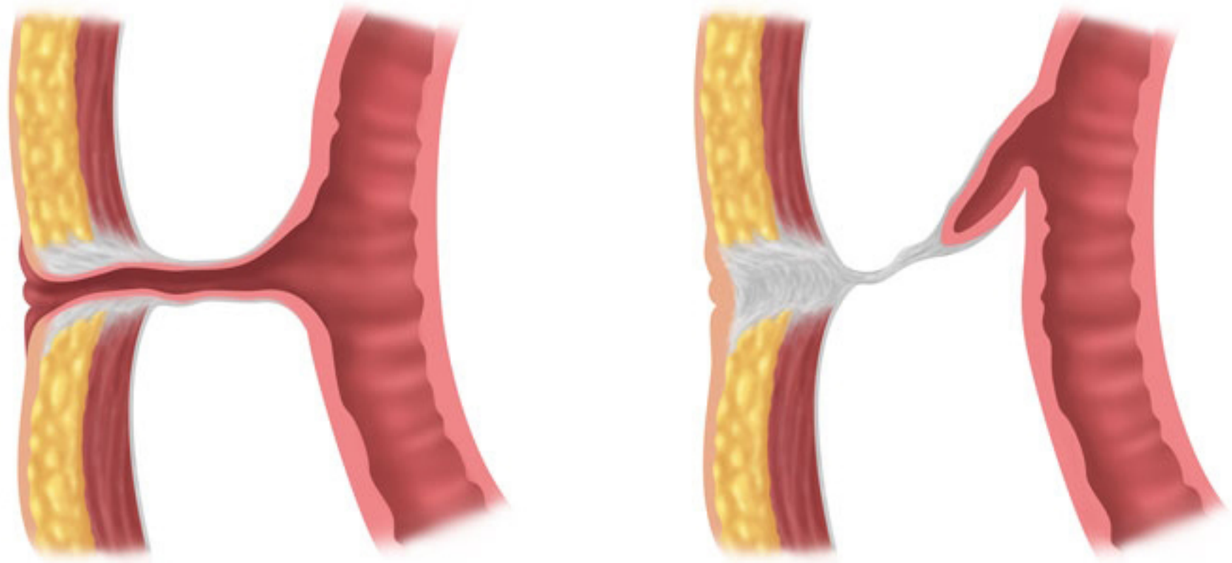

Persistent vitelline duct

Meckel diverticulum

©UWorld

Zoom In | Zoom Out | Reset | Add To New Card | Existing Card

A 33-year-old man comes to the office due to episodic headaches for several months accompanied by sweating and feelings of anxiety that spontaneously resolve after 15-30 minutes. He has no other medical conditions and takes no medications. His brother recently had surgery to treat hyperparathyroidism. Blood pressure is 180/110 mm Hg, and pulse is 102/min. Laboratory results show normal serum electrolytes and renal function. CT scan of the abdomen reveals a mass in the right adrenal gland. Which of the following cells have the same embryological origin as the tissue responsible for this patient's current condition?

A. Capillary endothelial cells

B. Cardiac myocytes

C. Interstitial fibroblasts

D. Melanin-producing cells

E. Thyroid follicular cells

Submit

A 33-year-old man comes to the office due to episodic headaches for several months accompanied by sweating and feelings of anxiety that spontaneously resolve after 15-30 minutes. He has no other medical conditions and takes no medications. His brother recently had surgery to treat hyperparathyroidism. Blood pressure is 180/110 mm Hg, and pulse is 102/min. Laboratory results show normal serum electrolytes and renal function. CT scan of the abdomen reveals a mass in the right adrenal gland. Which of the following cells have the same embryological origin as the tissue responsible for this patient's current condition?

- A. Capillary endothelial cells (1%)
- B. Cardiac myocytes (2%)
- C. Interstitial fibroblasts (0%)
- ✓ D. Melanin-producing cells (80%)
- E. Thyroid follicular cells (14%)

Omitted
Correct answer
D

80%
Answered correctly

02 secs
Time Spent

05/28/2020
Last Updated

Explanation

Embryological derivatives		
		• Anterior pituitary (Rathke pouch)

Embryological derivatives		
Ectoderm	Surface ectoderm	• Anterior pituitary (Rathke pouch) • Lens & cornea • Inner ear sensory organs, olfactory epithelium • Nasal & oral epithelial linings, salivary glands • Epidermis, sweat & mammary glands
	Neural tube	• Brain & spinal cord • Posterior pituitary, pineal gland • Retina
	Neural crest	• Neural ganglia, adrenal medulla • Schwann cells; pia & arachnoid mater • Aorticopulmonary septum & endocardial cushions • Branchial arches (bones & cartilage) • Skull bones • Melanocytes
Mesoderm		• Muscles (skeletal, cardiac & smooth) • Connective tissue, bone & cartilage • Serosal linings (eg, peritoneum) • Cardiovascular & lymphatic system • Spleen & hemopoietic cells • Kidney & ureters, internal genitalia • Adrenal cortex
		• Gastrointestinal tract, liver, pancreas

	• Melanocytes
Mesoderm	• Muscles (skeletal, cardiac & smooth) • Connective tissue, bone & cartilage • Serosal linings (eg, peritoneum) • Cardiovascular & lymphatic system • Spleen & hemopoietic cells • Kidney & ureters, internal genitalia • Adrenal cortex
Endoderm	• Gastrointestinal tract, liver, pancreas • Lungs • Thymus, parathyroids, thyroid follicular cells • Middle ear epithelium • Bladder & urethra • Parafollicular (C) cells*

*Formerly thought to be of neural crest origin.

This patient with severe hypertension, headaches, and an adrenal mass has typical features of **pheochromocytoma**, a catecholamine-secreting tumor of the chromaffin cells of the adrenal medulla. Pheochromocytoma can be sporadic or associated with several familial disorders, especially **multiple endocrine neoplasia (MEN) type 2** (particularly likely in this patient given his family history of hyperparathyroidism). MEN type 2 is associated with germ-line mutations in the *RET* proto-oncogene and is characterized by:

- Pheochromocytomas
- Medullary thyroid cancer (malignancy of parafollicular C cells)
- Either parathyroid hyperplasia (MEN 2A) or mucosal neuromas and marfanoid habitus (MEN 2B)

Neural crests are embryological structures composed of parallel strips of cells arising from the ectoderm at the margin of the neural tube. The chromaffin cells of the **adrenal medulla** are derived from neural crest tissue (the adrenal cortex is derived from the mesoderm). Structures arising

This patient with severe hypertension, headaches, and an adrenal mass has typical features of **pheochromocytoma**, a catecholamine-secreting tumor of the chromaffin cells of the adrenal medulla. Pheochromocytoma can be sporadic or associated with several familial disorders, especially **multiple endocrine neoplasia (MEN) type 2** (particularly likely in this patient given his family history of hyperparathyroidism). MEN type 2 is associated with germ-line mutations in the *RET* proto-oncogene and is characterized by:

- Pheochromocytomas
- Medullary thyroid cancer (malignancy of parafollicular C cells)
- Either parathyroid hyperplasia (MEN 2A) or mucosal neuromas and marfanoid habitus (MEN 2B)

Neural crests are embryological structures composed of parallel strips of cells arising from the ectoderm at the margin of the neural tube. The chromaffin cells of the **adrenal medulla** are derived from neural crest tissue (the adrenal cortex is derived from the mesoderm). Structures arising from neural crest cells can be remembered with the mnemonic "SOME SALT" (Schwann cells, odontoblasts, **melanocytes**, enterochromaffin cells, spinal membranes [pia and arachnoid], **adrenal medulla**/ganglia, laryngeal cartilage, tracheal cartilage).

(Choices A, B, and C) Capillary endothelial cells and cardiac myocytes are mesodermal derivatives that arise from primitive endothelium. Interstitial fibroblasts also arise from the mesoderm.

(Choice E) Thyroid follicular cells are an endodermal derivative, arising from the pharyngeal epithelium at the base of the tongue. Although the parafollicular, calcitonin-secreting C cells were previously thought to originate from neural crest tissue, recent studies suggest that they have an endodermal origin.

Educational objective:
Neural crests are embryological structures composed of parallel strips of cells arising from the ectoderm at the margin of the neural tube. Structures derived from neural crest cells include Schwann cells, odontoblasts, melanocytes, enterochromaffin cells, spinal membranes, adrenal medulla/ganglia, laryngeal cartilage, and tracheal cartilage.

References

- Familial pheochromocytomas and paragangliomas.
- The neural crest: a versatile organ system.

Formerly thought to be of neural crest origin.

Exhibit Display

Neural tube formation

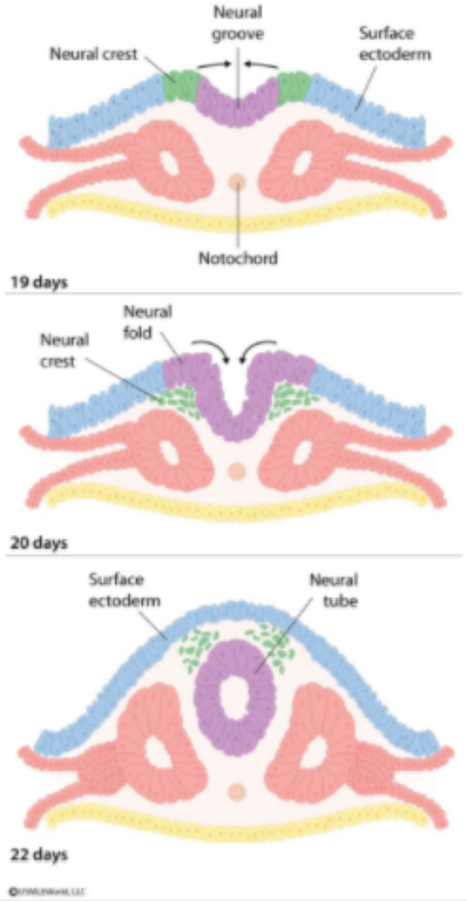

Zoom In | Zoom Out | Reset | Add To New Card | Existing Card

- The neural crest: a versatile organ system.

- Pheochromocytomas
- Medullary thyroid cancer (malignancy of parafollicular C cells)
- Either parathyroid hyperplasia (MEN 2A) or mucosal neuromas and marfanoid habitus (MEN 2B)

Neural crests are embryological structures composed of parallel strips of cells arising from the ectoderm at the margin of the neural tube. The chromaffin cells of the **adrenal medulla** are derived from neural crest tissue (the adrenal cortex is derived from the mesoderm). Structures arising from neural crest cells can be remembered with the mnemonic "SOME SALT" (Schwann cells, odontoblasts, **melanocytes**, enterochromaffin cells, spinal membranes [pia and arachnoid], **adrenal medulla**/ganglia, laryngeal cartilage, tracheal cartilage).

(Choices A, B, and C) Capillary endothelial cells and cardiac myocytes are mesodermal derivatives that arise from primitive endothelium. Interstitial fibroblasts also arise from the mesoderm.

(Choice E) Thyroid follicular cells are an endodermal derivative, arising from the pharyngeal epithelium at the base of the tongue. Although the parafollicular, calcitonin-secreting C cells were previously thought to originate from neural crest tissue, recent studies suggest that they have an endodermal origin.

Educational objective:
Neural crests are embryological structures composed of parallel strips of cells arising from the ectoderm at the margin of the neural tube. Structures derived from neural crest cells include Schwann cells, odontoblasts, melanocytes, enterochromaffin cells, spinal membranes, adrenal medulla/ganglia, laryngeal cartilage, and tracheal cartilage.

References

- Familial pheochromocytomas and paragangliomas.
- The neural crest: a versatile organ system.

Embryology	Endocrine, Diabetes & Metabolism	Pheochromocytoma
Subject	System	Topic

Copyright © UWorld. All rights reserved.

A 25-year-old woman, gravida 4, para 0, comes to the office for evaluation of recurrent pregnancy loss. She has had 4 second-trimester losses with the same partner. The patient has menstrual cycles approximately 28 days with light bleeding for 2-3 days. Her past medical history is significant for left renal agenesis. Family history is negative for recurrent pregnancy loss. Laboratory studies are negative for anticardiolipin antibodies and lupus anticoagulant. Results of the patient's hysterosalpingogram are shown exhibit. Based on her evaluation, a pelvic MRI is ordered and shows an abnormal contour to the uterine fundus. Failure of which of the following process is the most likely underlying mechanism of this patient's condition?

- A. Development of the paramesonephric ducts
- B. Fusion of the mesonephric ducts
- C. Involution of the paramesonephric ducts
- D. Lateral fusion of the paramesonephric ducts
- E. Vertical fusion with the urogenital sinus

Submit

A 25-year-old woman, gravida 4, para 0, comes to the office for evaluation of recurrent pregnancy loss. She has had 4 second-trimester losses with the same partner. The patient has menstrual cycles approximately 28 days with light bleeding for 2-3 days. Her past medical history is significant for left renal agenesis. Family history is negative for recurrent pregnancy loss. Laboratory studies are negative for anticardiolipin antibodies and lupus anticoagulant. Results of the patient's hysterosalpingogram are shown exhibit. Based on her evaluation, a pelvic MRI is ordered and shows an abnormal contour to the uterine fundus. Failure of which of the following process is the most likely underlying mechanism of this patient's condition?

- A. Development of the paramesonephric ducts (9%)
- B. Fusion of the mesonephric ducts (18%)
- C. Involution of the paramesonephric ducts (10%)
- ✓ D. Lateral fusion of the paramesonephric ducts (56%)
- E. Vertical fusion with the urogenital sinus (5%)

Omitted
Correct answer
D

56%
Answered correctly

02 secs
Time Spent

06/14/2020
Last Updated

Explanation

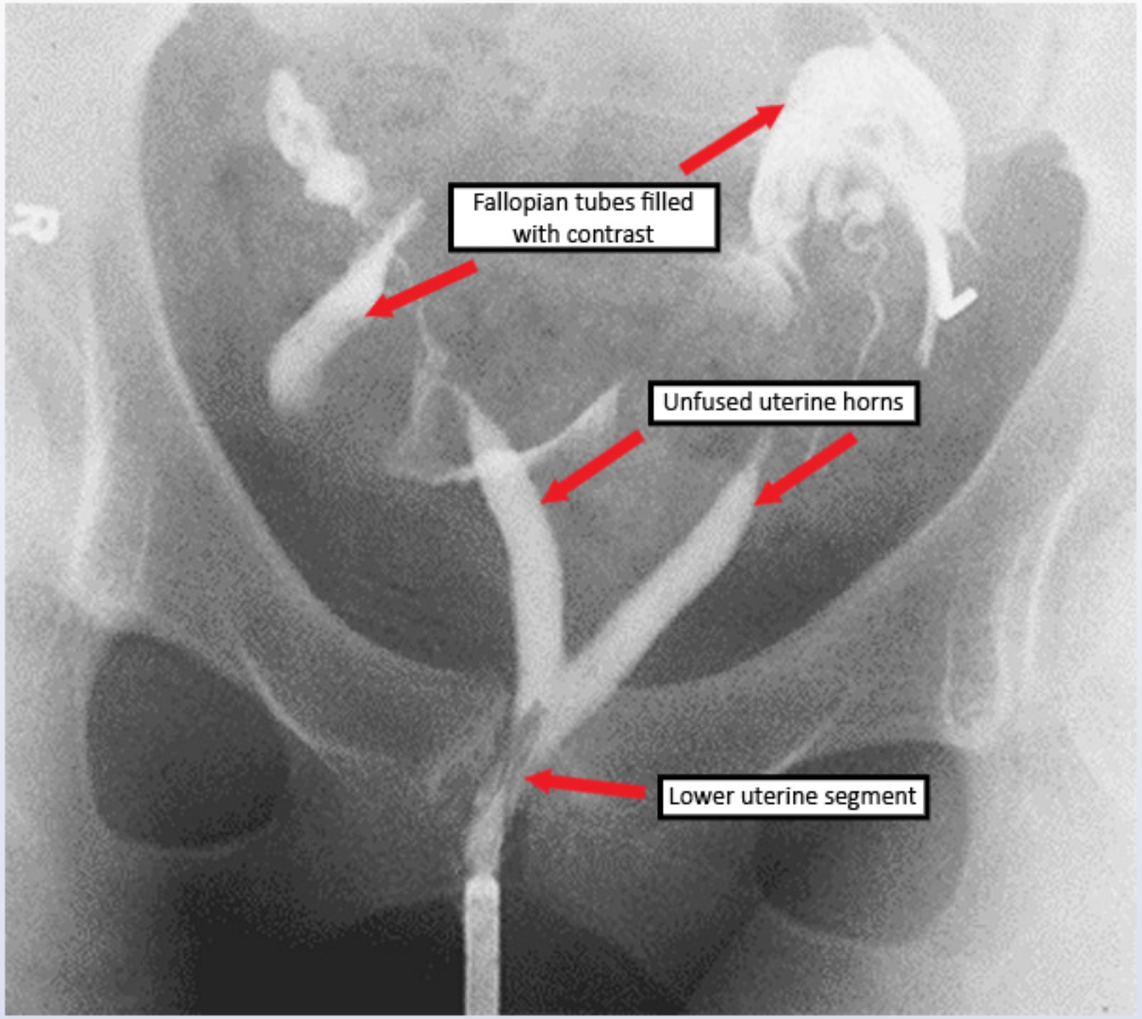

Female reproductive tract development involves lateral/vertical fusion and involution of the **paramesonephric ducts (eg, müllerian ducts)**, which give rise to the fallopian tubes, uterus, cervix, and upper vagina. Development of the paramesonephric and mesonephric ducts is closely linked;

Female reproductive tract development involves lateral/vertical fusion and involution of the **paramesonephric ducts (eg, müllerian ducts)**, which give rise to the fallopian tubes, uterus, cervix, and upper vagina. Development of the paramesonephric and mesonephric ducts is closely linked; therefore, uterine anomalies often coexist with **renal anomalies** (eg, unilateral renal agenesis).

Failed lateral fusion of the paramesonephric ducts can result in various anomalies. Incomplete lateral fusion of the upper segments can result in a **bicornuate** uterus characterized by an **indentation in the center of the fundus**. Complete lack of fusion can lead to uterine didelphys (double uterus and cervix). Failed involution of the paramesonephric ducts can result in a longitudinal uterine septum.

When a patient has difficulty conceiving or **recurrent pregnancy loss**, structural uterine anomalies can be screened by **hysterosalpingogram (HSG)**, which involves contrast injection through the cervix into the uterus with a concurrent pelvic x-ray. This patient's HSG shows 2 **unfused uterine horns** with a central filling defect, which can represent a bicornuate uterus or a longitudinal uterine septum **(Choice C)**. **MRI** can distinguish these 2 anomalies as a septate uterus has a normal outer uterine contour.

(Choice A) Complete agenesis of the paramesonephric ducts leads to Mayer-Rokitansky-Küster-Hauser syndrome. The lower vagina originates from the urogenital sinus, and affected patients would experience infertility due to a blind vaginal pouch and lack of müllerian structures.

(Choice B) The mesonephric ducts (eg, wolffian ducts) do not fuse during embryonic development. In females, the mesonephric ducts form Gartner ducts. In males, they form the epididymis, ductus deferens, seminal vesicles, and ejaculatory ducts.

(Choice E) A transverse vaginal septum is an example of failed vertical fusion of the paramesonephric ducts with the urogenital sinus. The obstructive septum causes primary amenorrhea with cyclic pelvic pain from hematometra (menses retained in the uterus), and an HSG cannot be performed on these patients.

Educational objective:
In females, the paramesonephric ducts fuse to form the fallopian tubes, uterus, cervix, and upper vagina. Disruptions of this process can lead to a variety of müllerian tract anomalies, and renal anomalies are a common comorbidity. Incomplete lateral fusion of the paramesonephric ducts results in a bicornuate uterus characterized by an indentation in the center of the fundus.

References

Settings

1 2 3 4 5 6 7 8 9 10 11 12 13 14 15 16 17 18 19 20 21 22 23 24 25 26 27 28 29 30

Item 38 of 40
Question Id: 1831

Mark | Previous | Next | Full Screen | Tutorial | Lab Values | Notes | Calculator | Reverse Color | Text Zoom | Settings

Exhibit Display

Kidney development

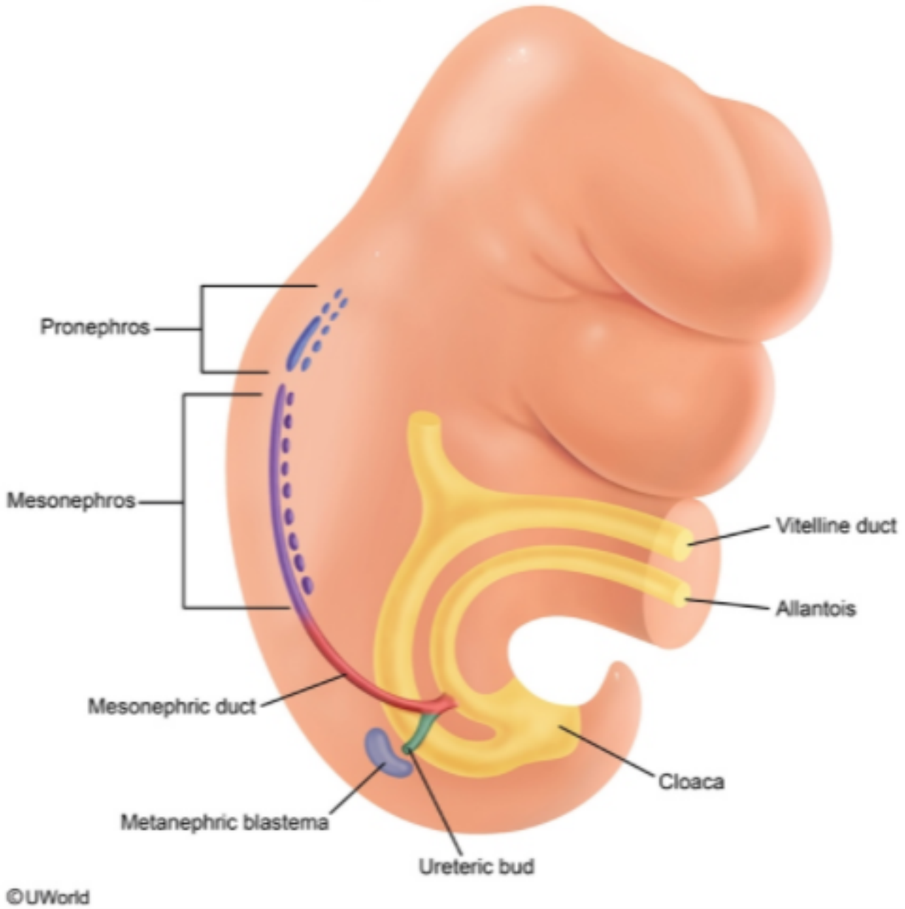

Zoom In | Zoom Out | Reset | Add To New Card | Existing Card

References

Block Time Remaining: 00:01:36
TUTOR

4 | Feedback | Suspend | End Block

Settings

1 2 3 4 5 6 7 8 9 10 11 12 13 14 15 16 17 18 19 20 21 22 23 24 25 26 27 28 29 30

Item 38 of 40
Question Id: 1831

Mark | Previous | Next | Full Screen | Tutorial | Lab Values | Notes | Calculator | Reverse Color | Text Zoom | Settings

Exhibit Display

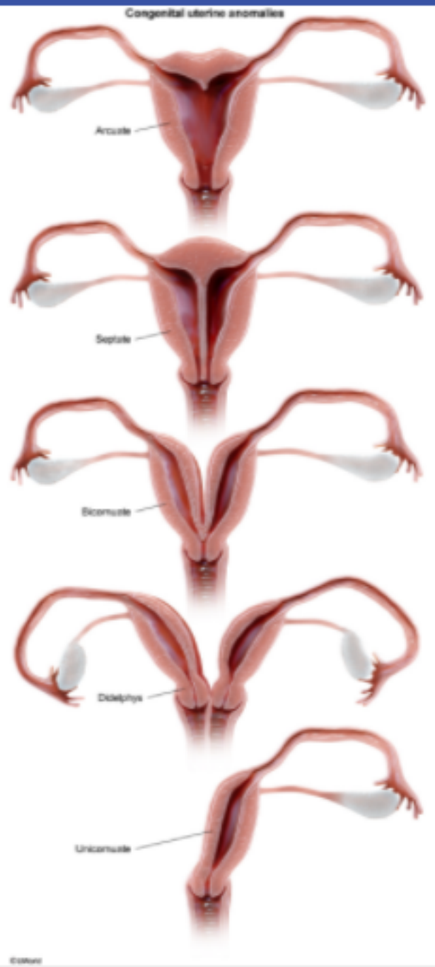

Zoom In | Zoom Out | Reset | Add To New Card | Existing Card

References

Block Time Remaining: 00:01:36
TUTOR

4 | Feedback | Suspend | End Block

Settings

1 2 3 4 5 6 7 8 9 10 11 12 13 14 15 16 17 18 19 20 21 22 23 24 25 26 27 28 29 30

Item 38 of 40
Question Id: 1831

Mark | Previous | Next | Full Screen | Tutorial | Lab Values | Notes | Calculator | Reverse Color | Text Zoom | Settings

Exhibit Display

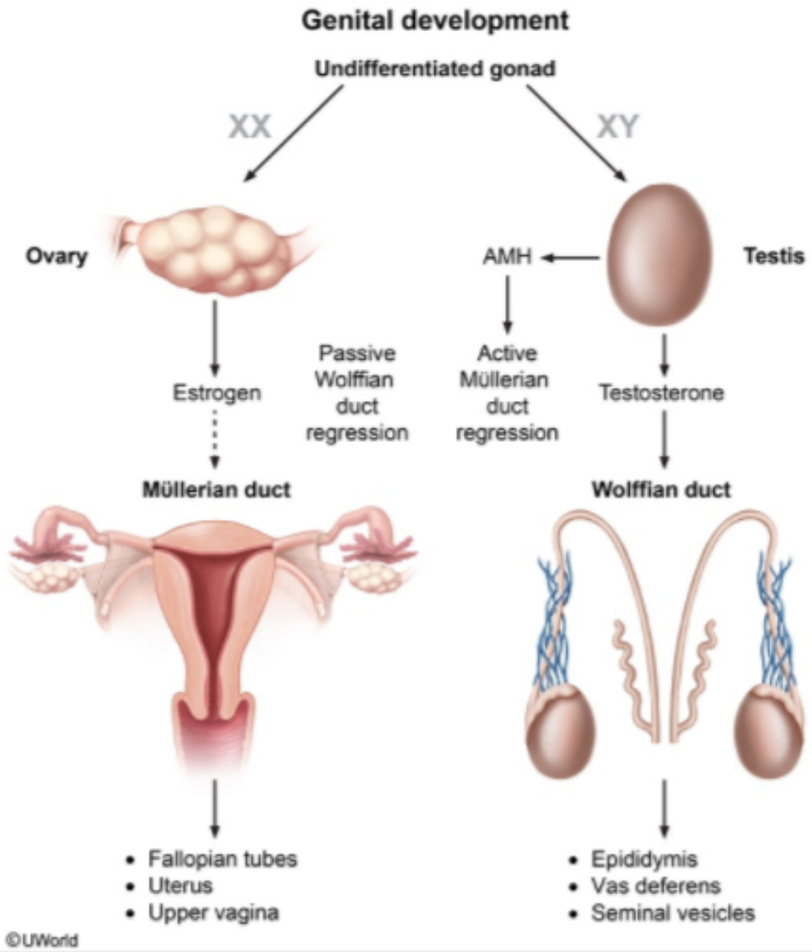

Zoom In | Zoom Out | Reset | Add To New Card | Existing Card

References

Block Time Remaining: 00:01:36
TUTOR

4 | Feedback | Suspend | End Block

When a patient has difficulty conceiving or **recurrent pregnancy loss**, structural uterine anomalies can be screened by **hysterosalpingogram (HSG)**, which involves contrast injection through the cervix into the uterus with a concurrent pelvic x-ray. This patient's HSG shows 2 **unfused uterine horns** with a central filling defect, which can represent a bicornuate uterus or a longitudinal uterine septum **(Choice C)**. **MRI** can distinguish these 2 anomalies as a septate uterus has a normal outer uterine contour.

(Choice A) Complete agenesis of the paramesonephric ducts leads to Mayer-Rokitansky-Küster-Hauser syndrome. The lower vagina originates from the urogenital sinus, and affected patients would experience infertility due to a blind vaginal pouch and lack of müllerian structures.

(Choice B) The mesonephric ducts (eg, wolffian ducts) do not fuse during embryonic development. In females, the mesonephric ducts form Gartner ducts. In males, they form the epididymis, ductus deferens, seminal vesicles, and ejaculatory ducts.

(Choice E) A transverse vaginal septum is an example of failed vertical fusion of the paramesonephric ducts with the urogenital sinus. The obstructive septum causes primary amenorrhea with cyclic pelvic pain from hematometra (menses retained in the uterus), and an HSG cannot be performed on these patients.

Educational objective:
In females, the paramesonephric ducts fuse to form the fallopian tubes, uterus, cervix, and upper vagina. Disruptions of this process can lead to a variety of müllerian tract anomalies, and renal anomalies are a common comorbidity. Incomplete lateral fusion of the paramesonephric ducts results in a bicornuate uterus characterized by an indentation in the center of the fundus.

References

- Müllerian duct anomalies: Embryological development, classification, and MRI assessment.
- Unilateral renal agenesis and female genital tract pathologies.

Embryology	Female Reproductive System & Breast	Mullerian anomaly
Subject	System	Topic

Copyright © UWorld. All rights reserved.

A newborn girl is evaluated in the neonatal intensive care unit for difficulty breathing. The patient was born at term via spontaneous vaginal delivery. Since birth, she has had difficulty breathing with loud snoring sounds and intermittent oxygen desaturations. She has been unable to breastfeed due to her breathing problems. Breathing improves significantly when the patient is placed in a prone position. On examination, there is a small mandible, posteriorly displaced tongue, and U-shaped cleft palate. The abnormalities described represent an example of which of the following?

- A. Association
- B. Disruption
- C. Imprinting
- D. Sequence
- E. Syndrome

Submit

A newborn girl is evaluated in the neonatal intensive care unit for difficulty breathing. The patient was born at term via spontaneous vaginal delivery. Since birth, she has had difficulty breathing with loud snoring sounds and intermittent oxygen desaturations. She has been unable to breastfeed due to her breathing problems. Breathing improves significantly when the patient is placed in a prone position. On examination, there is a small mandible, posteriorly displaced tongue, and U-shaped cleft palate. The abnormalities described represent an example of which of the following?

- A. Association (6%)
- B. Disruption (15%)
- C. Imprinting (1%)
- ✓ D. Sequence (35%)
- E. Syndrome (41%)

Omitted
Correct answer
D

35%
Answered correctly

02 secs
Time Spent

05/07/2020
Last Updated

Explanation

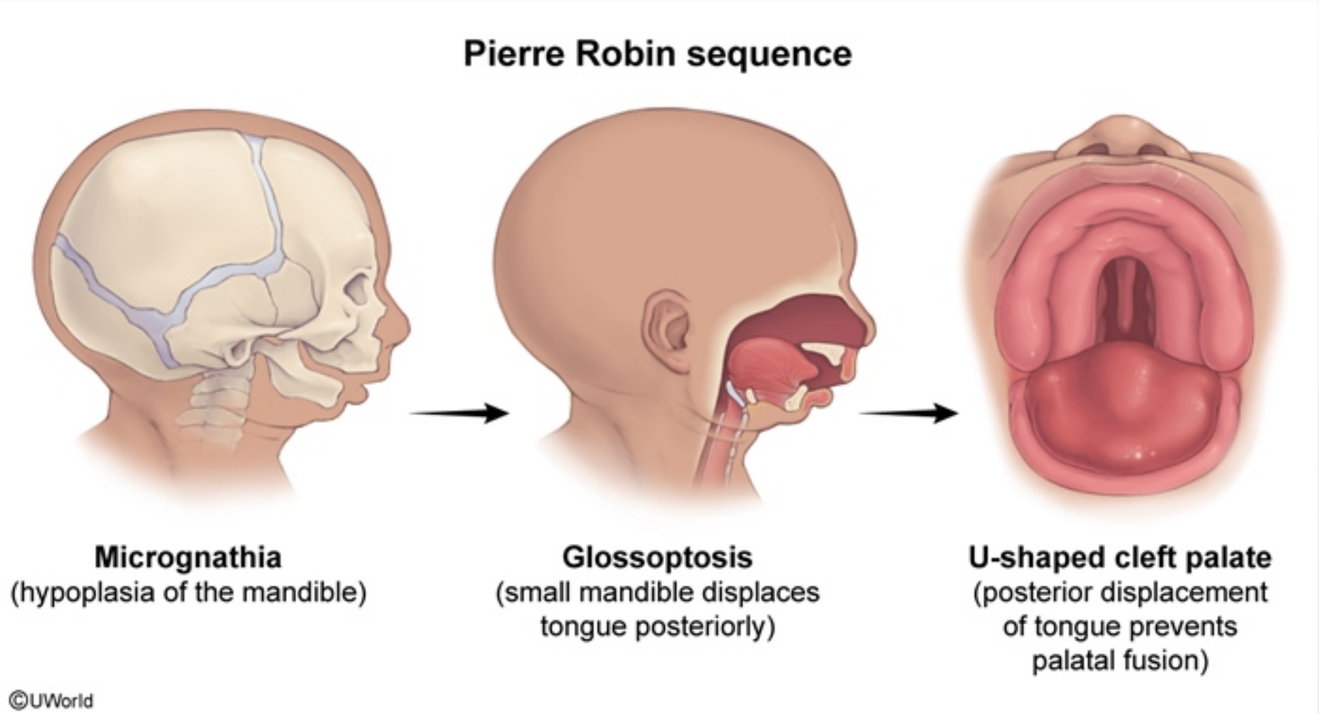

This patient has a small mandible, posteriorly displaced tongue, and U-shaped cleft palate, which is consistent with **Pierre Robin sequence**. A sequence occurs when a **single developmental defect** causes a **cascade of additional malformations**.

In Pierre Robin sequence, hypoplasia of the mandibular prominence leads to **micrognathia**. Severe micrognathia causes posterior displacement of the tongue **(glossoptosis)**, which blocks fusion of the palatine shelves, resulting in a **cleft palate** that is characteristically U-shaped. Difficulty breathing occurs because the tongue prolapses into the posterior oropharynx, blocking airflow. Breathing improves when the patient is in a prone position because gravity pulls the tongue anteriorly, opening the airway.

(Choice A) An association is a collection of malformations that are often seen together and do not have a known, common cause (eg, VACTERL association).

(Choice B) A disruption occurs when an external insult (rather than a genetic defect) interrupts and arrests normal fetal development (eg, when

This patient has a small mandible, posteriorly displaced tongue, and U-shaped cleft palate, which is consistent with **Pierre Robin sequence**. A sequence occurs when a **single developmental defect** causes a **cascade of additional malformations**.

In Pierre Robin sequence, hypoplasia of the mandibular prominence leads to **micrognathia**. Severe micrognathia causes posterior displacement of the tongue **(glossoptosis)**, which blocks fusion of the palatine shelves, resulting in a **cleft palate** that is characteristically U-shaped. Difficulty breathing occurs because the tongue prolapses into the posterior oropharynx, blocking airflow. Breathing improves when the patient is in a prone position because gravity pulls the tongue anteriorly, opening the airway.

(Choice A) An association is a collection of malformations that are often seen together and do not have a known, common cause (eg, VACTERL association).

(Choice B) A disruption occurs when an external insult (rather than a genetic defect) interrupts and arrests normal fetal development (eg, when an amniotic band disrupts limb development). No specific external insult has been linked to Pierre Robin sequence, and most cases result from genetic abnormalities.

(Choice C) Genomic imprinting is a normal process that refers to selective activation of gene expression depending on the parent of origin. Aberrant imprinting occurs with uniparental disomy (ie, when a person receives 2 copies of a chromosome from the same parent and no copy from the other parent). Prader-Willi syndrome and Angelman syndrome (15q) are examples of conditions caused by dysfunctional imprinting.

(Choice E) A syndrome is a collection of malformations that have a common cause but are not related anatomically. For example, upslanting palpebral fissures, atrioventricular canal defect, and single palmar crease are all due to trisomy 21.

Educational objective:
Pierre Robin is characterized as a sequence because the primary defect (hypoplasia of the mandibular prominence) leads to a cascade of further malformations (ie, micrognathia, posteriorly displaced tongue, U-shaped cleft palate).

Embryology	Ear, Nose & Throat (ENT)	Craniofacial anomalies
Subject	System	Topic

Copyright © UWorld. All rights reserved.

This patient has a small mandible, posteriorly displaced tongue, and U-shaped cleft palate, which is consistent with **Pierre Robin sequence**. A sequence occurs when a **single developmental defect** causes a **cascade of additional malformations**.

In Pierre Robin sequence, hypoplasia of the mandibular prominence leads to **micrognathia**. Severe micrognathia causes posterior displacement of the tongue **(glossoptosis)**, which blocks fusion of the palatine shelves, resulting in a **cleft palate** that is characteristically U-shaped. Difficulty breathing occurs because the tongue prolapses into the posterior oropharynx, blocking airflow. Breathing improves when the patient is in a prone position because gravity pulls the tongue anteriorly, opening the airway.

(Choice A) An association is a collection of malformations that are often seen together and do not have a known, common cause (eg, VACTERL association).

(Choice B) A disruption occurs when an external insult (rather than a genetic defect) interrupts and arrests normal fetal development (eg, when an amniotic band disrupts limb development). No specific external insult has been linked to Pierre Robin sequence, and most cases result from genetic abnormalities.

(Choice C) Genomic imprinting is a normal process that refers to selective activation of gene expression depending on the parent of origin. Aberrant imprinting occurs with uniparental disomy (ie, when a person receives 2 copies of a chromosome from the same parent and no copy from the other parent). Prader-Willi syndrome and Angelman syndrome (15q) are examples of conditions caused by dysfunctional imprinting.

(Choice E) A syndrome is a collection of malformations that have a common cause but are not related anatomically. For example, upslanting palpebral fissures, atrioventricular canal defect, and single palmar crease are all due to trisomy 21.

Educational objective:
Pierre Robin is characterized as a sequence because the primary defect (hypoplasia of the mandibular prominence) leads to a cascade of further malformations (ie, micrognathia, posteriorly displaced tongue, U-shaped cleft palate).

Embryology	Ear, Nose & Throat (ENT)	Craniofacial anomalies
Subject	System	Topic

Copyright © UWorld. All rights reserved.

This patient has a small mandible, posteriorly displaced tongue, and U-shaped cleft palate, which is consistent with **Pierre Robin sequence**. A sequence occurs when a **single developmental defect** causes a **cascade of additional malformations**.

In Pierre Robin sequence, ent
of the tongue **(glossoptos** lty
breathing occurs because one
position because gravity p

(Choice A) An associatio RL
association).

(Choice B) A disruption c en
an amniotic band disrupts m
genetic abnormalities.

(Choice C) Genomic imp
Aberrant imprinting occurs from
the other parent). Prader-

(Choice E) A syndrome i
palpebral fissures, atriove

Educational objective:
Pierre Robin is characteriz her
malformations (ie, microgr

Embryology	Ear, N
Subject	System

Copyright © UWorld. All rights reserved.

Exhibit Display

VACTERL association
V: vertebral anomalies **A**: anal atresia **C**: cardiac defects **TE**: tracheoesophageal fistula **R**: renal anomalies **L**: limb anomalies

Add To Flash Card

This patient has a small mandible, posteriorly displaced tongue, and U-shaped cleft palate, which is consistent with **Pierre Robin sequence**. A

Exhibit Display

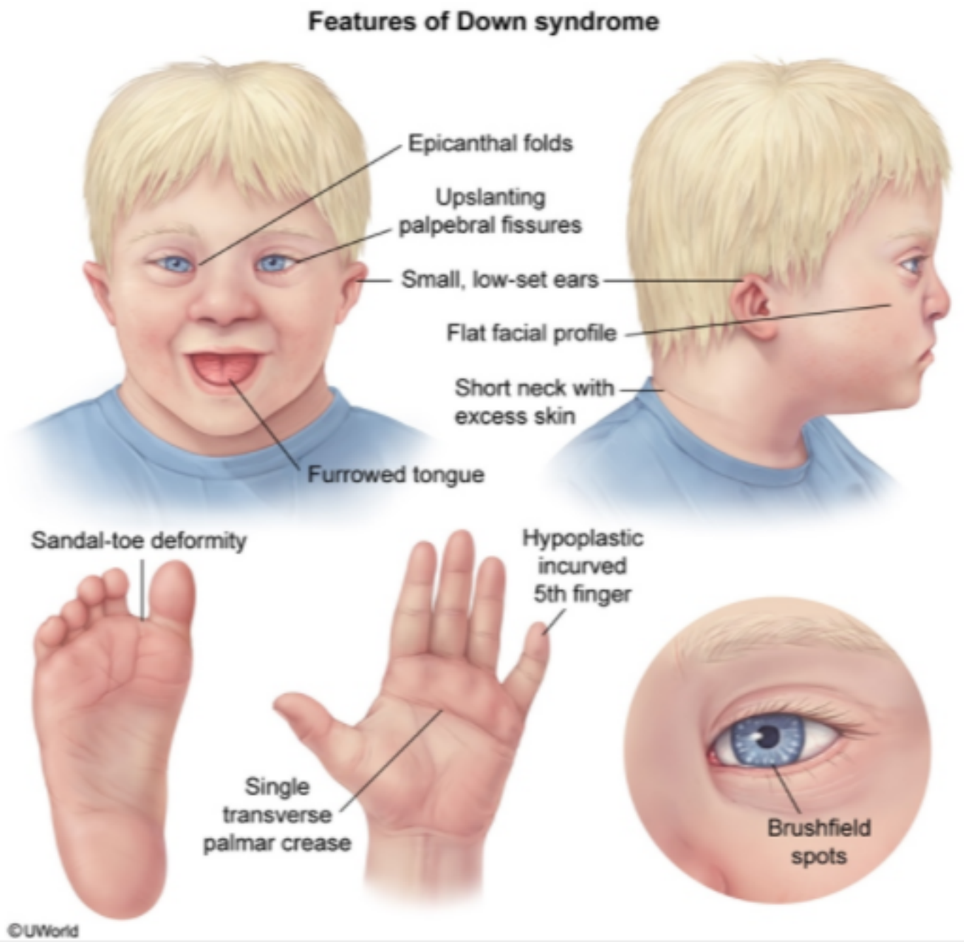

Zoom In Zoom Out Reset Add To Flash Card

A 34-year-old primigravida at 18 weeks gestation comes to the office for a routine prenatal examination. The patient's pregnancy has been uncomplicated. She takes a daily prenatal vitamin, and her prenatal laboratory results have been normal to date. The patient's personal and family medical histories are unremarkable. During the visit, a detailed fetal ultrasound reveals unilateral hydronephrosis. Male external genitalia are also visible. If the fetal hydronephrosis is caused by obstruction, which of the following is the most likely site?

A. Spinal cord

B. Ureteropelvic junction

C. Urethra

D. Urinary meatus

E. Vesicoureteral junction

Submit

A 34-year-old primigravida at 18 weeks gestation comes to the office for a routine prenatal examination. The patient's pregnancy has been uncomplicated. She takes a daily prenatal vitamin, and her prenatal laboratory results have been normal to date. The patient's personal and family medical histories are unremarkable. During the visit, a detailed fetal ultrasound reveals unilateral hydronephrosis. Male external genitalia are also visible. If the fetal hydronephrosis is caused by obstruction, which of the following is the most likely site?

- A. Spinal cord (0%)
- ✓ B. Ureteropelvic junction (55%)
- C. Urethra (4%)
- D. Urinary meatus (1%)
- E. Vesicoureteral junction (38%)

Omitted
Correct answer
B

55%
Answered correctly

02 secs
Time Spent

01/23/2020
Last Updated

Explanation

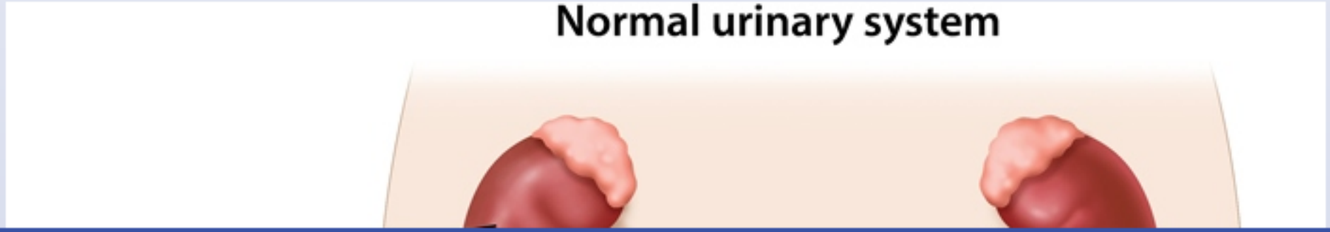

Settings

1 2 3 4 5 6 7 8 9 10 11 12 13 14 15 16 17 18 19 20 21 22 23 24 25 26 27 28 29 30

Item 40 of 40
Question Id: 837

Mark | Previous | Next | Full Screen | Tutorial | Lab Values | Notes | Calculator | Reverse Color | Text Zoom | Settings

Normal urinary system

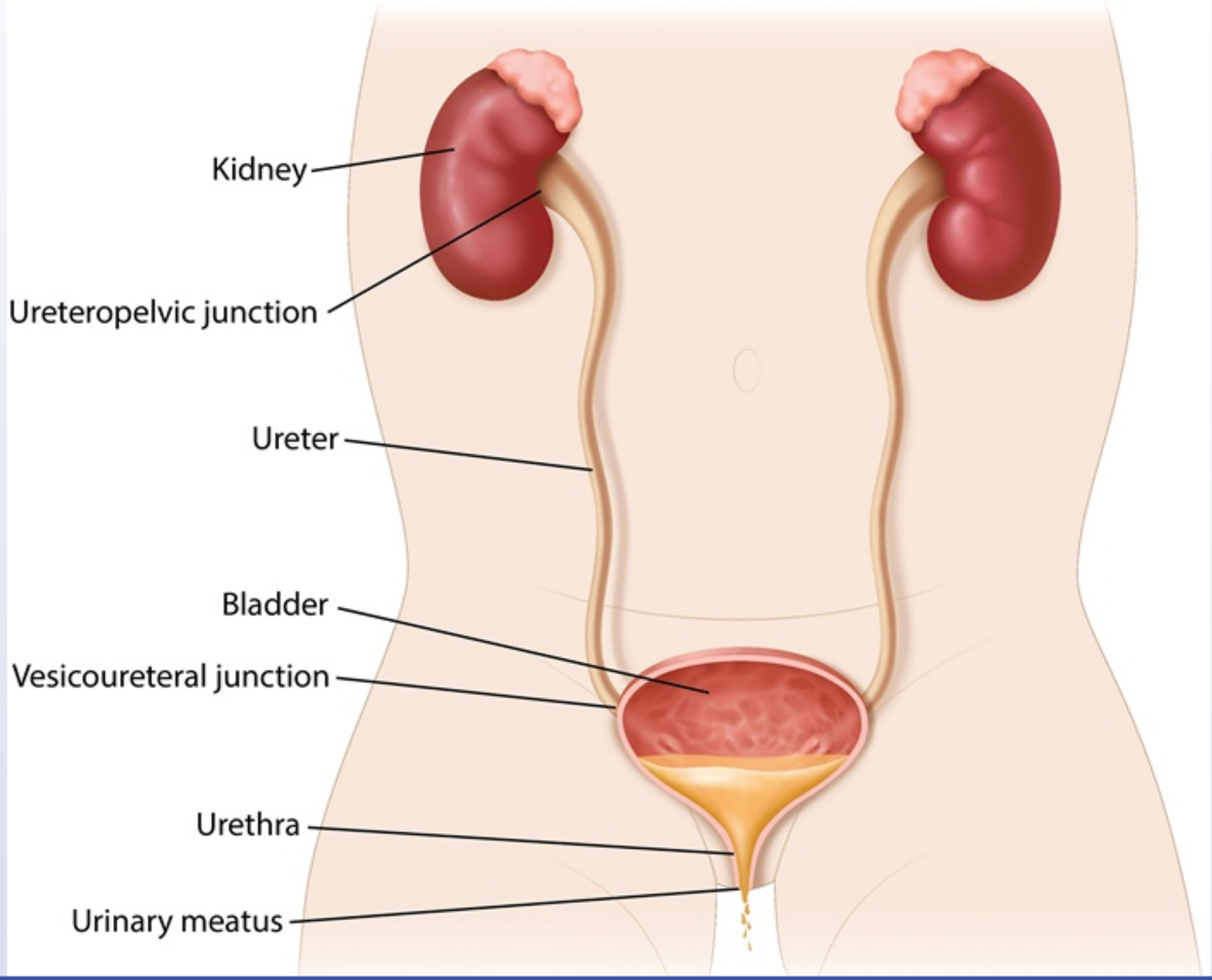

Block Time Remaining: 00:01:40
TUTOR

6 | Feedback | Suspend | End Block

1 2 3 4 5 6 7 8 9 10 11 12 13 14 15 16 17 18 19 20 21 22 23 24 25 26 27 28 29 30

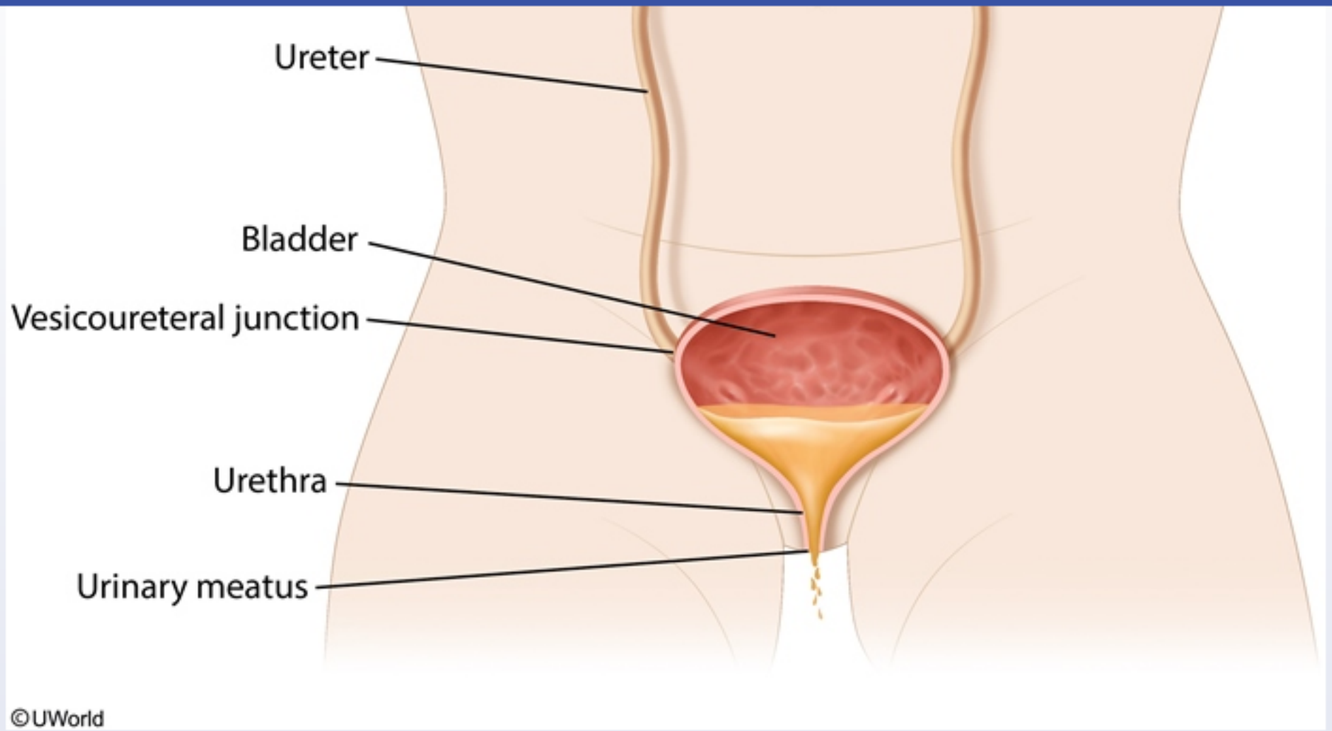

Fetal hydronephrosis is commonly detected in the second trimester during routine ultrasonographic anatomy survey. The finding is usually transient or clinically insignificant as the fetal **renal pelvis** has **high compliance** and can accommodate large volumes of urine. This compliance makes the fetal kidney susceptible to dilation (hydronephrosis), particularly in the setting of obstruction. The most common pathologic cause of unilateral fetal hydronephrosis is a narrowing or kinking of the proximal ureter at the **ureteropelvic junction (UPJ)**. Newborns who were not diagnosed prenatally may present with a **palpable abdominal mass** reflecting an **enlarged kidney**.

Embryologically, the fetal genitourinary tract is derived from the metanephric blastema and the ureteric bud (a dorsal outgrowth from the mesonephric duct). The metanephric blastema gives rise to functioning renal parenchyma by 10 weeks gestation while the ureteric bud develops into the renal pelvis and ureters through dilation and canalization. The UPJ is the last segment of the fetal ureter to canalize. The pathogenesis of UPJ obstruction may involve failure of this canalization through abnormal development of circular musculature and/or collagen fibers.

Fetal hydronephrosis is commonly detected in the second trimester during routine ultrasonographic anatomy survey. The finding is usually transient or clinically insignificant as the fetal **renal pelvis** has **high compliance** and can accommodate large volumes of urine. This compliance makes the fetal kidney susceptible to dilation (hydronephrosis), particularly in the setting of obstruction. The most common pathologic cause of unilateral fetal hydronephrosis is a narrowing or kinking of the proximal ureter at the **ureteropelvic junction (UPJ)**. Newborns who were not diagnosed prenatally may present with a **palpable abdominal mass** reflecting an **enlarged kidney**.

Embryologically, the fetal genitourinary tract is derived from the metanephric blastema and the ureteric bud (a dorsal outgrowth from the mesonephric duct). The metanephric blastema gives rise to functioning renal parenchyma by 10 weeks gestation while the ureteric bud develops into the renal pelvis and ureters through dilation and canalization. The UPJ is the last segment of the fetal ureter to canalize. The pathogenesis of UPJ obstruction may involve failure of this canalization through abnormal development of circular musculature and/or collagen fibers.

(Choices A, C, and D) Posterior urethral valves are the most common cause of bilateral fetal hydronephrosis in boys. They are caused by an obstructive, persistent urogenital membrane at the junction of the bladder and urethra. Other congenital anomalies that cause bilateral fetal hydronephrosis include urethral strictures, meatal stenosis, and bladder neck obstruction. Neurogenic causes of obstructive uropathy (eg, spinal cord damage) can also result in bilateral hydronephrosis.

(Choice E) During normal bladder contraction, the intravesical portion of the ureter is compressed to ensure the anterograde travel of urine. Vesicoureteral reflux results from incomplete closure at this vesicoureteral junction and can lead to chronic dilation of the ureter and renal pelvis (unilateral or bilateral). This is a nonobstructive cause of fetal hydronephrosis.

Educational objective:
Inadequate canalization of the ureteropelvic junction, the connection site between the kidney and the ureter, is the most common cause of unilateral fetal hydronephrosis.

References

- Hydronephrosis: prenatal and postnatal evaluation and management.
- Clinical outcome and follow-up of prenatal hydronephrosis.

Embryology | Renal, Urinary Systems & Electrolytes | Urinary tract obstruction

Fetal hydronephrosis is commonly detected in the second trimester during routine ultrasonographic anatomy survey. The finding is usually

Exhibit Display

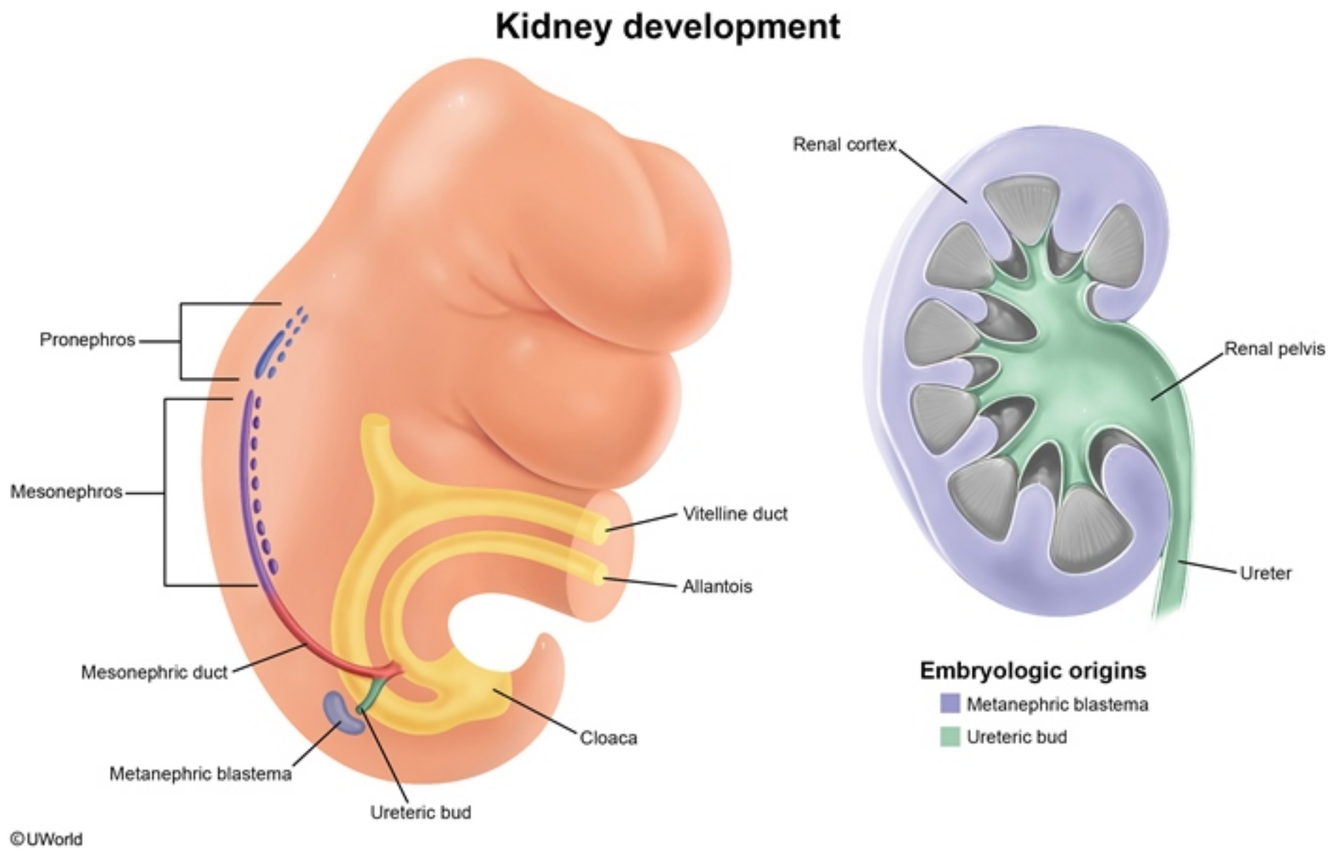

Zoom In Zoom Out Reset Add To New Card | Existing Card

Fetal hydronephrosis is commonly detected in the second trimester during routine ultrasonographic anatomy survey. The finding is usually

Exhibit Display

Vesicoureteral reflux

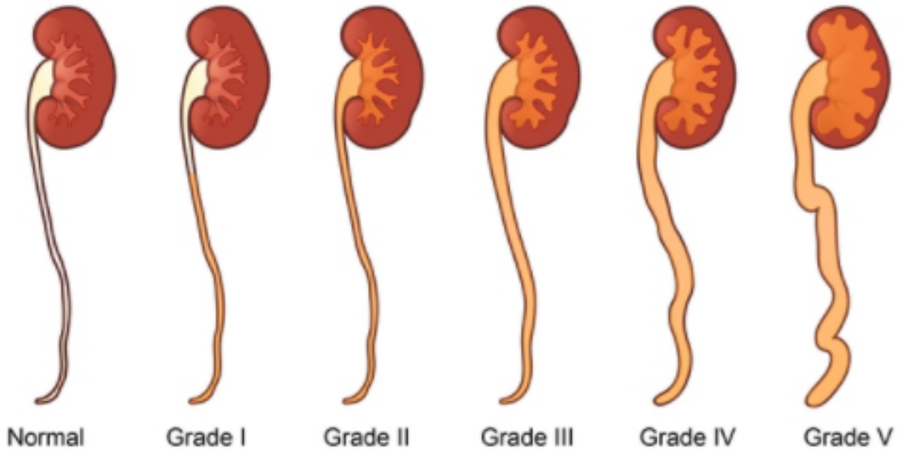

Grade	Description
I	Into a nondilated ureter
II	Into the pelvis & calyces without dilation
III	Mild to moderate dilation of the ureter, renal pelvis & calyces, with minimal blunting of the fornices
IV	Moderate ureteral tortuosity & dilation of the pelvis & calyces
V	Gross dilation of the ureter, pelvis & calyces; loss of papillary impressions; ureteral tortuosity

©UWorld

Zoom In | Zoom Out | Reset | Add To New Card | Existing Card

Settings

1
2
3
4
5
6
7
8
9
10

Item 1 of 10
Question Id: 1750

Mark | Previous | Next | Full Screen | Tutorial | Lab Values | Notes | Calculator | Reverse Color | Text Zoom | Settings

A 64-year-old man loses consciousness near the entrance to an emergency room. A physician rushes to the patient and palpates a strong pulse along the inner side of the left sternocleidomastoid muscle. The vessel palpated by the doctor is a derivative of which of the following aortic arches?

A. First
B. Second
C. Third
D. Fourth
E. Sixth

Submit

Block Time Remaining: 00:00:01
TUTOR

2 | Feedback | Suspend | End Block

A 64-year-old man loses consciousness near the entrance to an emergency room. A physician rushes to the patient and palpates a strong pulse along the inner side of the left sternocleidomastoid muscle. The vessel palpated by the doctor is a derivative of which of the following aortic arches?

A. First (7%)
B. Second (23%)
✓ C. Third (51%)
D. Fourth (12%)
E. Sixth (5%)

Omitted
Correct answer
C

51%
Answered correctly

02 secs
Time Spent

04/15/2020
Last Updated

Explanation

Arches & associated cranial nerves		
Pharyngeal and aortic arch	Cranial nerve	Key aortic arch derivatives
1	Trigeminal (CN V)	Maxillary artery (portion)

Arches & associated cranial nerves		
Pharyngeal and aortic arch	**Cranial nerve**	**Key aortic arch derivatives**
1	Trigeminal (CN V)	Maxillary artery (portion)
2	Facial (CN VII)	Stapedial artery (regresses)
3	Glossopharyngeal (CN IX)	Common carotid artery, proximal internal carotid artery
4	Superior laryngeal branch of vagus (CN X)	True aortic arch, subclavian arteries
5	Obliterated	Obliterated
6	Recurrent laryngeal branch of CN X	Pulmonary arteries, ductus arteriosus

During embryonic development, the head, neck, and upper thorax region develop from a set of arches known as **pharyngeal arches**. Each arch is associated with a cranial nerve and an aortic arch derivative. The vessel palpated in this patient is the **common carotid artery**, which (along with the proximal portion of the internal carotid artery) is derived from the **third aortic arch** (ie, third pharyngeal arch). The third pharyngeal arch also gives rise to the glossopharyngeal nerve (CN IX), parts of the hyoid bone, and the stylopharyngeus muscle.

(Choice A) The first pharyngeal arch is associated with the trigeminal nerve (CN V). This pharyngeal arch gives rise to the tensor tympani, muscles of mastication, maxilla, and inner ear bones (eg, incus, malleus). The associated first aortic arch regresses almost completely, although it does give rise to a portion of the maxillary artery.

(Choice B) The second pharyngeal arch is associated with the facial nerve (CN VII). This pharyngeal arch gives rise to the muscles of facial

During embryonic development, the head, neck, and upper thorax region develop from a set of arches known as **pharyngeal arches**. Each arch is associated with a cranial nerve and an aortic arch derivative. The vessel palpated in this patient is the **common carotid artery**, which (along with the proximal portion of the internal carotid artery) is derived from the **third aortic arch** (ie, third pharyngeal arch). The third pharyngeal arch also gives rise to the glossopharyngeal nerve (CN IX), parts of the hyoid bone, and the stylopharyngeus muscle.

(Choice A) The first pharyngeal arch is associated with the trigeminal nerve (CN V). This pharyngeal arch gives rise to the tensor tympani, muscles of mastication, maxilla, and inner ear bones (eg, incus, malleus). The associated first aortic arch regresses almost completely, although it does give rise to a portion of the maxillary artery.

(Choice B) The second pharyngeal arch is associated with the facial nerve (CN VII). This pharyngeal arch gives rise to the muscles of facial expression as well as some ear and hyoid structures. The stapedial artery is a derivative of the associated second aortic arch, but this vessel typically regresses.

(Choice D) The fourth pharyngeal arch is associated with the superior laryngeal branch of the vagus nerve (CN X). This pharyngeal arch gives rise to many of the muscles of the pharynx and soft palate as well as a few of the laryngeal muscles. The associated fourth aortic arch gives rise to part of the true aortic arch and subclavian arteries.

(Choice E) The sixth pharyngeal arch is associated with the recurrent laryngeal branches of CN X. This pharyngeal arch gives rise to most of the muscles of the larynx, and the associated aortic arch gives rise to the pulmonary arteries and the ductus arteriosus.

Educational objective:
The common carotid artery and the proximal portion of the internal carotid artery are derived from the third aortic arch. The third aortic arch is associated with the third pharyngeal arch, which gives rise to the glossopharyngeal nerve (CN IX), parts of the hyoid bone, and the stylopharyngeus muscle.

Embryology	Cardiovascular System	Embryologic derivatives
Subject	System	Topic

Copyright © UWorld. All rights reserved.

Settings

1
2
3
4
5
6
7
8
9
10

Item 1 of 10
Question Id: 1750

Mark | Previous | Next | Full Screen | Tutorial | Lab Values | Notes | Calculator | Reverse Color | Text Zoom | Settings

Exhibit Display

Pharyngeal arches in the embryo

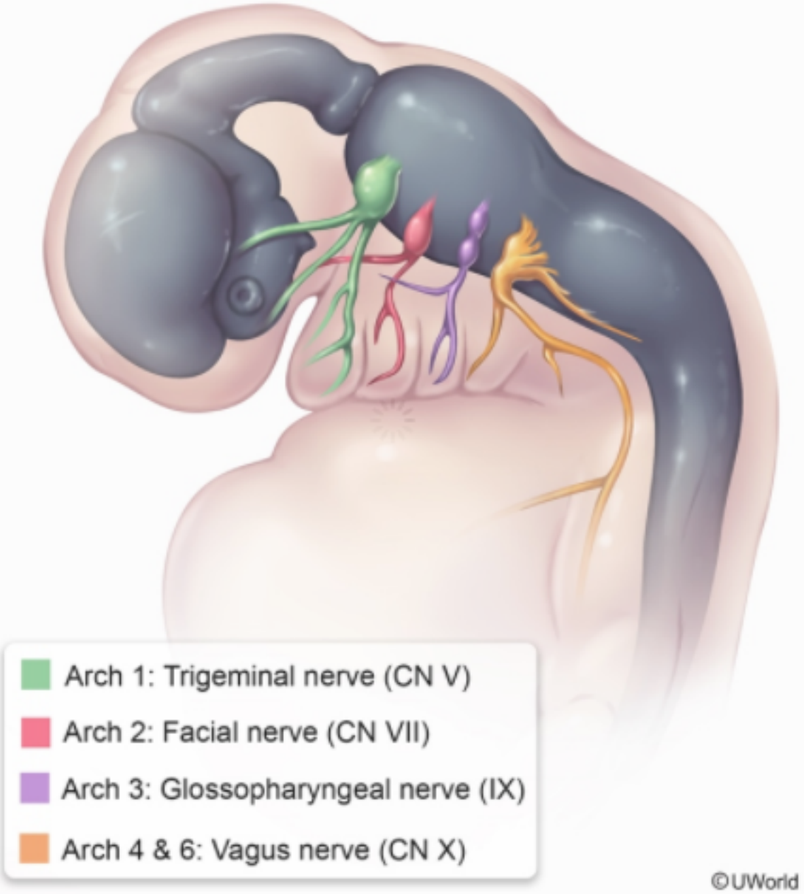

Zoom In | Zoom Out | Reset | Add To New Card | Existing Card

Copyright © UWorld. All rights reserved.

Block Time Remaining: 00:00:02
TUTOR

2 | Feedback | Suspend | End Block

Settings

1
2
3
4
5
6
7
8
9
10

Item 2 of 10
Question Id: 1534

Mark | Previous | Next | Full Screen | Tutorial | Lab Values | Notes | Calculator | Reverse Color | Text Zoom | Settings

A 22-year-old man comes to the office due to occasional dull headaches that awaken him from sleep. The patient has no associated neurologic deficits. There is no history of migraines in the family. His temperature is 37.2 C (99 F), blood pressure is 140/80 mm Hg, pulse is 60/min, and respirations are 12/min. On physical examination, there are several 3- to 5-cm flat, pigmented spots on his trunk. There are also multiple, subcentimeter, soft, fleshy, cutaneous tumors located on his trunk and neck. The predominant cells forming these skin tumors most likely originated from which of the following structures?

A. Endoderm
B. Mesoderm
C. Neural crest
D. Neural tube
E. Notochord
F. Surface ectoderm

Submit

Block Time Remaining: 00:00:03
TUTOR

4 | Feedback | Suspend | End Block

A 22-year-old man comes to the office due to occasional dull headaches that awaken him from sleep. The patient has no associated neurologic deficits. There is no history of migraines in the family. His temperature is 37.2 C (99 F), blood pressure is 140/80 mm Hg, pulse is 60/min, and respirations are 12/min. On physical examination, there are several 3- to 5-cm flat, pigmented spots on his trunk. There are also multiple, subcentimeter, soft, fleshy, cutaneous tumors located on his trunk and neck. The predominant cells forming these skin tumors most likely originated from which of the following structures?

- A. Endoderm (1%)
- B. Mesoderm (3%)
- ✓ C. Neural crest (73%)
- D. Neural tube (3%)
- E. Notochord (0%)
- F. Surface ectoderm (17%)

Omitted
Correct answer
C

73%
Answered correctly

02 secs
Time Spent

03/15/2020
Last Updated

Explanation

Embryological derivatives

Embryological derivatives		
Ectoderm	Surface ectoderm	• Anterior pituitary (Rathke pouch) • Lens & cornea • Inner ear sensory organs, olfactory epithelium • Nasal & oral epithelial linings, salivary glands • Epidermis, sweat & mammary glands
	Neural tube	• Brain & spinal cord • Posterior pituitary, pineal gland • Retina
	Neural crest	• Neural ganglia, adrenal medulla • Schwann cells; pia & arachnoid mater • Aorticopulmonary septum & endocardial cushions • Branchial arches (bones & cartilage) • Skull bones • Melanocytes
Mesoderm		• Muscles (skeletal, cardiac & smooth) • Connective tissue, bone & cartilage • Serosal linings (eg, peritoneum) • Cardiovascular & lymphatic system • Spleen & hemopoietic cells • Kidney & ureters, internal genitalia • Adrenal cortex
		• Gastrointestinal tract, liver, pancreas

Mesoderm	• Muscles (skeletal, cardiac & smooth) • Connective tissue, bone & cartilage • Serosal linings (eg, peritoneum) • Cardiovascular & lymphatic system • Spleen & hemopoietic cells • Kidney & ureters, internal genitalia • Adrenal cortex
Endoderm	• Gastrointestinal tract, liver, pancreas • Lungs • Thymus, parathyroids, thyroid follicular cells • Middle ear epithelium • Bladder & urethra • Parafollicular (C) cells*

*Formerly thought to be of neural crest origin.

This patient has clinical features of **neurofibromatosis type I** (von Recklinghausen disease), an autosomal dominant neurocutaneous disorder caused by mutations in the *NF1* tumor suppressor gene. Patients typically develop hyperpigmented macules (café-au-lait spots) over the trunk soon after birth and are at increased risk of developing central nervous system neoplasms (eg, optic gliomas, pilocytic astrocytomas), which can cause elevated intracranial pressure and headache.

Cutaneous neurofibromas usually manifest during early adolescence as multiple, raised, fleshy tumors (<2 cm) that often increase in size and number with age. These are benign nerve sheath neoplasms predominantly comprised of **Schwann cells**, which are embryologically derived from the **neural crest**.

(Choice A) The endoderm gives rise to thyroid follicular cells (derived from the primitive tongue) and the epithelial linings of the gastrointestinal tract, middle ear, lung, bladder, and most of the urethra. It also gives rise to the bulk of the liver, pancreas, and lungs, as these structures form from outpouchings of the primitive gut tube.

This patient has clinical features of **neurofibromatosis type I** (von Recklinghausen disease), an autosomal dominant neurocutaneous disorder caused by mutations in the *NF1* tumor suppressor gene. Patients typically develop hyperpigmented macules (café-au-lait spots) over the trunk soon after birth and are at increased risk of developing central nervous system neoplasms (eg, optic gliomas, pilocytic astrocytomas), which can cause elevated intracranial pressure and headache.

Cutaneous neurofibromas usually manifest during early adolescence as multiple, raised, fleshy tumors (<2 cm) that often increase in size and number with age. These are benign nerve sheath neoplasms predominantly comprised of **Schwann cells**, which are embryologically derived from the **neural crest**.

(Choice A) The endoderm gives rise to thyroid follicular cells (derived from the primitive tongue) and the epithelial linings of the gastrointestinal tract, middle ear, lung, bladder, and most of the urethra. It also gives rise to the bulk of the liver, pancreas, and lungs, as these structures form from outpouchings of the primitive gut tube.

(Choice B) The mesoderm is divided into paraxial, intermediate, and lateral sections and gives rise to muscles, bones, blood, connective tissue, dermis, and the kidneys/ureters.

(Choice D) The neural tube gives rise to neurons of the central nervous system and the neurohypophysis, retina, pineal gland, preganglionic autonomic fibers, astrocytes, and ependymal cells.

(Choice E) The notochord almost completely regresses in humans, and its only major derivative is the nucleus pulposus of the intervertebral disc. Vertebrae are derived from the paraxial mesoderm.

(Choice F) The surface ectoderm gives rise to the epidermis, lens of the eye, outer layer of the cornea, nasal and oral epithelium, and anal epithelium below the dentate line.

Educational objective:
Neurofibromatosis type I (von Recklinghausen disease) is an autosomal dominant disorder caused by mutations in the *NF1* tumor suppressor gene. Patients characteristically develop numerous cutaneous neurofibromas comprised mostly of Schwann cells, which are embryologically derived from the neural crest.

References

the **neural crest**.

(Choice A) The endoderm gives rise to thyroid follicular cells (derived from the primitive tongue) and the epithelial linings of the gastrointestinal tract, middle ear, lung, bladder, and most of the urethra. It also gives rise to the bulk of the liver, pancreas, and lungs, as these structures form from outpouchings of the primitive gut tube.

(Choice B) The mesoderm is divided into paraxial, intermediate, and lateral sections and gives rise to muscles, bones, blood, connective tissue, dermis, and the kidneys/ureters.

(Choice D) The neural tube gives rise to neurons of the central nervous system and the neurohypophysis, retina, pineal gland, preganglionic autonomic fibers, astrocytes, and ependymal cells.

(Choice E) The notochord almost completely regresses in humans, and its only major derivative is the nucleus pulposus of the intervertebral disc. Vertebrae are derived from the paraxial mesoderm.

(Choice F) The surface ectoderm gives rise to the epidermis, lens of the eye, outer layer of the cornea, nasal and oral epithelium, and anal epithelium below the dentate line.

Educational objective:
Neurofibromatosis type I (von Recklinghausen disease) is an autosomal dominant disorder caused by mutations in the *NF1* tumor suppressor gene. Patients characteristically develop numerous cutaneous neurofibromas comprised mostly of Schwann cells, which are embryologically derived from the neural crest.

References

- Neurofibromatosis type 1.

Embryology	Nervous System	Neurofibromatosis
Subject	System	Topic

Copyright © UWorld. All rights reserved.

A 38-year-old woman is brought to the emergency department after a motor vehicle collision. She sustained no injuries in the collision but is adamant that she did not see the car that hit her along the front side of her vehicle. The patient also reports that she has been having daily headaches and has not menstruated in 4 months. On physical examination, there is bitemporal hemianopsia but no other abnormalities. MRI of the brain is shown below.

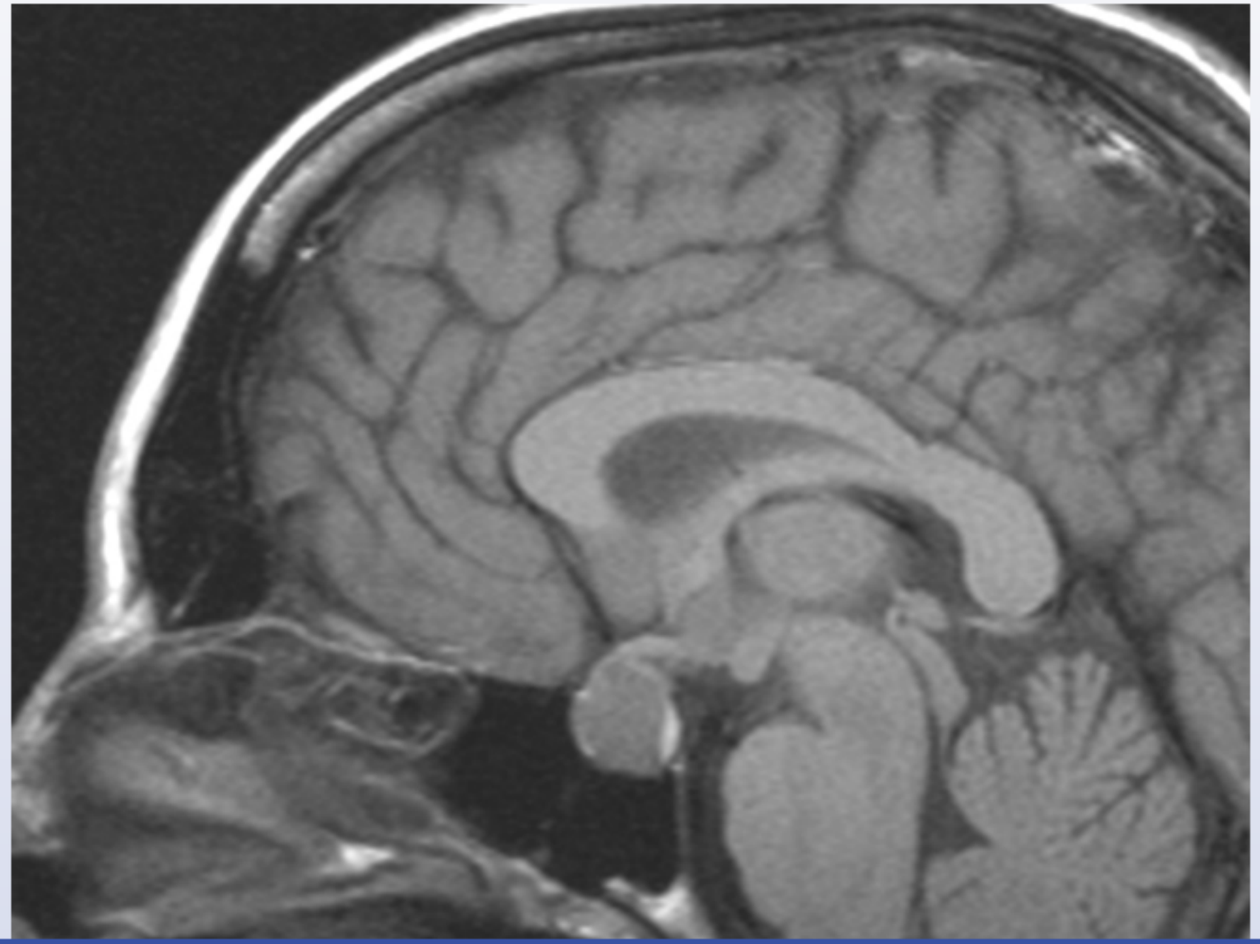

Settings

1
2
3
4
5
6
7
8
9
10

Item 3 of 10
Question Id: 8702

Mark | Previous | Next | Full Screen | Tutorial | Lab Values | Notes | Calculator | Reverse Color | Text Zoom | Settings

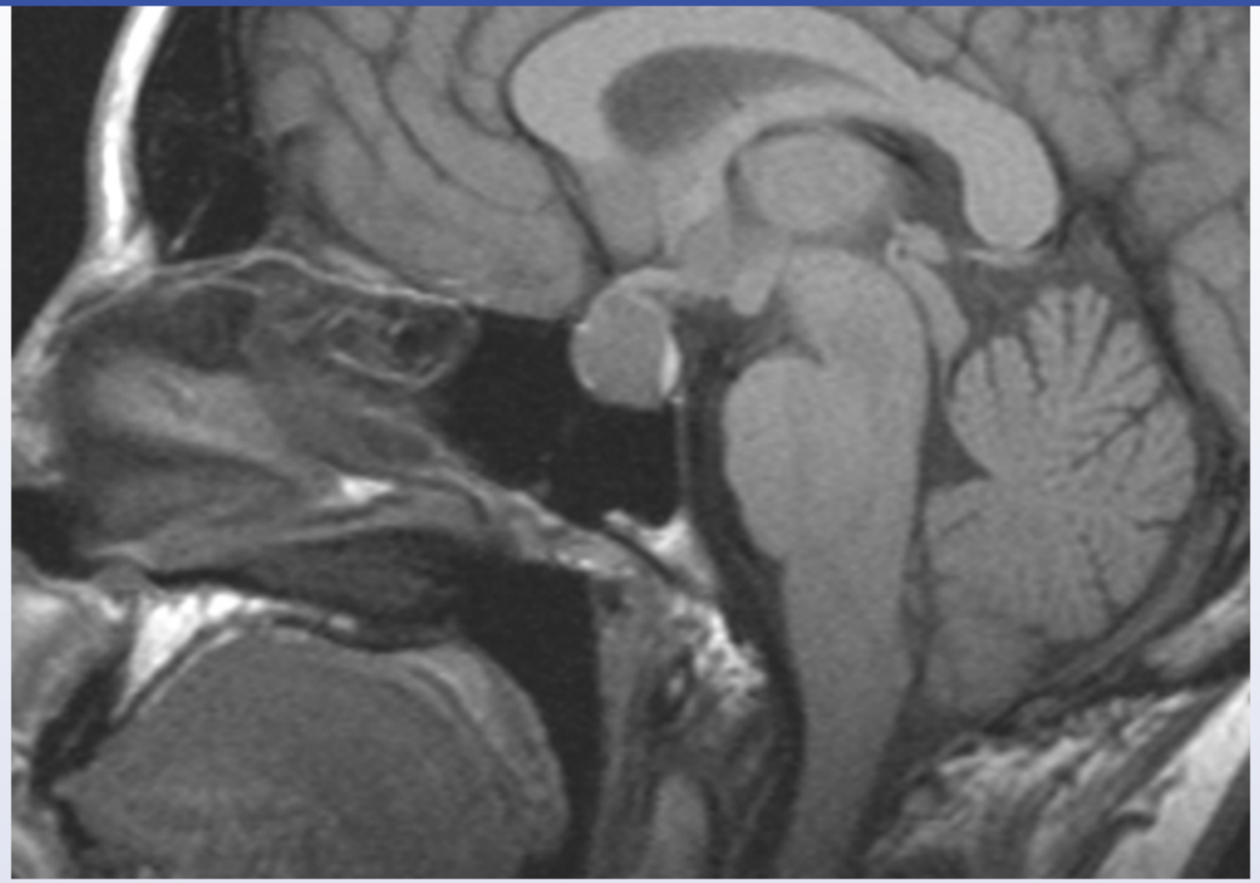

This patient's lesion most likely originates from which of the following embryologic layers?

A. Endoderm

B. Mesoderm

C. Neural crest

Block Time Remaining: 00:00:07
TUTOR

6 | Feedback | Suspend | End Block

Settings

1
2
3
4
5
6
7
8
9
10

Item 3 of 10
Question Id: 8702

Mark | Previous | Next | Full Screen | Tutorial | Lab Values | Notes | Calculator | Reverse Color | Text Zoom | Settings

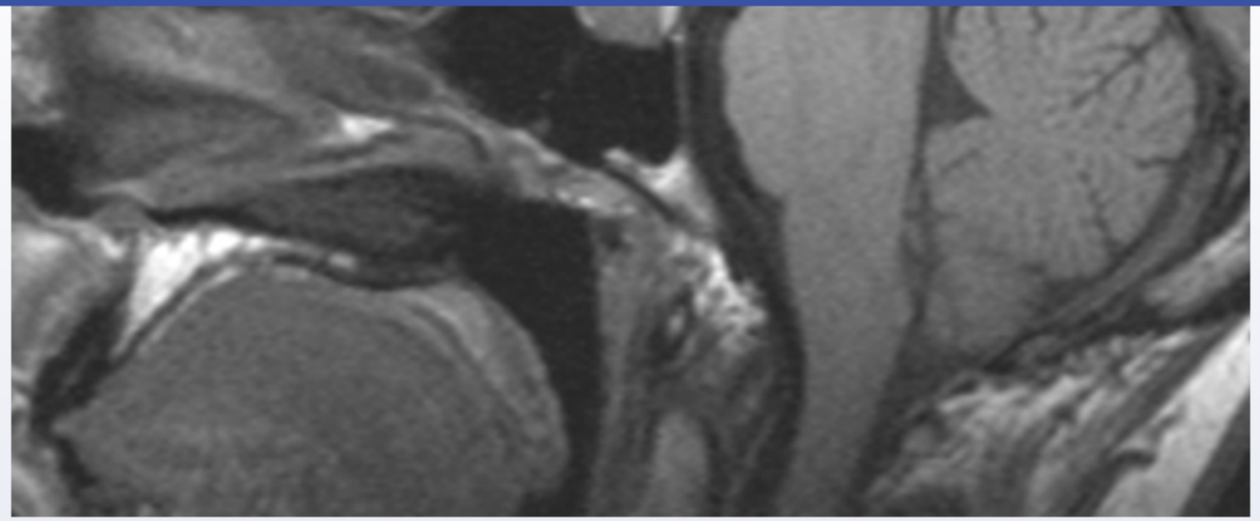

This patient's lesion most likely originates from which of the following embryologic layers?

- A. Endoderm
- B. Mesoderm
- C. Neural crest
- D. Neural tube
- E. Notochord
- F. Surface ectoderm

Submit

Block Time Remaining: 00:00:09
TUTOR

6 | Feedback | Suspend | End Block

Settings

1
2
3
4
5
6
7
8
9
10

Item 3 of 10
Question Id: 8702

Mark | Previous | Next | Full Screen | Tutorial | Lab Values | Notes | Calculator | Reverse Color | Text Zoom | Settings

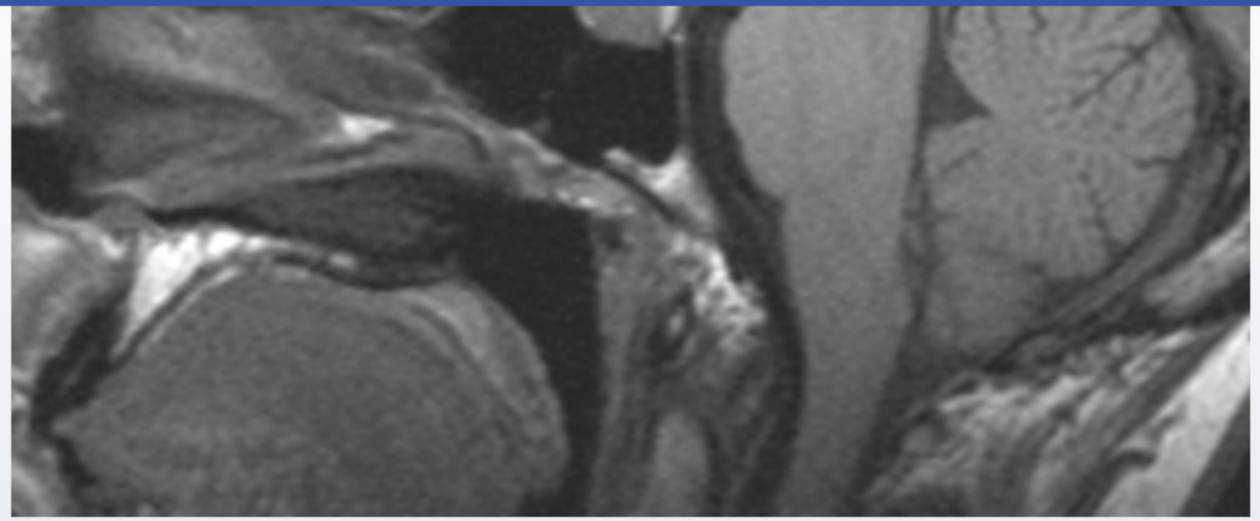

This patient's lesion most likely originates from which of the following embryologic layers?

- A. Endoderm (9%)
- B. Mesoderm (6%)
- C. Neural crest (21%)
- D. Neural tube (13%)
- E. Notochord (1%)
- ✓ F. Surface ectoderm (47%)

Omitted
Correct answer

47%
Answered correctly

06 secs
Time Spent

06/30/2020
Last Updated

Block Time Remaining: 00:00:10
TUTOR

6 | Feedback | Suspend | End Block

Embryological derivatives		
Ectoderm	Surface ectoderm	• Anterior pituitary (Rathke pouch) • Lens & cornea • Inner ear sensory organs, olfactory epithelium • Nasal & oral epithelial linings, salivary glands • Epidermis, sweat & mammary glands
	Neural tube	• Brain & spinal cord • Posterior pituitary, pineal gland • Retina
	Neural crest	• Neural ganglia, adrenal medulla • Schwann cells; pia & arachnoid mater • Aorticopulmonary septum & endocardial cushions • Branchial arches (bones & cartilage) • Skull bones • Melanocytes
Mesoderm		• Muscles (skeletal, cardiac & smooth) • Connective tissue, bone & cartilage • Serosal linings (eg, peritoneum) • Cardiovascular & lymphatic system • Spleen & hemopoietic cells • Kidney & ureters, internal genitalia • Adrenal cortex
		• Gastrointestinal tract, liver, pancreas

	• Melanocytes
Mesoderm	• Muscles (skeletal, cardiac & smooth) • Connective tissue, bone & cartilage • Serosal linings (eg, peritoneum) • Cardiovascular & lymphatic system • Spleen & hemopoietic cells • Kidney & ureters, internal genitalia • Adrenal cortex
Endoderm	• Gastrointestinal tract, liver, pancreas • Lungs • Thymus, parathyroids, thyroid follicular cells • Middle ear epithelium • Bladder & urethra • Parafollicular (C) cells*

*Formerly thought to be of neural crest origin.

Bitemporal hemianopsia, amenorrhea, and enlargement of the pituitary gland on brain imaging are suggestive of a prolactin-secreting **pituitary adenoma**. Prolactinomas develop from lactotroph cells in the **anterior pituitary** (adenohypophysis).

All tissues can be traced back to 3 primary germ layers: ectoderm, mesoderm, and endoderm. These germ layers form during the process of gastrulation, which occurs during week 3 of embryogenesis. Gastrulation is initiated by formation of the primitive streak, a thickening of the epiblast cell layer that appears at the caudal end of the embryo and grows cranially. Epiblast cells then undergo an epithelial-to-mesenchymal transition, causing them to lose their cell-cell adhesion properties. This allows them to migrate downward through the primitive streak to form the mesoderm **(Choice B)** and endoderm **(Choice A)** layers. The remainder of the epiblast layer forms the ectoderm.

About 2 days after gastrulation begins, some of the epiblast cells migrate cranially through the primitive node (the cephalic end of the primitive streak) to form a midline cellular cord known as the notochord. The notochord induces the overlying ectoderm to differentiate into the

	• Parafollicular (C) cells*

*Formerly thought to be of neural crest origin.

Bitemporal hemianopsia, amenorrhea, and enlargement of the pituitary gland on brain imaging are suggestive of a prolactin-secreting **pituitary adenoma**. Prolactinomas develop from lactotroph cells in the **anterior pituitary** (adenohypophysis).

All tissues can be traced back to 3 primary germ layers: ectoderm, mesoderm, and endoderm. These germ layers form during the process of gastrulation, which occurs during week 3 of embryogenesis. Gastrulation is initiated by formation of the primitive streak, a thickening of the epiblast cell layer that appears at the caudal end of the embryo and grows cranially. Epiblast cells then undergo an epithelial-to-mesenchymal transition, causing them to lose their cell-cell adhesion properties. This allows them to migrate downward through the primitive streak to form the mesoderm **(Choice B)** and endoderm **(Choice A)** layers. The remainder of the epiblast layer forms the ectoderm.

About 2 days after gastrulation begins, some of the epiblast cells migrate cranially through the primitive node (the cephalic end of the primitive streak) to form a midline cellular cord known as the notochord. The notochord induces the overlying ectoderm to differentiate into the neuroectoderm and form the neural plate. The neural plate gives rise to the neural crest and neural tube cells **(Choices C and D)**, while the remainder of the ectoderm becomes the surface ectoderm. The anterior pituitary is derived from the **Rathke pouch**, an evagination of the surface ectoderm that lines the fetal oral cavity. In contrast, the posterior pituitary (pars nervosa and pituitary stalk) is derived from the infundibulum, an extension of neuroectoderm from the diencephalon.

(Choice E) The notochord becomes the nucleus pulposus of the intervertebral disks in adults.

Educational objective:
All adult cells and tissues can be traced back to the 3 primary germ layers: ectoderm, mesoderm, and endoderm. The ectoderm gives rise to the surface ectoderm, neural tube, and neural crest.

Embryology	Nervous System	Pituitary adenoma
Subject	System	Topic

Copyright © UWorld. All rights reserved.

Settings

1
2
3
4
5
6
7
8
9
10

Item 3 of 10
Question Id: 8702

Mark | Previous | Next | Full Screen | Tutorial | Lab Values | Notes | Calculator | Reverse Color | Text Zoom | Settings

• Parafollicular (C) cells"

Exhibit Display

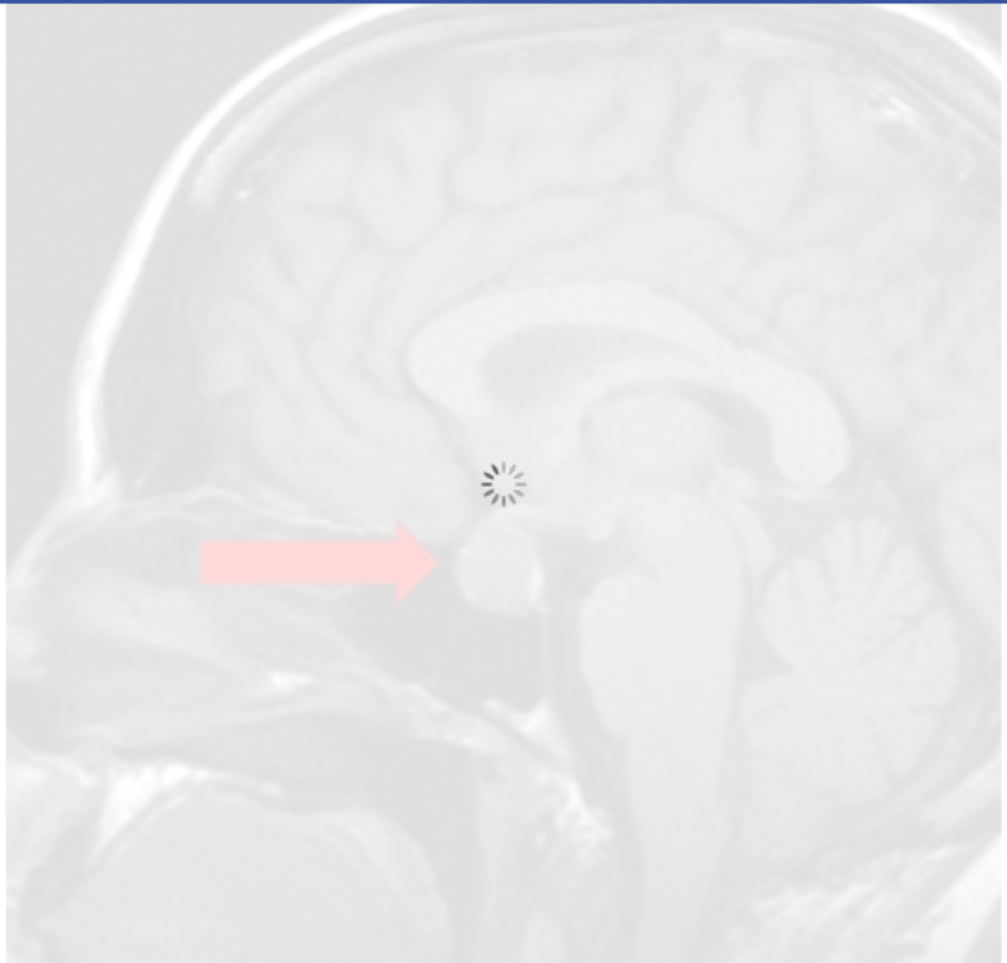

Zoom In | Zoom Out | Reset | Add To New Card | Existing Card

Block Time Remaining: 00:00:10
TUTOR

6 | Feedback | Suspend | End Block

• Parafollicular (C) cells*

*Formerly thought to be of neural crest origin.

Bitemporal hemianopsia, amenorrhea, and enlargement of the pituitary gland on bra
adenoma. Prolactinomas develop from lactotroph cells in the **anterior pituitary** (ac

All tissues can be traced back to 3 primary germ layers: ectoderm, mesoderm, and e
gastrulation, which occurs during week 3 of embryogenesis. Gastrulation is initiated
epibl Highlight Add To New Card Add To Existing Card vs cranially.
transition, causing them to lose their cell-cell adhesion properties. This allows them
mesoderm **(Choice B)** and endoderm **(Choice A)** layers. The remainder of the epib

About 2 days after gastrulation begins, some of the epiblast cells migrate cranially th
streak) to form a midline cellular cord known as the notochord. The notochord induc
neuroectoderm and form the neural plate. The neural plate gives rise to the neural c
remainder of the ectoderm becomes the surface ectoderm. The anterior pituitary is
ectoderm that lines the fetal oral cavity. In contrast, the posterior pituitary (pars nerv
extension of neuroectoderm from the diencephalon.

(Choice E) The notochord becomes the nucleus pulposus of the intervertebral disks

Educational objective:
All adult cells and tissues can be traced back to the 3 primary germ layers: ectoderm
surface ectoderm, neural tube, and neural crest.

Embryology	Nervous System	Pituitary adenoma
Subject	System	Topic

Copyright © UWorld. All rights rese

Exhibit Display

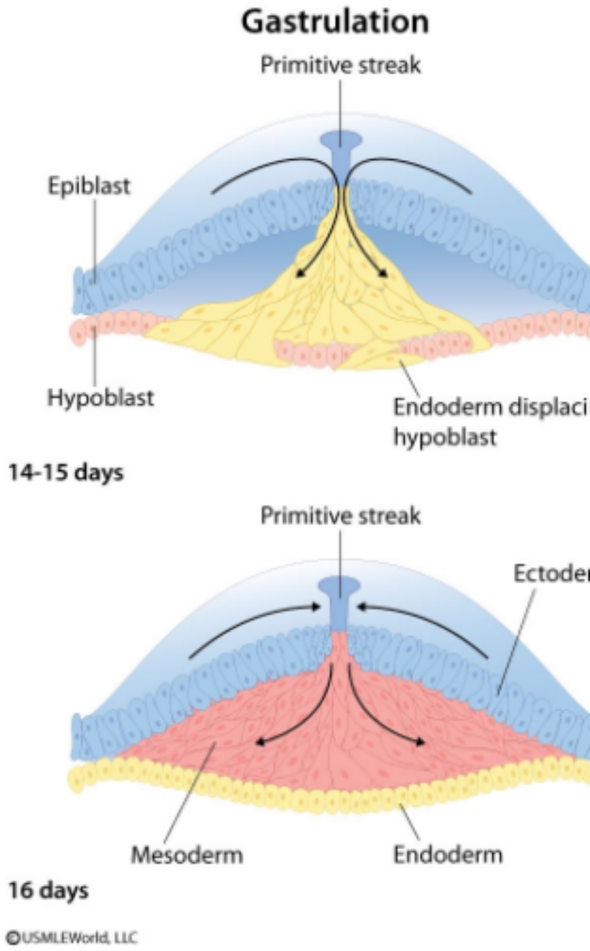

Zoom In Zoom Out Reset Add To New

Settings

1
2
3
4
5
6
7
8
9
10

Item 3 of 10
Question Id: 8702

Mark | Previous | Next | Full Screen | Tutorial | Lab Values | Notes | Calculator | Reverse Color | Text Zoom | Settings

• Parafollicular (C) cells"

Exhibit Display

Neural tube formation

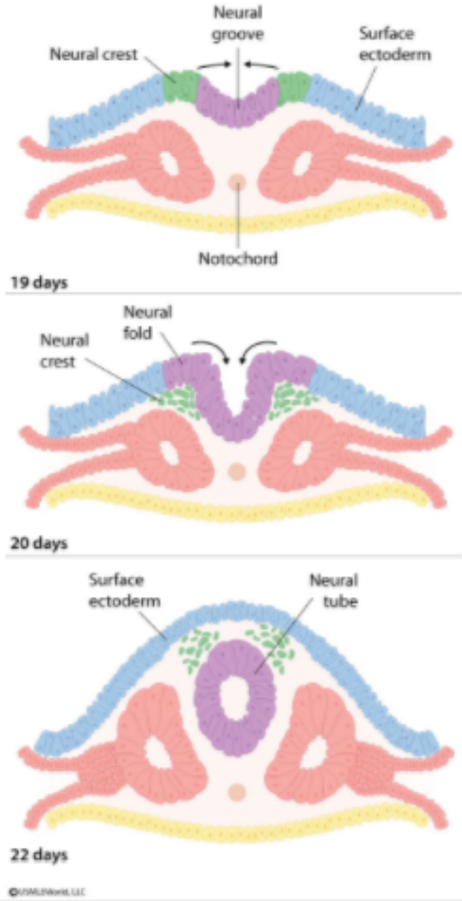

Zoom In | Zoom Out | Reset | Add To New Card | Existing Card

Block Time Remaining: 00:00:10
TUTOR

6 | Feedback | Suspend | End Block

• Parafollicular (C) cells"

Exhibit Display

Pituitary embryology

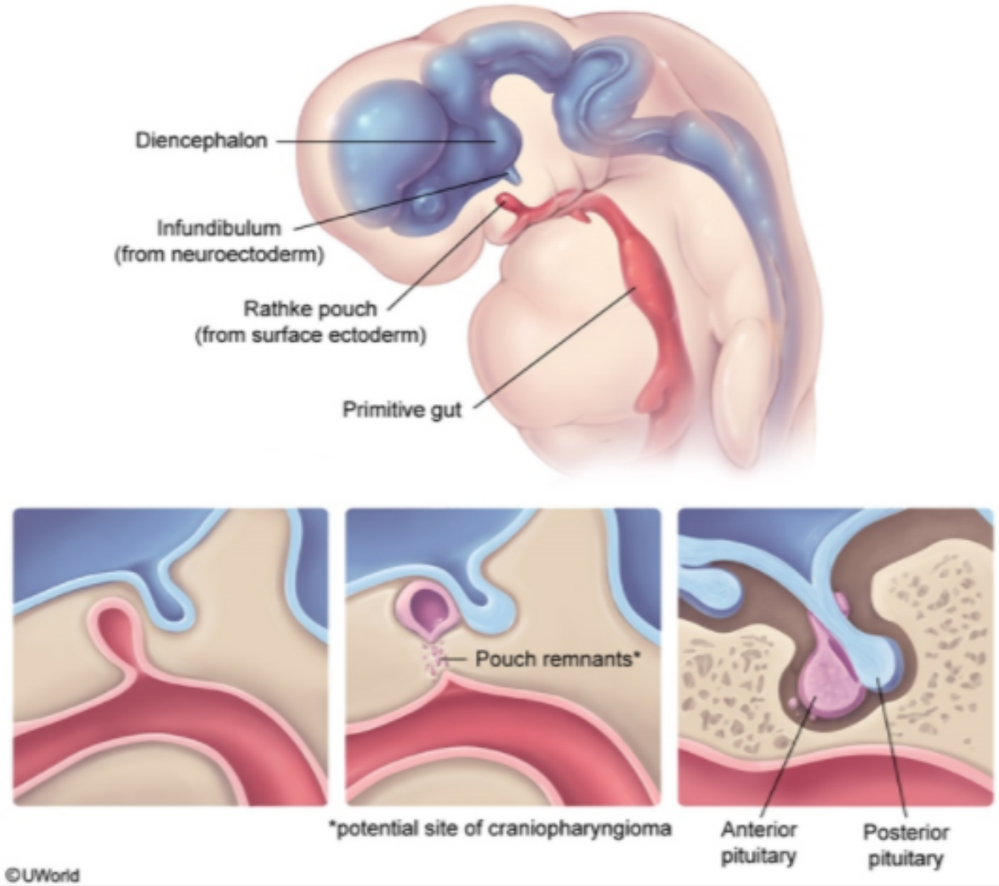

©UWorld

Zoom In | Zoom Out | Reset | Add To New Card | Existing Card

Settings

1
2
3
4
5
6
7
8
9
10

Item 4 of 10
Question Id: 15637

Mark | Previous | Next | Full Screen | Tutorial | Lab Values | Notes | Calculator | Reverse Color | Text Zoom | Settings

A 35-year-old woman, gravida 2 para 1, comes to the office for prenatal evaluation. The patient says she had been using condoms for birth control and unintentionally became pregnant. Her last menstrual period was 2 months ago, and home pregnancy tests are positive. She has not been taking prenatal vitamins. The patient has a healthy, 5-year-old daughter who was born after an uneventful pregnancy. She has a history of rheumatoid arthritis, and her joint symptoms are controlled with methotrexate therapy. The patient has no other medical conditions and takes no other medications. She does not use tobacco, alcohol, or illicit drugs. Vital signs are within normal limits, and physical examination shows no abnormalities. Serum β-hCG is elevated, and transvaginal ultrasonography shows a normal gestational sac and embryo. This patient's unborn child is at the greatest risk for which of the following congenital defects?

A. Branchial arch anomalies
B. Neural tube defects
C. Renal dysplasia
D. Sacral agenesis
E. Skeletal lesions
F. Thyroid hypoplasia

Submit

Block Time Remaining: 00:00:10
TUTOR

5 | Feedback | Suspend | End Block

A 35-year-old woman, gravida 2 para 1, comes to the office for prenatal evaluation. The patient says she had been using condoms for birth control and unintentionally became pregnant. Her last menstrual period was 2 months ago, and home pregnancy tests are positive. She has not been taking prenatal vitamins. The patient has a healthy, 5-year-old daughter who was born after an uneventful pregnancy. She has a history of rheumatoid arthritis, and her joint symptoms are controlled with methotrexate therapy. The patient has no other medical conditions and takes no other medications. She does not use tobacco, alcohol, or illicit drugs. Vital signs are within normal limits, and physical examination shows no abnormalities. Serum β-hCG is elevated, and transvaginal ultrasonography shows a normal gestational sac and embryo. This patient's unborn child is at the greatest risk for which of the following congenital defects?

- A. Branchial arch anomalies (2%)
- ✓ B. Neural tube defects (91%)
- C. Renal dysplasia (1%)
- D. Sacral agenesis (1%)
- E. Skeletal lesions (1%)
- F. Thyroid hypoplasia (1%)

Omitted
Correct answer
B

91%
Answered correctly

02 secs
Time Spent

04/07/2020
Last Updated

Explanation

Explanation

Folate antagonists		
Mechanism	**Drug**	**Therapeutic applications**
Inhibition of DHFR	Methotrexate	• Rheumatoid arthritis • Cancer
	Sulfasalazine	• Rheumatoid arthritis • Inflammatory bowel disease
	Triamterene	• Diuretic (with HCTZ) for edema & hypertension
	Trimethoprim	• Cystitis • *Pneumocystis* pneumonia (with sulfamethoxazole)
Variable inhibition of folate metabolism	• Valproic acid • Carbamazepine • Phenytoin	• Seizure disorders • Bipolar disorder (valproic acid & carbamazepine)

DHFR = dihydrofolate reductase; HCTZ = hydrochlorothiazide.

This patient with an unintended pregnancy has been taking **methotrexate**, a disease-modifying antirheumatic drug, to control symptoms of **rheumatoid arthritis**. Methotrexate is a folic acid analog that **competitively inhibits** dihydrofolate reductase, which produces nucleic acid precursors that are essential to DNA synthesis and repair. **Rapidly dividing cells** (eg, neural tube cells, stem cells, hepatic cells, epithelial cells) are **particularly susceptible** to folate antagonism. All patients taking methotrexate should also take a daily folic acid supplement to ameliorate the potential adverse effects (eg, oral ulcers, hepatotoxicity).

Methotrexate and other folate antagonists have **abortifacient** and/or **teratogenic** effects when used during the first trimester. They are contraindicated in pregnant women except under specific circumstances (eg, cancer therapy with no better alternative, treatment of ectopic

DHFR = dihydrofolate reductase; HCTZ = hydrochlorothiazide.

This patient with an unintended pregnancy has been taking **methotrexate**, a disease-modifying antirheumatic drug, to control symptoms of **rheumatoid arthritis**. Methotrexate is a folic acid analog that **competitively inhibits** dihydrofolate reductase, which produces nucleic acid precursors that are essential to DNA synthesis and repair. **Rapidly dividing cells** (eg, neural tube cells, stem cells, hepatic cells, epithelial cells) are **particularly susceptible** to folate antagonism. All patients taking methotrexate should also take a daily folic acid supplement to ameliorate the potential adverse effects (eg, oral ulcers, hepatotoxicity).

Methotrexate and other folate antagonists have **abortifacient** and/or **teratogenic** effects when used during the first trimester. They are contraindicated in pregnant women except under specific circumstances (eg, cancer therapy with no better alternative, treatment of ectopic pregnancy). Adverse effects of methotrexate use to the fetus include cardiovascular, urinary tract, and **neural tube defects** (eg, anencephaly, spina bifida).

(Choice A) Under the influence of Hox (homeobox) genes, the branchial arches develop into many head and neck tissues (eg, muscles, bones, and cartilage of the face, neck, and pharynx). Retinoids (eg, topical tretinoin) are vitamin A derivatives used in the treatment of acne that interfere with the Hox signaling pathways. If used during pregnancy, they can cause branchial arch abnormalities (eg, CNS, thymic, and craniofacial defects).

(Choice C) Renal dysplasia can be a complication of second or third trimester fetal exposure to ACE inhibitors in hypertensive mothers. Because fetal renal function is essential to maintain amniotic fluid volume, impaired renal function can lead to pulmonary hypoplasia, limb contractions, growth restriction, or cord compression with poor fetal outcomes.

(Choice D) Sacral agenesis (ie, caudal regression syndrome) is a rare malformation that occurs almost exclusively in infants of diabetic mothers. Defects can include incomplete development of the sacrum, lumbar vertebrae, and lower extremities.

(Choice E) Skeletal lesions can occur in congenital syphilis infection due to an inflammatory response (eg, periostitis, osteochondritis) to *Treponema pallidum* spirochetes in highly vascular areas of bones (eg, Hutchinson teeth). Although methotrexate exposure can cause skeletal development abnormalities, discrete inflammatory lesions would not be expected.

(Choice F) Thyroid hypoplasia is a complication of inadvertent fetal exposure to radioactive iodine (I131) in patients receiving treatment for

DHFR = dihydrofolate reductase; HCTZ = hydrochlorothiazide

Exhibit Display

Trimethoprim-sulfamethoxazole & folic acid pathway

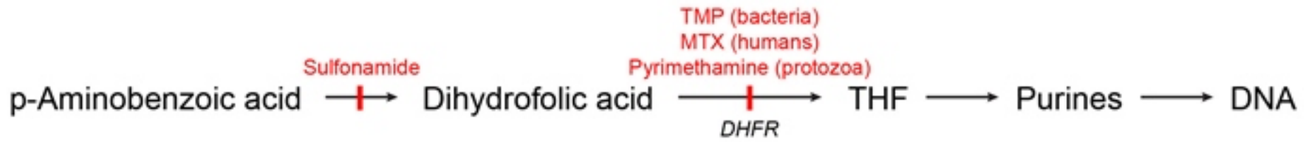

DHFR = dihydrofolate reductase; MTX = methotrexate; THF = tetrahydrofolic acid; TMP = trimethoprim

©UWorld

Zoom In | Zoom Out | Reset | Add To New Card | Existing Card

DHFR = dihydrofolate reductase; HCTZ = hydrochlorothiazide

Exhibit Display

Trimethoprim-sulfamethoxazole & folic acid pathway

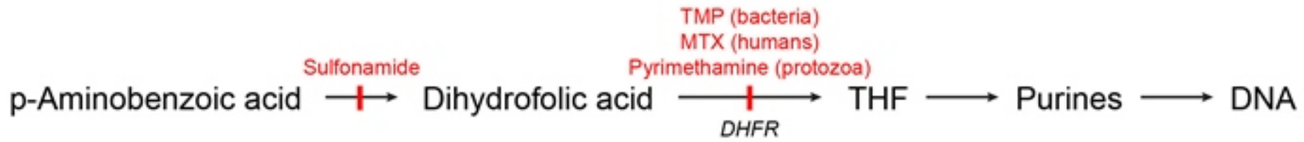

DHFR = dihydrofolate reductase; MTX = methotrexate; THF = tetrahydrofolic acid; TMP = trimethoprim

©UWorld

Zoom In | Zoom Out | Reset | Add To New Card | Existing Card

Settings

1
2
3
4
5
6
7
8
9
10

Item 4 of 10
Question Id: 15637

Mark | Previous | Next | Full Screen | Tutorial | Lab Values | Notes | Calculator | Reverse Color | Text Zoom | Settings

spina bifida).

Exhibit Display

Zoom In | Zoom Out | Reset | Add To New Card | Existing Card

Subject System Topic

Block Time Remaining: 00:00:12
TUTOR

5 | Feedback | Suspend | End Block

Settings

1
2
3
4
5
6
7
8
9
10

Item 5 of 10
Question Id: 496

Mark | Previous | Next | Full Screen | Tutorial | Lab Values | Notes | Calculator | Reverse Color | Text Zoom | Settings

A newborn is examined in the delivery room shortly after being born vaginally to a 38-year-old woman. The mother had intermittent prenatal care, and the pregnancy was complicated by bipolar disorder and chronic hypertension. Interview of the mother reveals pressured and tangential speech. She states, "I take my prescribed meds when I remember," and then adds, "I have a good memory, and I took the meds most of the time throughout the pregnancy." She claims to have smoked cigarettes occasionally but then changes the subject when asked if other substances were used during pregnancy. Examination of the neonate shows a nondysmorphic face and a mass overlying the lower spine that is covered with a patch of hair. Which of the following interventions in the mother could have most likely prevented this neonate's abnormalities?

A. Antenatal steroid therapy
B. Avoiding alcohol consumption
C. Increasing dose of mood stabilizer
D. Lowering dose of antihypertensive drug
E. Smoking cessation
F. Vitamin supplementation

Submit

Block Time Remaining: 00:00:12
TUTOR

6 | Feedback | Suspend | End Block

A newborn is examined in the delivery room shortly after being born vaginally to a 38-year-old woman. The mother had intermittent prenatal care, and the pregnancy was complicated by bipolar disorder and chronic hypertension. Interview of the mother reveals pressured and tangential speech. She states, "I take my prescribed meds when I remember," and then adds, "I have a good memory, and I took the meds most of the time throughout the pregnancy." She claims to have smoked cigarettes occasionally but then changes the subject when asked if other substances were used during pregnancy. Examination of the neonate shows a nondysmorphic face and a mass overlying the lower spine that is covered with a patch of hair. Which of the following interventions in the mother could have most likely prevented this neonate's abnormalities?

- A. Antenatal steroid therapy (0%)
- B. Avoiding alcohol consumption (3%)
- C. Increasing dose of mood stabilizer (0%)
- D. Lowering dose of antihypertensive drug (0%)
- E. Smoking cessation (1%)
- ✓ F. Vitamin supplementation (94%)

Omitted
Correct answer
F

94%
Answered correctly

02 secs
Time Spent

03/23/2020
Last Updated

Explanation

Neural tube formation

Neural tube formation

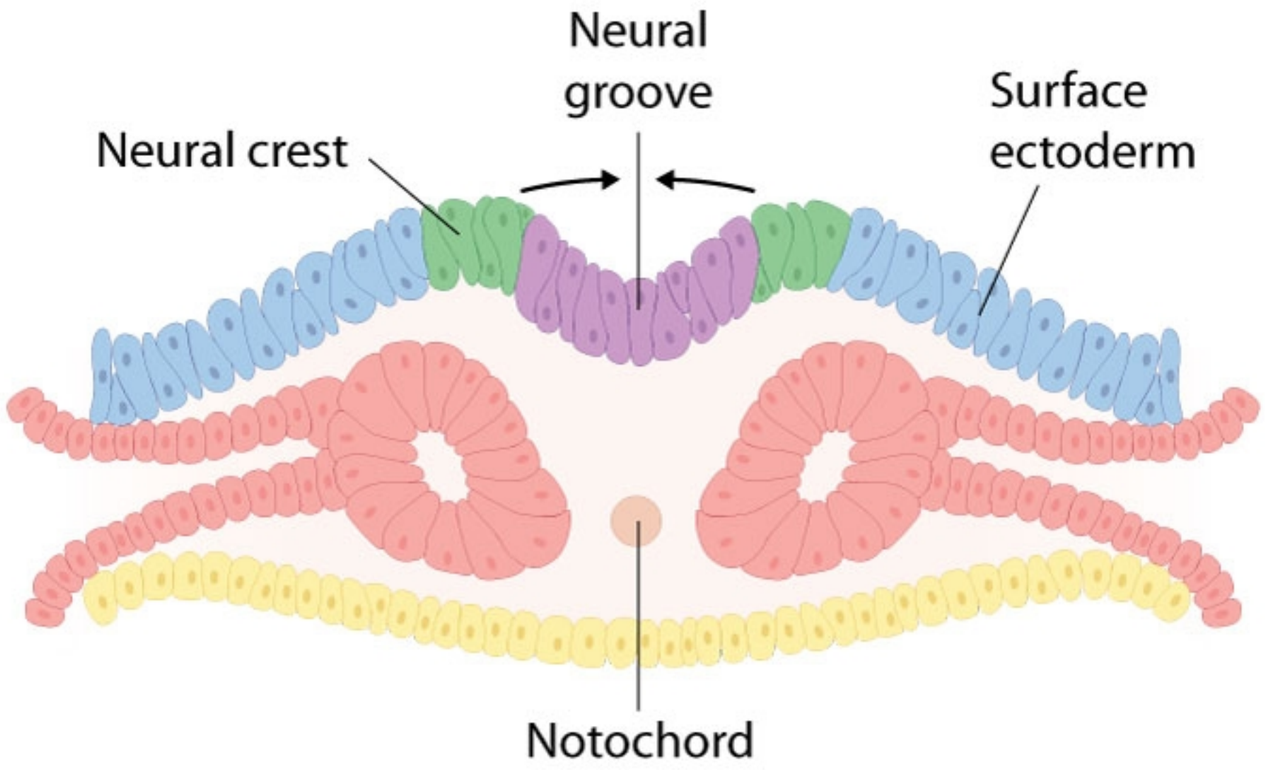

19 days

Neural fold

Settings

1
2
3
4
5
6
7
8
9
10

Item 5 of 10
Question Id: 496

Mark | Previous | Next | Full Screen | Tutorial | Lab Values | Notes | Calculator | Reverse Color | Text Zoom | Settings

19 days

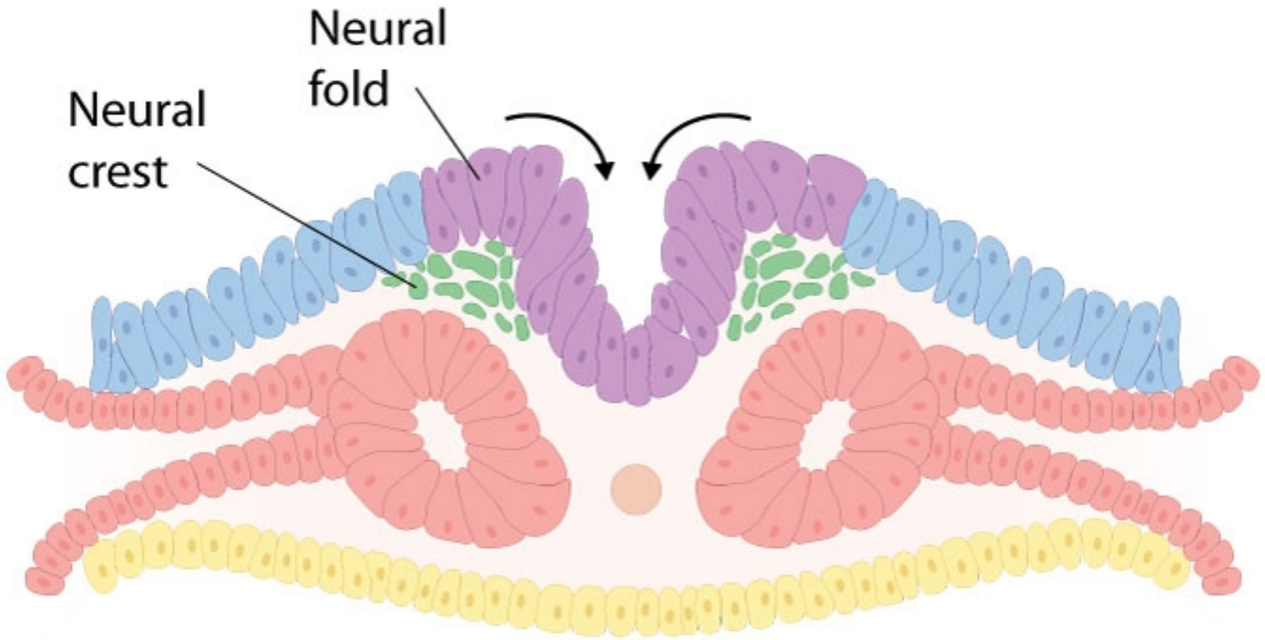

20 days

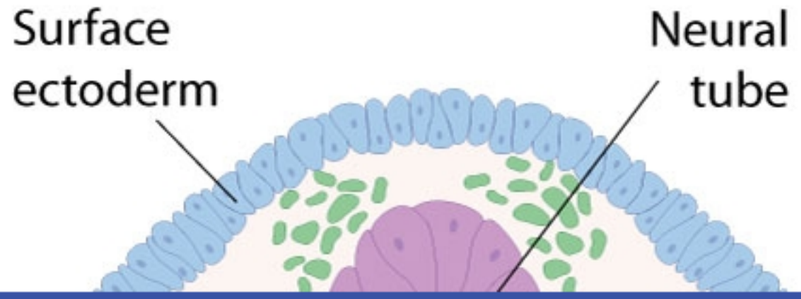

Block Time Remaining: 00:00:14
TUTOR

6 | Feedback | Suspend | End Block

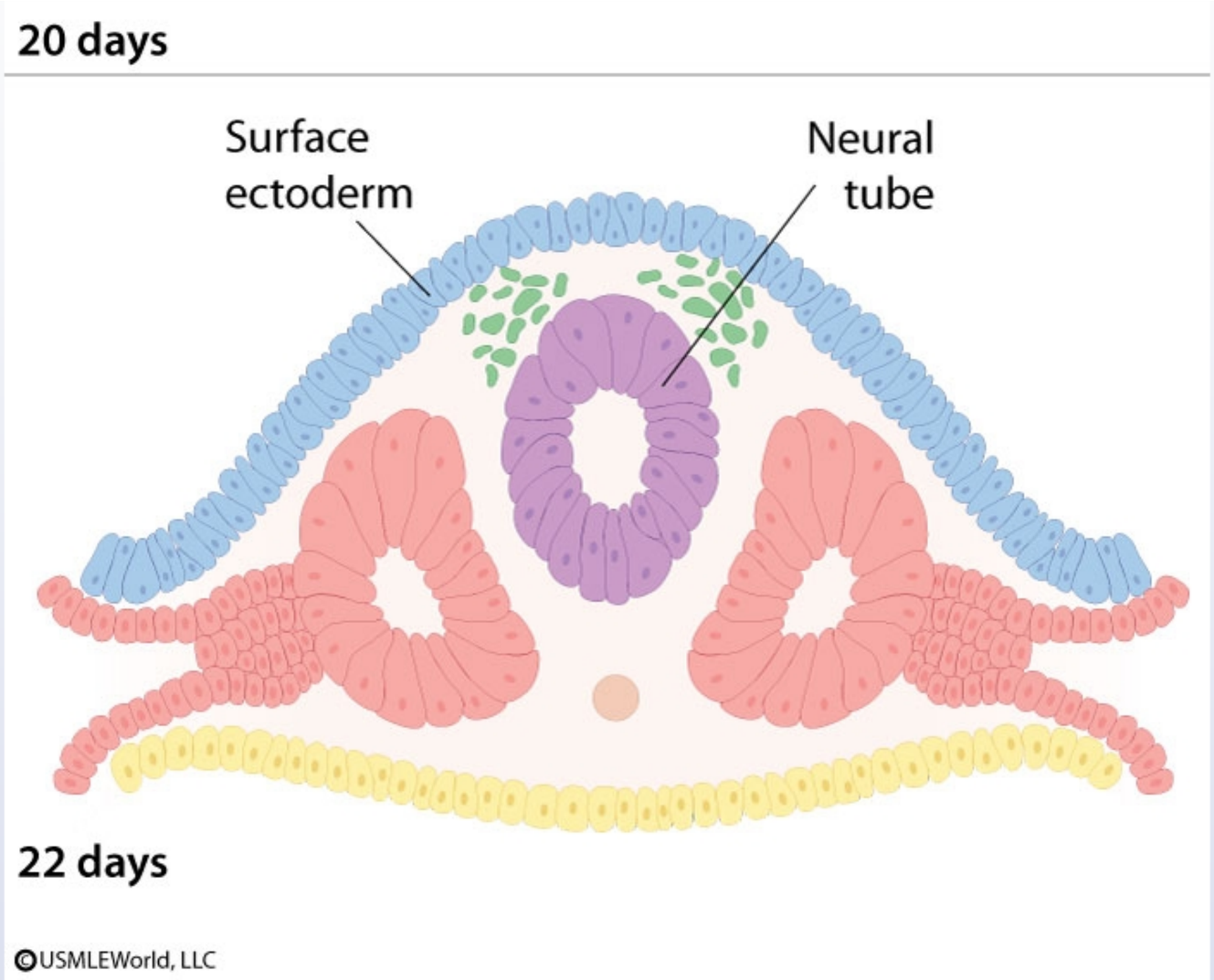

Midline fusion of neural folds creates the neural tube during the third week of fetal life. The neural tube is a structure that is connected to the amniotic cavity by openings at the ends known as anterior and posterior neuropores. Failure of neuropore closure by 4 weeks gestation leads to

Settings

1
2
3
4
5
6
7
8
9
10

Item 5 of 10
Question Id: 496

Mark | Previous | Next | Full Screen | Tutorial | Lab Values | Notes | Calculator | Reverse Color | Text Zoom | Settings

Explanation

Exhibit Display

Neural tube formation

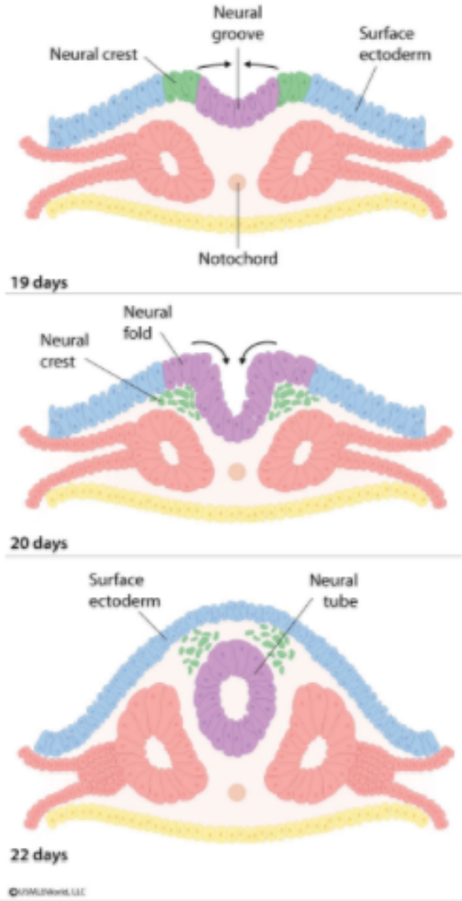

Zoom In | Zoom Out | Reset | Add To New Card | Existing Card

Block Time Remaining: 00:00:14
TUTOR

6 | Feedback | Suspend | End Block

Midline fusion of neural folds creates the neural tube during the third week of fetal life. The neural tube is a structure that is connected to the amniotic cavity by openings at the ends known as anterior and posterior neuropores. Failure of neuropore closure by 4 weeks gestation leads to **neural tube defects** (NTDs). Anterior NTDs include anencephaly (complete absence of the brain) and encephalocele (protrusion of neural tissue through the cranial defect). Posterior NTDs include spina bifida occulta, meningocele, and meningomyelocele. Meningocele and meningomyelocele present as a **cystic mass at the lower spine** that is covered with skin and sometimes a **tuft of hair** (seen in this patient). A meningocele consists of spinal meninges that protrude through the vertebral arch defect. A meningomyelocele has portions of the spinal cord or cauda equina within the protruding meningeal sac.

Folate (vitamin B_9) supplementation reduces risk of NTDs and is recommended for all women of childbearing age because the neural tube develops during the time when most women are unaware of their pregnancy. Prenatal **valproate** use for **bipolar disorder** (likely in this patient) or **epilepsy** is associated with a 10- to 20-fold increased risk of NTDs due to impaired folate metabolism. Other risk factors include maternal use of folate antagonists (eg, methotrexate, trimethoprim-sulfamethoxazole).

(Choice A) Antenatal steroid therapy (eg, betamethasone) reduces the incidence of neonatal respiratory distress syndrome in premature infants. It does not increase risk of NTDs.

(Choice B) Although chronic alcohol consumption can result in folate deficiency (and therefore NTDs), it is more commonly associated with fetal alcohol syndrome. However, fetal alcohol syndrome is unlikely in the absence of short palpebral fissures, a thin vermilion border, and a smooth philtrum.

(Choice C) Lithium and valproate are first-line drugs for acute mania. If valproate cannot be substituted by another drug to control a mood or epilepsy disorder, the lowest effective dose should be prescribed during pregnancy. Lithium use in pregnancy is also not recommended due to its association with increased incidence of Ebstein anomaly.

(Choices D and E) Uncontrolled hypertension and tobacco use can cause fetal growth restriction, premature delivery, and placental abruption. Tobacco use, hypertension, and antihypertensive medications are not associated with NTDs.

Educational objective:
Failure of neural tube closure at 4 weeks gestation results in neural tube defects (NTDs). First trimester use of valproate is a significant risk factor for NTDs, but periconceptional folate (vitamin B_9) supplementation reduces this risk.

Folate (vitamin B_9) supplementation reduces risk of NTDs and is recommended for all women of childbearing age because the neural tube develops during the time when most women are unaware of their pregnancy. Prenatal **valproate** use for **bipolar disorder** (likely in this patient) or **epilepsy** is associated with a 10- to 20-fold increased risk of NTDs due to impaired folate metabolism. Other risk factors include maternal use of folate antagonists (eg, methotrexate, trimethoprim-sulfamethoxazole).

(Choice A) Antenatal steroid therapy (eg, betamethasone) reduces the incidence of neonatal respiratory distress syndrome in premature infants. It does not increase risk of NTDs.

(Choice B) Although chronic alcohol consumption can result in folate deficiency (and therefore NTDs), it is more commonly associated with fetal alcohol syndrome. However, fetal alcohol syndrome is unlikely in the absence of short palpebral fissures, a thin vermilion border, and a smooth philtrum.

(Choice C) Lithium and valproate are first-line drugs for acute mania. If valproate cannot be substituted by another drug to control a mood or epilepsy disorder, the lowest effective dose should be prescribed during pregnancy. Lithium use in pregnancy is also not recommended due to its association with increased incidence of Ebstein anomaly.

(Choices D and E) Uncontrolled hypertension and tobacco use can cause fetal growth restriction, premature delivery, and placental abruption. Tobacco use, hypertension, and antihypertensive medications are not associated with NTDs.

Educational objective:
Failure of neural tube closure at 4 weeks gestation results in neural tube defects (NTDs). First trimester use of valproate is a significant risk factor for NTDs, but periconceptional folate (vitamin B_9) supplementation reduces this risk.

References

- Effects and safety of periconceptional oral folate supplementation for preventing birth defects

Embryology	Nervous System	Neural tube defects
Subject	System	Topic

Copyright © UWorld. All rights reserved.

Settings

1
2
3
4
5
6
7
8
9
10

Item 5 of 10
Question Id: 496

Mark | Previous | Next | Full Screen | Tutorial | Lab Values | Notes | Calculator | Reverse Color | Text Zoom | Settings

Exhibit Display

Zoom In | Zoom Out | Reset | Add To New Card | Existing Card

(Choice C) Lithium and valproate are first-line drugs for acute mania. If valproate cannot be substituted by another drug to control a mood or

Block Time Remaining: 00:00:14
TUTOR

6 | Feedback | Suspend | End Block

Exhibit Display

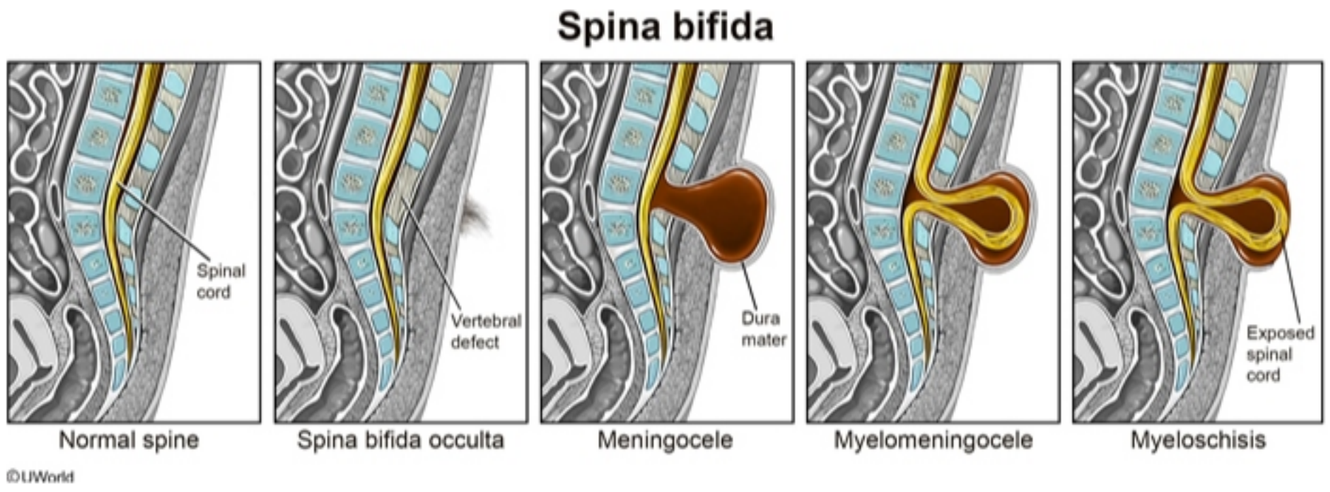

Zoom In | Zoom Out | Reset | Add To New Card | Existing Card

(Choice C) Lithium and valproate are first-line drugs for acute mania. If valproate cannot be substituted by another drug to control a mood or

Settings

1
2
3
4
5
6
7
8
9
10

Item 5 of 10
Question Id: 496

Mark | Previous | Next | Full Screen | Tutorial | Lab Values | Notes | Calculator | Reverse Color | Text Zoom | Settings

Exhibit Display

Fetal alcohol syndrome

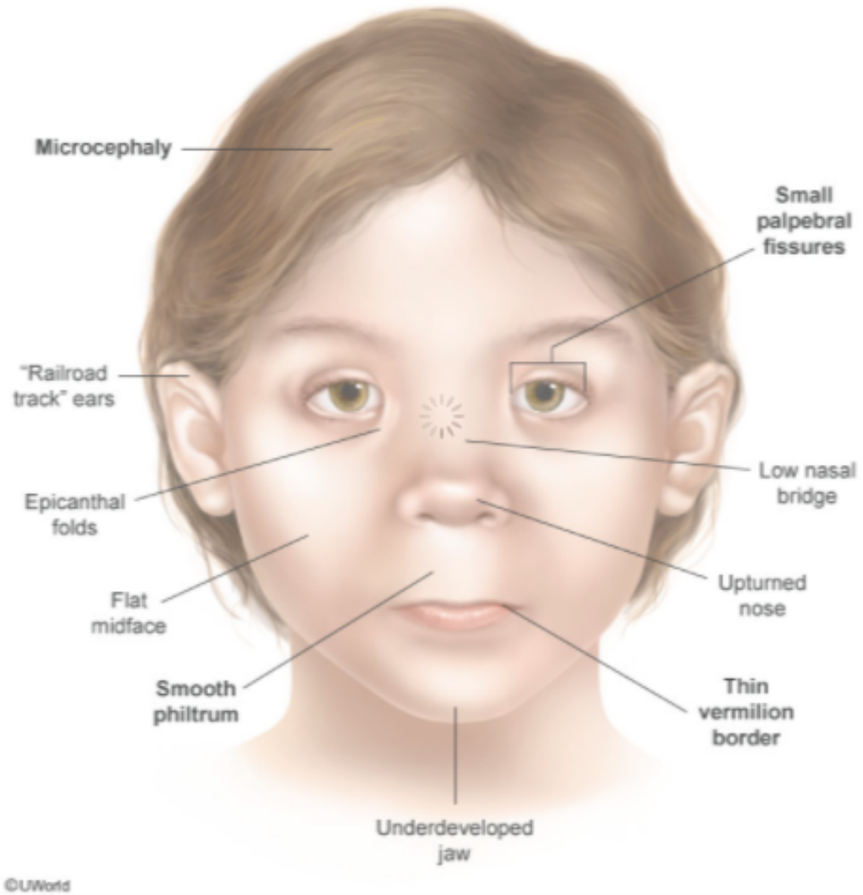

Zoom In | Zoom Out | Reset | Add To New Card | Existing Card

(Choice C) Lithium and valproate are first-line drugs for acute mania. If valproate cannot be substituted by another drug to control a mood or

Block Time Remaining: 00:00:14
TUTOR

6 | Feedback | Suspend | End Block

Folate (vitamin B_9) supplementation reduces risk of NTDs and is recommended for all women of childbearing age because the neural tube

Exhibit Display

Ebstein's anomaly

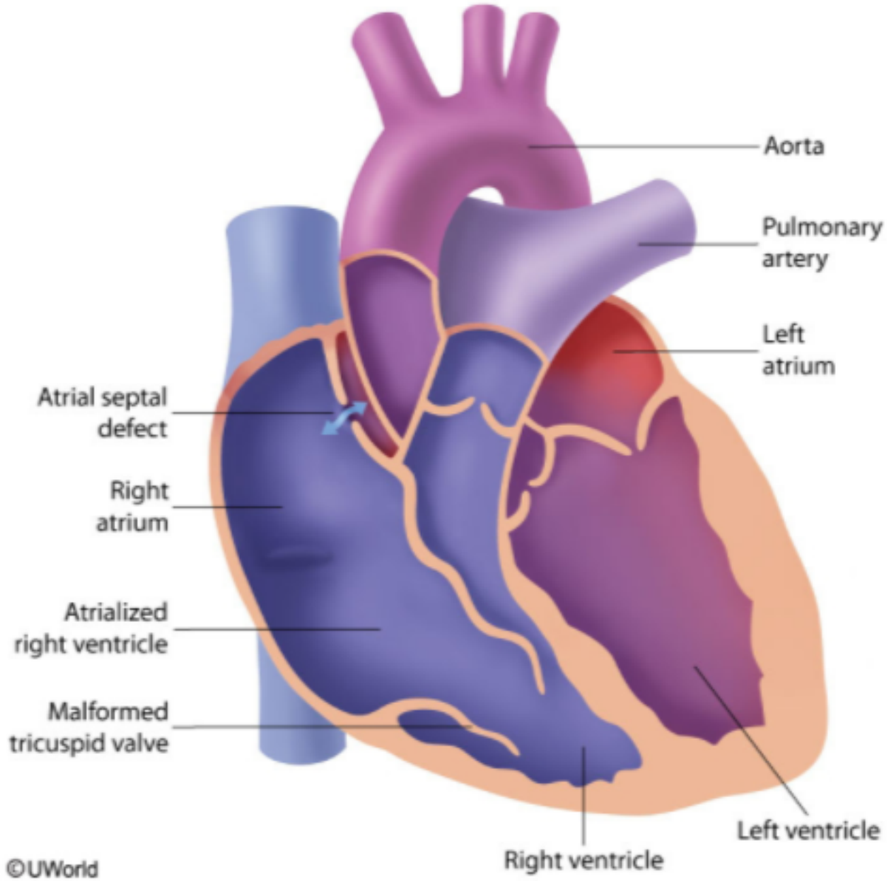

Zoom In | Zoom Out | Reset | Add To New Card | Existing Card

Settings

1
2
3
4
5
6
7
8
9
10

Item 6 of 10
Question Id: 502

Mark | Previous | Next | Full Screen | Tutorial | Lab Values | Notes | Calculator | Reverse Color | Text Zoom | Settings

A 35-year-old woman, gravida 2 para 1, comes to the office for a routine prenatal visit. Her first child was born with a hydrocele and syndactyly of the first and second toes. The patient has no significant medical problems and takes no medications except for a multivitamin. Examination reveals clear lungs and normal first and second heart sounds. The abdomen is soft and nontender. Uterine size, fetal movements, and fetal cardiac activity are all within appropriate limits. The patient undergoes amniocentesis during the 18th week of pregnancy. Amniotic fluid analysis shows an increased level of acetylcholinesterase. This patient's amniocentesis results most likely suggest failure of which of the following processes?

A. Epithelial cell apoptosis in the embryonic duodenum
B. Fusion of the edges of the neural plate
C. Involution of the thyroglossal duct
D. Meiotic disjunction of chromosome 21
E. Migration of neural crest cells
F. Obliteration of the processus vaginalis

Submit

Block Time Remaining: 00:00:16
TUTOR

4 | Feedback | Suspend | End Block

A 35-year-old woman, gravida 2 para 1, comes to the office for a routine prenatal visit. Her first child was born with a hydrocele and syndactyly of the first and second toes. The patient has no significant medical problems and takes no medications except for a multivitamin. Examination reveals clear lungs and normal first and second heart sounds. The abdomen is soft and nontender. Uterine size, fetal movements, and fetal cardiac activity are all within appropriate limits. The patient undergoes amniocentesis during the 18th week of pregnancy. Amniotic fluid analysis shows an increased level of acetylcholinesterase. This patient's amniocentesis results most likely suggest failure of which of the following processes?

- A. Epithelial cell apoptosis in the embryonic duodenum (5%)
- ✓ B. Fusion of the edges of the neural plate (57%)
- C. Involution of the thyroglossal duct (2%)
- D. Meiotic disjunction of chromosome 21 (13%)
- E. Migration of neural crest cells (16%)
- F. Obliteration of the processus vaginalis (3%)

Omitted
Correct answer
B

57%
Answered correctly

02 secs
Time Spent

04/30/2020
Last Updated

Explanation

Neural tube formation

Settings

1
2
3
4
5
6
7
8
9
10

Item 6 of 10
Question Id: 502

Mark | Previous | Next | Full Screen | Tutorial | Lab Values | Notes | Calculator | Reverse Color | Text Zoom | Settings

Neural tube formation

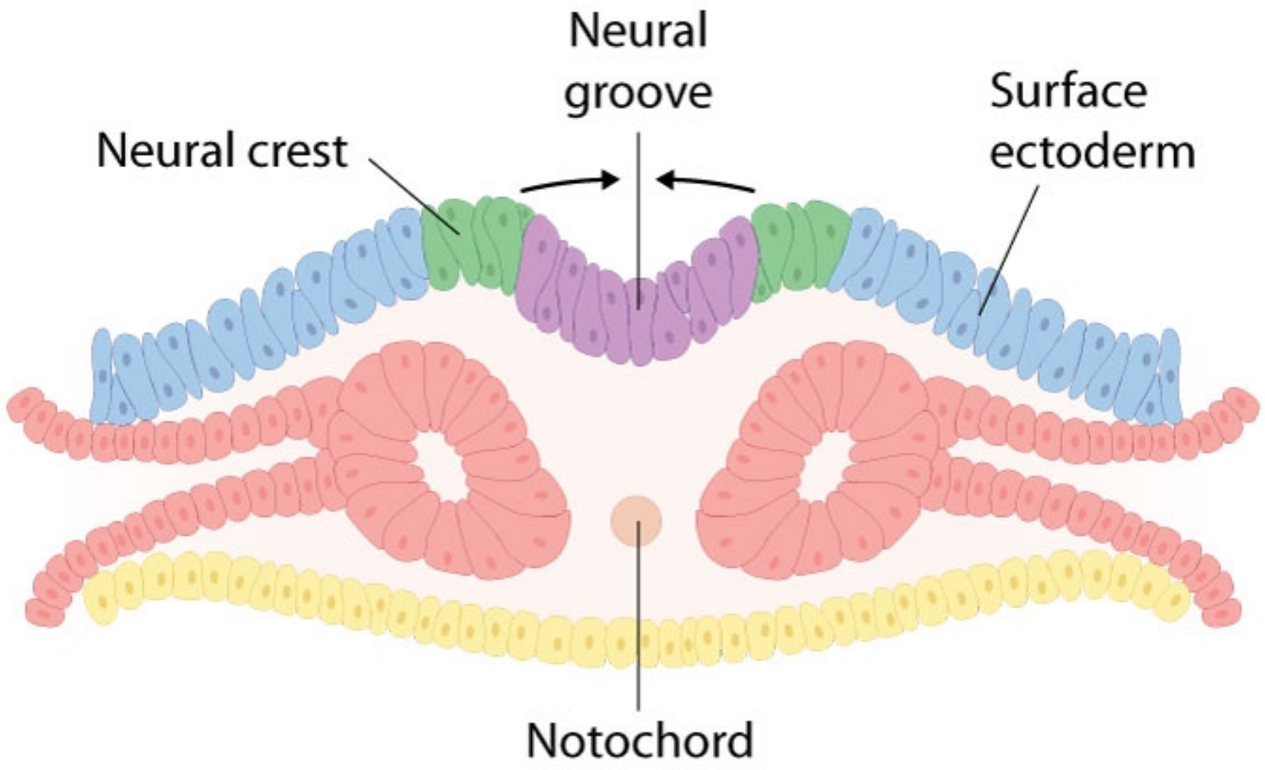

19 days

Neural fold

Block Time Remaining: 00:00:17
TUTOR

4 | Feedback | Suspend | End Block

Settings

1
2
3
4
5
6
7
8
9
10

Item 6 of 10
Question Id: 502

Mark | Previous | Next | Full Screen | Tutorial | Lab Values | Notes | Calculator | Reverse Color | Text Zoom | Settings

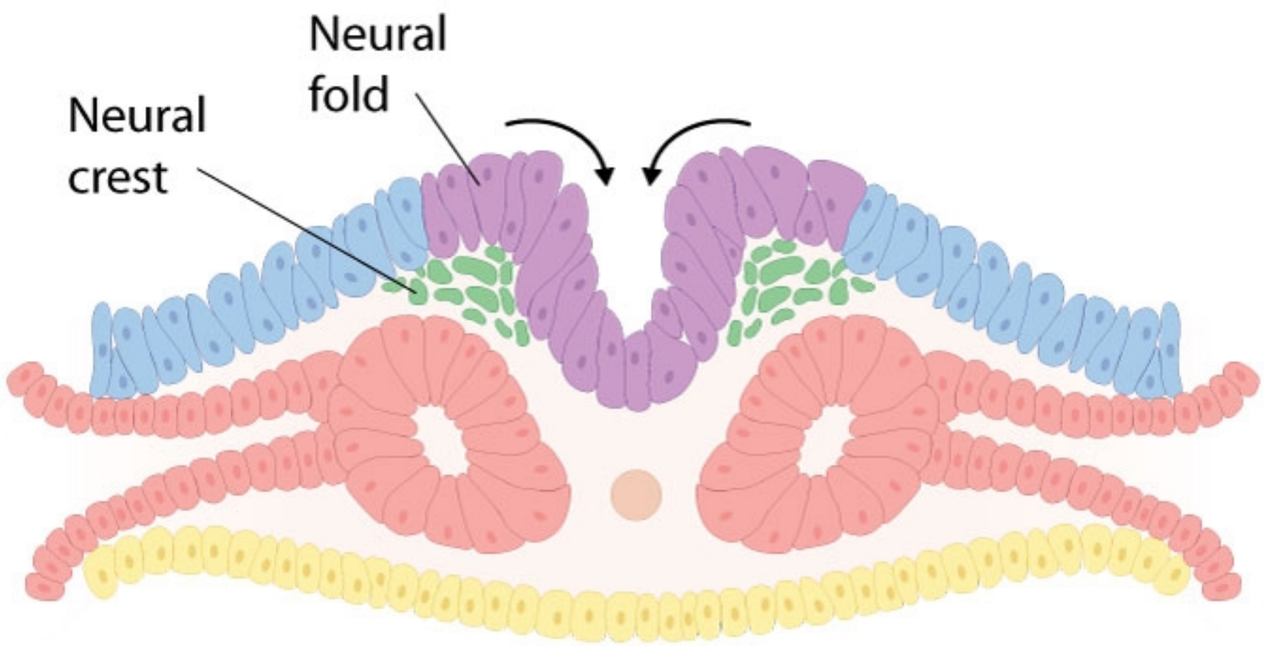

20 days

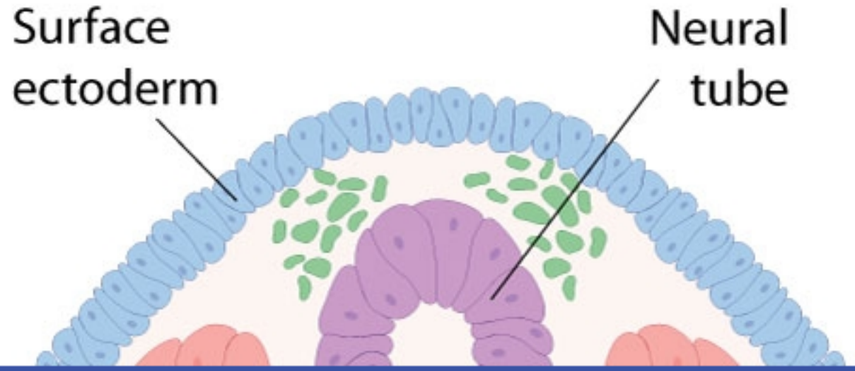

Block Time Remaining: 00:00:17
TUTOR

4 | Feedback | Suspend | End Block

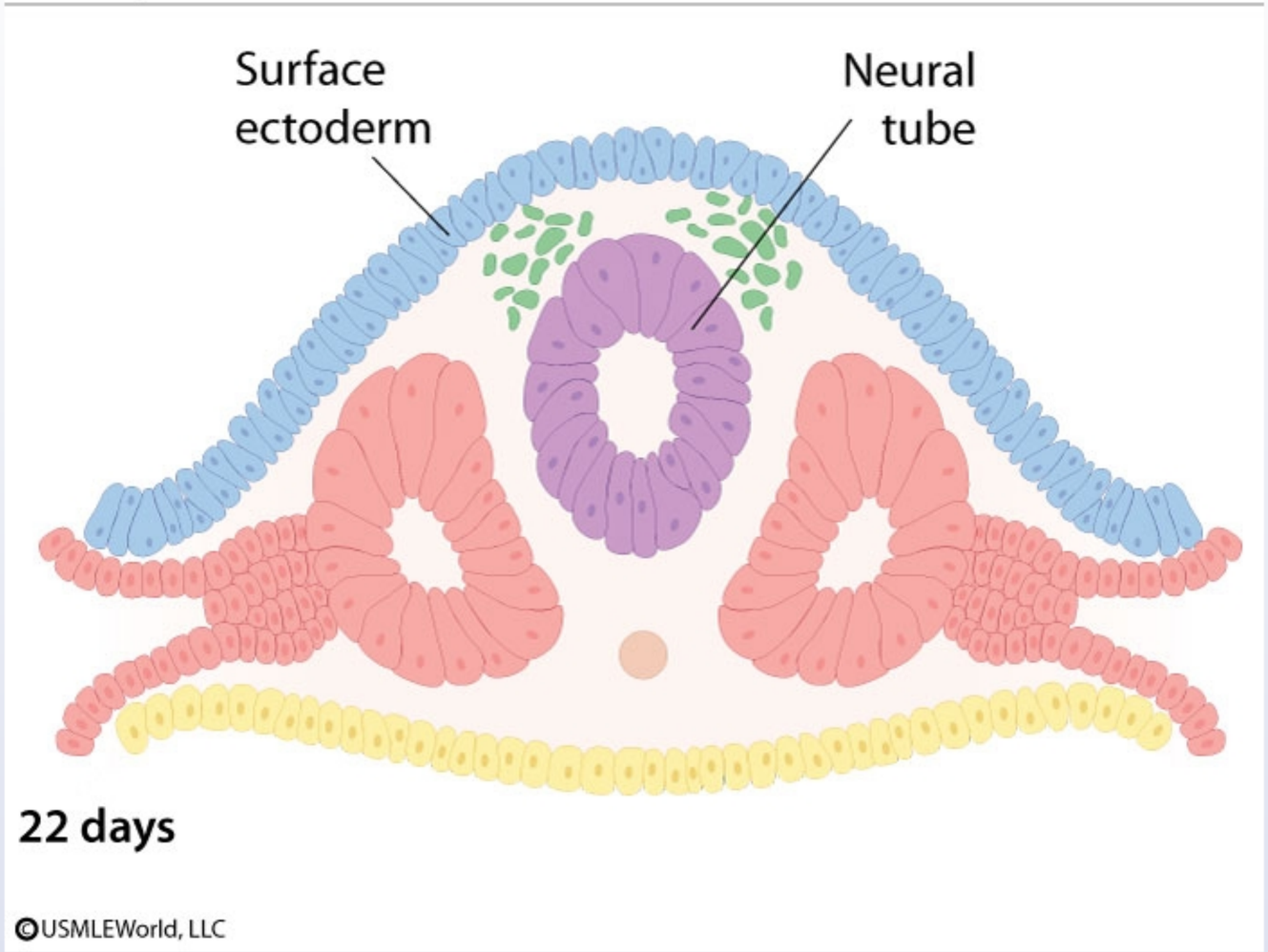

Neural tube defects (NTDs) occur due to **failure of fusion** of the neural plate edges during the 4th week of fetal development. Fusion begins in the cervical region and proceeds toward the cranial and caudal ends of the neural tube (ie, the rostral and caudal neuropores). Failure of the rostral neuropore to close results in **anencephaly**, whereas impaired closure of the caudal neuropore causes spina bifida. If either neuropore does not fuse, an opening persists between the neural tube and the amniotic cavity that allows leakage of **alpha fetoprotein** (AFP) and

Neural tube defects (NTDs) occur due to **failure of fusion** of the neural plate edges during the 4th week of fetal development. Fusion begins in the cervical region and proceeds toward the cranial and caudal ends of the neural tube (ie, the rostral and caudal neuropores). Failure of the rostral neuropore to close results in **anencephaly**, whereas impaired closure of the caudal neuropore causes spina bifida. If either neuropore does not fuse, an opening persists between the neural tube and the amniotic cavity that allows leakage of **alpha-fetoprotein** (AFP) and **acetylcholinesterase** (AChE) into the amniotic fluid. AFP can also cross the placenta and is detectable in the maternal serum. Detection of AFP and AChE is used for prenatal screening of NTDs (eg, spina bifida cystica, anencephaly).

(Choice A) Duodenal atresia is a result of impaired recanalization of the duodenal lumen due to failure of epithelial cell apoptosis during fetal life. Although it can cause increased levels of amniotic fluid (ie, polyhydramnios), it is not associated with elevated levels of AChE. The first child's syndactyly is also an example of failed apoptosis of mesenchyme between the digits.

(Choice C) Failed involution of the thyroglossal tract can lead to formation of a persistent thyroglossal duct cyst. It typically presents as a painless midline mass close to the body of the hyoid bone. Amnionic fluid AChE level is not elevated.

(Choice D) Chromosomal disjunction during meiosis involves separation of 23 pairs of homologous chromosomes in anaphase I, followed by separation of 23 pairs of sister chromatids during anaphase II. Advanced maternal age is a risk factor for Down syndrome (nondisjunction of chromosome 21), which presents with low AFP and normal AChE levels in the amniotic fluid.

(Choice E) Hirschsprung disease involves failure of neural crest cells to migrate into the sigmoid colon/rectum. It leads to absence of the myenteric and submucosal nervous plexuses, causing tonic constriction of the affected intestinal segments with consequent bilious emesis, abdominal distension, and failure to pass meconium.

(Choice F) Failure of the processus vaginalis to obliterate can lead to congenital hydrocele or indirect inguinal hernia. Neither condition is associated with increased amniotic AChE levels.

Educational objective:
Neural tube defects most often occur when the neural folds fail to fuse in the region of the anterior or posterior neuropores. Persistent communication between the spinal canal and the amniotic cavity allows leakage of alpha-fetoprotein (AFP) and acetylcholinesterase (AChE) into the amnionic fluid, leading to elevated levels of AFP and AChE that can be detected on amniocentesis.

(Choice A) Duodenal atresia is a result of impaired recanalization of the duodenal lumen due to failure of epithelial cell apoptosis during fetal life. Although it can cause increased levels of amniotic fluid (ie, polyhydramnios), it is not associated with elevated levels of AChE. The first child's syndactyly is also an example of failed apoptosis of mesenchyme between the digits.

(Choice C) Failed involution of the thyroglossal tract can lead to formation of a persistent thyroglossal duct cyst. It typically presents as a painless midline mass close to the body of the hyoid bone. Amnionic fluid AChE level is not elevated.

(Choice D) Chromosomal disjunction during meiosis involves separation of 23 pairs of homologous chromosomes in anaphase I, followed by separation of 23 pairs of sister chromatids during anaphase II. Advanced maternal age is a risk factor for Down syndrome (nondisjunction of chromosome 21), which presents with low AFP and normal AChE levels in the amniotic fluid.

(Choice E) Hirschsprung disease involves failure of neural crest cells to migrate into the sigmoid colon/rectum. It leads to absence of the myenteric and submucosal nervous plexuses, causing tonic constriction of the affected intestinal segments with consequent bilious emesis, abdominal distension, and failure to pass meconium.

(Choice F) Failure of the processus vaginalis to obliterate can lead to congenital hydrocele or indirect inguinal hernia. Neither condition is associated with increased amniotic AChE levels.

Educational objective:
Neural tube defects most often occur when the neural folds fail to fuse in the region of the anterior or posterior neuropores. Persistent communication between the spinal canal and the amniotic cavity allows leakage of alpha-fetoprotein (AFP) and acetylcholinesterase (AChE) into the amnionic fluid, leading to elevated levels of AFP and AChE that can be detected on amniocentesis.

References

- Mechanisms of tissue fusion during development.

Embryology	Nervous System	Neural tube defects
Subject	System	Topic

Copyright © UWorld. All rights reserved.

A 2-day-old infant is dusky and irritable. He was born to a 22-year-old primigravida with sporadic prenatal care. Delivery was uncomplicated, and Apgar scores were 7 and 8 at 1 and 5 minutes, respectively. His temperature is 36.7 C (98 F), blood pressure is 70/30 mm Hg, pulse is 148/min, and respiratory rate is 68/min. Physical examination shows a cyanotic and irritable newborn with mild-to-moderate respiratory distress. Auscultation reveals a continuous, machine-like murmur appreciated between the scapulae. Serum lactate is elevated. Echocardiogram shows the aorta lying anterior, inferior, and to the right of the pulmonary artery. Failure of which of the following embryologic processes is most likely responsible for this patient's condition?

- A. Apoptosis
- B. Fusion
- C. Obliteration
- D. Proliferation
- E. Septation
- F. Spiraling

Submit

A 2-day-old infant is dusky and irritable. He was born to a 22-year-old primigravida with sporadic prenatal care. Delivery was uncomplicated, and Apgar scores were 7 and 8 at 1 and 5 minutes, respectively. His temperature is 36.7 C (98 F), blood pressure is 70/30 mm Hg, pulse is 148/min, and respiratory rate is 68/min. Physical examination shows a cyanotic and irritable newborn with mild-to-moderate respiratory distress. Auscultation reveals a continuous, machine-like murmur appreciated between the scapulae. Serum lactate is elevated. Echocardiogram shows the aorta lying anterior, inferior, and to the right of the pulmonary artery. Failure of which of the following embryologic processes is most likely responsible for this patient's condition?

A. Apoptosis (2%)

B. Fusion (4%)

C. Obliteration (12%)

D. Proliferation (0%)

E. Septation (10%)

✓ F. Spiraling (68%)

Omitted
Correct answer
F

68%
Answered correctly

03 secs
Time Spent

04/06/2020
Last Updated

Explanation

Formation of aorta, pulmonary trunk, & interventricular septum

Formation of aorta, pulmonary trunk, & interventricular septum

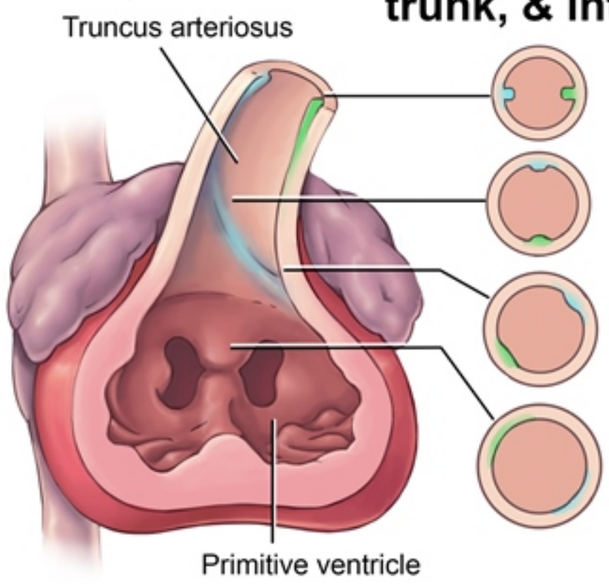

1. Ridges appear at opposite sides of truncal lumen

2. Truncal ridges grow toward each other

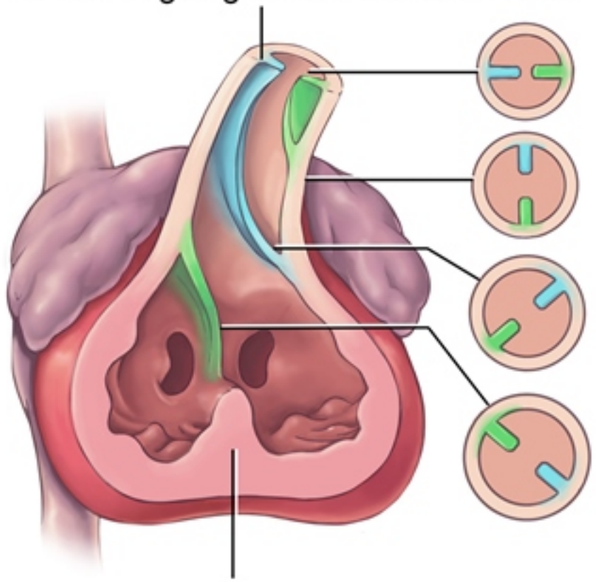

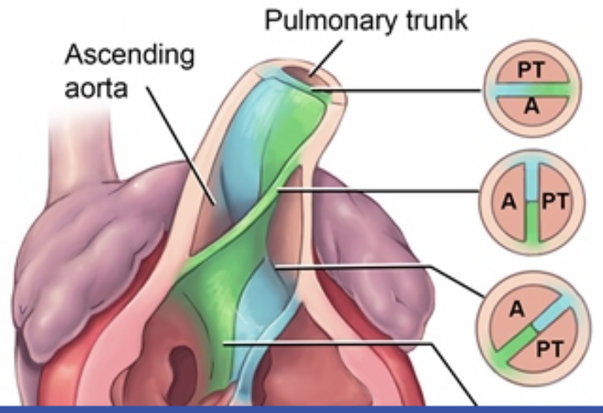

3. Cells at ventricle base grow toward endocardial cushions, and form the muscular part of the interventricular septum

Settings

1
2
3
4
5
6
7
8
9
10

Item 7 of 10
Question Id: 35

Mark | Previous | Next | Full Screen | Tutorial | Lab Values | Notes | Calculator | Reverse Color | Text Zoom | Settings

Exhibit Display

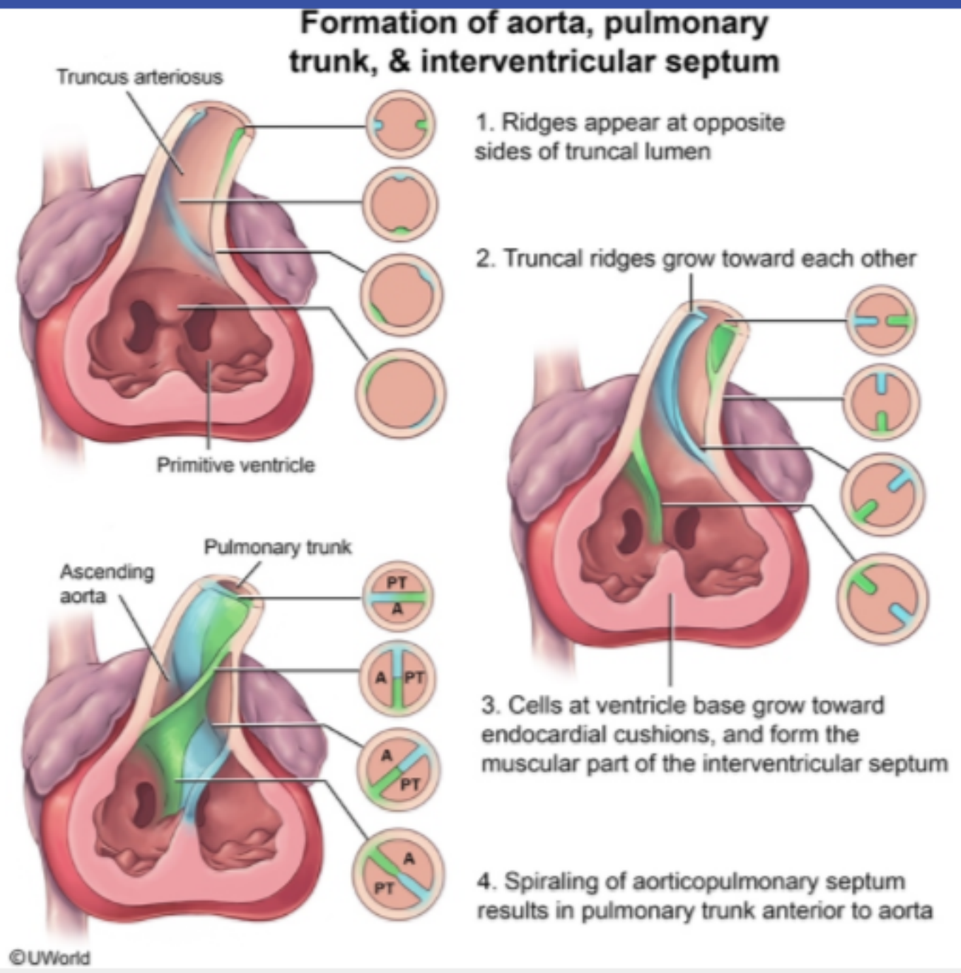

Zoom In | Zoom Out | Reset | Add To New Card | Existing Card

Block Time Remaining: 00:00:19
TUTOR

7 | Feedback | Suspend | End Block

The clinical and echocardiographic findings in this cyanotic neonate are consistent with transposition of the great arteries (TGA). The etiology of TGA is due to linear (rather than spiral) **development of the aorticopulmonary septum** in utero, resulting in an anteriorly positioned aorta connected to the right ventricle and a posteriorly positioned pulmonary artery connected to the left ventricle. Therefore, pulmonary and systemic circulations are abnormally separated and exist as 2 **parallel circulations**.

TGA is incompatible with life unless there is another coexisting connection, such as a patent foramen ovale, septal defect, or **patent ductus arteriosus** (PDA), to allow **mixing** of oxygenated pulmonary circulation blood with the systemic circulation. Patients may be normal on initial presentation but will become cyanotic, tachypneic, and tachycardic as the PDA (machine-like murmur) begins to close, which typically occurs at age 1-3 days. Elevated lactate in this patient signifies anaerobic metabolism in the presence of poorly oxygenated blood.

(Choice A) Failure of apoptosis of the tissue between the digits can result in syndactyly.

(Choice B) Failure of fusion is seen in hypospadias (failure of urethral folds to fuse).

(Choice C) A branchial cleft cyst results from failure of obliteration of the second branchial cleft. The cysts usually present as a draining sinus at the angle of the mandible.

(Choice D) The membranous portion of the interventricular septum results from proliferation of endocardial cushions. Failure of this proliferation leads to a membranous ventricular septal defect (VSD) that can present as a holosystolic murmur if small, or cyanosis if large. However, the aorta should lie posterior to the pulmonary artery (the normal configuration).

(Choice E) Failure of conotruncal septation results in persistent truncus arteriosus, which can present with cyanosis and respiratory distress, although an echocardiogram will show a single arterial trunk overriding a large VSD.

Educational objective:
An echocardiogram showing an aorta lying anterior to the pulmonary artery is diagnostic of transposition of the great arteries (TGA). This life-threatening cyanotic condition results from failure of the fetal aorticopulmonary septum to spiral normally during septation of the truncus arteriosus.

References

- Clinical presentations of critical cardiac defects in the newborn: Decision making and initial management.

TGA is incompatible with life unless there is another coexisting connection, such as a patent foramen ovale, septal defect, or **patent ductus arteriosus** (PDA), to allow **mixing** of oxygenated pulmonary circulation blood with the systemic circulation. Patients may be normal on initial presentation but will become cyanotic, tachypneic, and tachycardic as the PDA (machine-like murmur) begins to close, which typically occurs at age 1-3 days. Elevated lactate in this patient signifies anaerobic metabolism in the presence of poorly oxygenated blood.

(Choice A) Failure of apoptosis of the tissue between the digits can result in syndactyly.

(Choice B) Failure of fusion is seen in hypospadias (failure of urethral folds to fuse).

(Choice C) A branchial cleft cyst results from failure of obliteration of the second branchial cleft. The cysts usually present as a draining sinus at the angle of the mandible.

(Choice D) The membranous portion of the interventricular septum results from proliferation of endocardial cushions. Failure of this proliferation leads to a membranous ventricular septal defect (VSD) that can present as a holosystolic murmur if small, or cyanosis if large. However, the aorta should lie posterior to the pulmonary artery (the normal configuration).

(Choice E) Failure of conotruncal septation results in persistent truncus arteriosus, which can present with cyanosis and respiratory distress, although an echocardiogram will show a single arterial trunk overriding a large VSD.

Educational objective:
An echocardiogram showing an aorta lying anterior to the pulmonary artery is diagnostic of transposition of the great arteries (TGA). This life-threatening cyanotic condition results from failure of the fetal aorticopulmonary septum to spiral normally during septation of the truncus arteriosus.

References

- Clinical presentations of critical cardiac defects in the newborn: Decision making and initial management.

Embryology	Cardiovascular System	Transposition of the great vessels
Subject	System	Topic

Copyright © UWorld. All rights reserved.

Settings

1
2
3
4
5
6
7
8
9
10

Item 8 of 10
Question Id: 1691

Mark | Previous | Next | Full Screen | Tutorial | Lab Values | Notes | Calculator | Reverse Color | Text Zoom | Settings

A newborn is taken to the neonatal intensive care unit after delivery due to respiratory distress. The neonate was born full-term, and there were no significant complications during pregnancy or delivery. Once the patient is stabilized, a detailed physical examination is performed. The neonate has an underdeveloped mandible and hypoplastic zygomatic bones. Genetic testing confirms a gene mutation that results in abnormal development of the first and second pharyngeal arches. Which of the following structures is also likely abnormal in this patient?

- A. Cricoid cartilage
- B. Glossopharyngeal nerve
- C. Greater horn of hyoid
- D. Stapes
- E. Thyroid cartilage
- F. Vagus nerve

Submit

Block Time Remaining: 00:00:19
TUTOR

3 | Feedback | Suspend | End Block

A newborn is taken to the neonatal intensive care unit after delivery due to respiratory distress. The neonate was born full-term, and there were no significant complications during pregnancy or delivery. Once the patient is stabilized, a detailed physical examination is performed. The neonate has an underdeveloped mandible and hypoplastic zygomatic bones. Genetic testing confirms a gene mutation that results in abnormal development of the first and second pharyngeal arches. Which of the following structures is also likely abnormal in this patient?

A. Cricoid cartilage
B. Glossopharyngeal nerve
C. Greater horn of hyoid
D. Stapes
E. Thyroid cartilage
F. Vagus nerve

Submit

A newborn is taken to the neonatal intensive care unit after delivery due to respiratory distress. The neonate was born full-term, and there were no significant complications during pregnancy or delivery. Once the patient is stabilized, a detailed physical examination is performed. The neonate has an underdeveloped mandible and hypoplastic zygomatic bones. Genetic testing confirms a gene mutation that results in abnormal development of the first and second pharyngeal arches. Which of the following structures is also likely abnormal in this patient?

- A. Cricoid cartilage (5%)
- B. Glossopharyngeal nerve (4%)
- C. Greater horn of hyoid (11%)
- ✓ D. Stapes (72%)
- E. Thyroid cartilage (5%)
- F. Vagus nerve (0%)

Omitted
Correct answer
D

72%
Answered correctly

03 secs
Time Spent

01/23/2020
Last Updated

Explanation

Settings

1
2
3
4
5
6
7
8
9
10

Item 8 of 10
Question Id: 1691

Mark | Previous | Next | Full Screen | Tutorial | Lab Values | Notes | Calculator | Reverse Color | Text Zoom | Settings

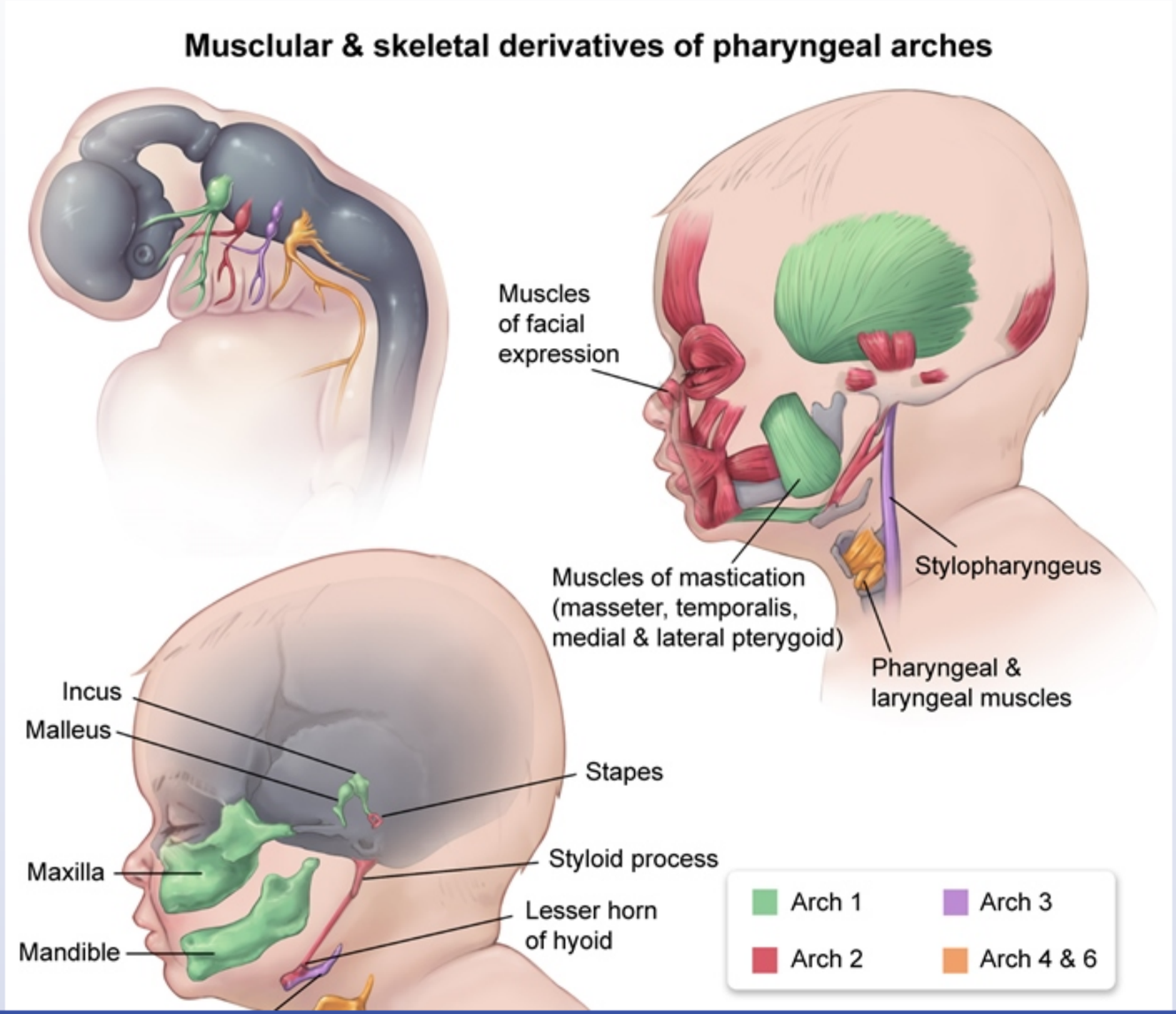

Block Time Remaining: 00:00:22
TUTOR

3 | Feedback | Suspend | End Block

Settings

1
2
3
4
5
6
7
8
9
10

Item 8 of 10
Question Id: 1691

Mark | Previous | Next | Full Screen | Tutorial | Lab Values | Notes | Calculator | Reverse Color | Text Zoom | Settings

Exhibit Display

Musclular & skeletal derivatives of pharyngeal arches

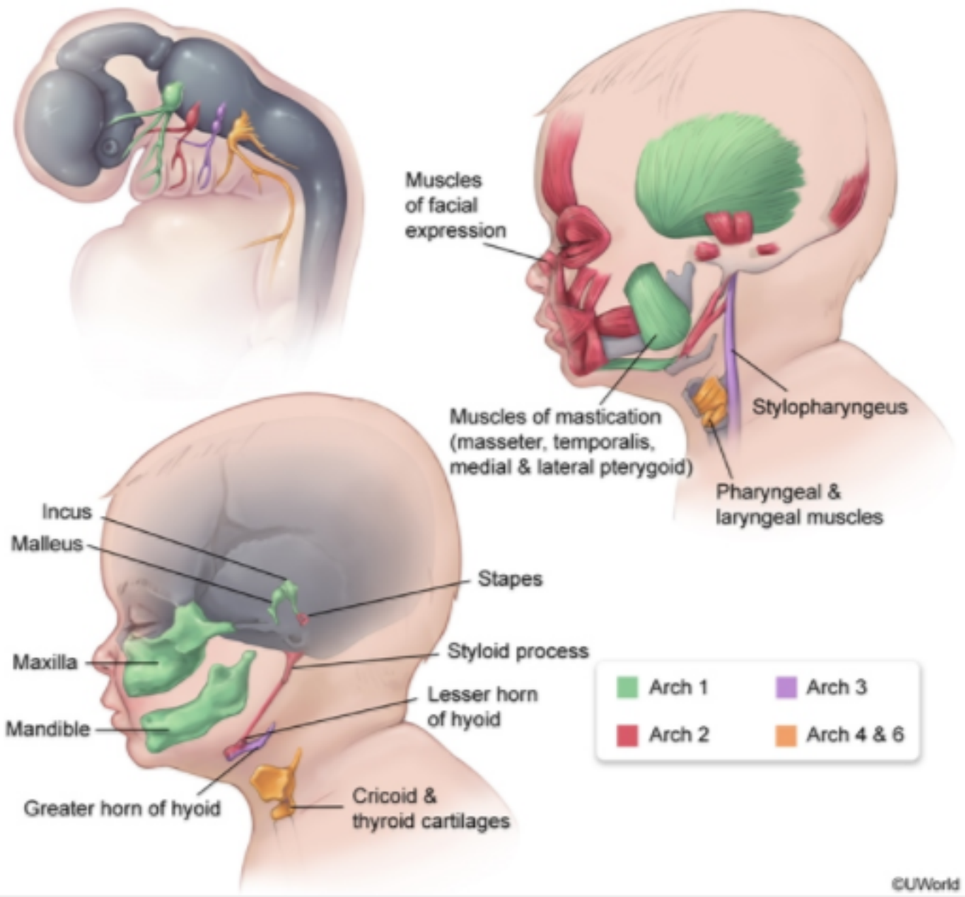

Zoom In | Zoom Out | Reset | Add To New Card | Existing Card

Block Time Remaining: 00:00:22
TUTOR

3 | Feedback | Suspend | End Block

The developing embryo has 6 pharyngeal or branchial arches, all but the fifth arch contribute to adult structures. The mesoderm forms muscular and vascular elements, and neural crest cells form the bony and cartilaginous structures. Each arch is also innervated by a specific cranial nerve (CN).

The **first pharyngeal arch** is associated with the trigeminal nerve (CN V). Its bony derivatives include the **maxilla, zygoma, mandible, incus,** and **malleus**; its muscular derivatives include the muscles of mastication (eg, masseter, temporalis). The **second pharyngeal arch** is associated with the facial nerve (CN VII) and gives rise to the **styloid process of the temporal bone, lesser horn of the hyoid,** and **stapes**. Muscular derivatives of the second arch include the muscles of facial expression.

This neonate's presentation is consistent with **Treacher-Collins syndrome** (TCS), a genetic disorder resulting in the abnormal development of the first and second pharyngeal arches. The craniofacial abnormalities (eg, mandibular, maxillary, and zygomatic bone hypoplasia) often result in airway compromise and feeding difficulties. In addition, absent or abnormal ossicles (eg, incus, malleus, stapes) lead to profound conductive hearing loss.

(Choices A and E) The fourth and sixth arches make up the cartilaginous structures of the larynx, including the cricoid and thyroid cartilages.

(Choice B) The glossopharyngeal nerve (CN IX) is derived from the third pharyngeal arch. Dysfunction may lead to impaired taste perception and an absent gag reflex.

(Choice C) The hyoid bone at the base of the mandible is derived from 2 pharyngeal arches. The lesser horn of the hyoid is derived from the second arch, and the greater horn of the hyoid is derived from the third arch.

(Choice F) The vagus nerve (CN X) is derived from the fourth and sixth arches. Dysfunction results in laryngeal and pharyngeal paralysis and autonomic dysfunction (eg, esophageal motility, gastric acid secretion, heart rate variability).

Educational objective:
The development of derivatives of the first (eg, trigeminal nerve, mandible, maxilla, zygoma, incus, malleus) and second (eg, facial nerve, stapes, styloid process, lesser horn of hyoid) pharyngeal arches can be disrupted in genetic disorders (eg, Treacher-Collins syndrome), resulting in hypoplasia of the mandibular and zygomatic bones.

References

- First and second brachial arch syndromes: multimodality approach

(CN).

The **first pharyngeal arch** is associated with the trigeminal nerve (CN V). Its bony derivatives include the **maxilla, zygoma, mandible, incus,** and **malleus**; its muscular derivatives include the muscles of mastication (eg, masseter, temporalis). The **second pharyngeal arch** is associated with the facial nerve (CN VII) and gives rise to the **styloid process of the temporal bone, lesser horn of the hyoid,** and **stapes**. Muscular derivatives of the second arch include the muscles of facial expression.

This neonate's presentation is consistent with **Treacher-Collins syndrome** (TCS), a genetic disorder resulting in the abnormal development of the first and second pharyngeal arches. The craniofacial abnormalities (eg, mandibular, maxillary, and zygomatic bone hypoplasia) often result in airway compromise and feeding difficulties. In addition, absent or abnormal ossicles (eg, incus, malleus, stapes) lead to profound conductive hearing loss.

(Choices A and E) The fourth and sixth arches make up the cartilaginous structures of the larynx, including the cricoid and thyroid cartilages.

(Choice B) The glossopharyngeal nerve (CN IX) is derived from the third pharyngeal arch. Dysfunction may lead to impaired taste perception and an absent gag reflex.

(Choice C) The hyoid bone at the base of the mandible is derived from 2 pharyngeal arches. The lesser horn of the hyoid is derived from the second arch, and the greater horn of the hyoid is derived from the third arch.

(Choice F) The vagus nerve (CN X) is derived from the fourth and sixth arches. Dysfunction results in laryngeal and pharyngeal paralysis and autonomic dysfunction (eg, esophageal motility, gastric acid secretion, heart rate variability).

Educational objective:
The development of derivatives of the first (eg, trigeminal nerve, mandible, maxilla, zygoma, incus, malleus) and second (eg, facial nerve, stapes, styloid process, lesser horn of hyoid) pharyngeal arches can be disrupted in genetic disorders (eg, Treacher-Collins syndrome), resulting in hypoplasia of the mandibular and zygomatic bones.

References

- First and second brachial arch syndromes: multimodality approach
- Syndromes of the first and second branchial arches, part 2: syndromes.

A 5-year-old boy is brought to the office by his parents for evaluation of cyanosis with minimal exertion. The boy has had occasional episodes of "turning blue" that first began during infancy and are now occurring more frequently. During the episodes, the boy assumes a squatting position as it makes him "feel better." The family recently immigrated to the United States; the boy has never had a medical checkup prior to this visit. Physical examination reveals a prominent right ventricular impulse and a harsh systolic murmur. Which of the following embryological events is the most likely mechanism that caused this patient's condition?

A. Anomalous pulmonary venous return

B. Aortic arch constriction

C. Deviation of the infundibular septum

D. Endocardial cushion defect

E. Linear development of the aorticopulmonary septum

Submit

A 5-year-old boy is brought to the office by his parents for evaluation of cyanosis with minimal exertion. The boy has had occasional episodes of "turning blue" that first began during infancy and are now occurring more frequently. During the episodes, the boy assumes a squatting position as it makes him "feel better." The family recently immigrated to the United States; the boy has never had a medical checkup prior to this visit. Physical examination reveals a prominent right ventricular impulse and a harsh systolic murmur. Which of the following embryological events is the most likely mechanism that caused this patient's condition?

A. Anomalous pulmonary venous return (5%)

B. Aortic arch constriction (4%)

✓ C. Deviation of the infundibular septum (42%)

D. Endocardial cushion defect (34%)

E. Linear development of the aorticopulmonary septum (12%)

Omitted
Correct answer
C

42%
Answered correctly

02 secs
Time Spent

01/22/2020
Last Updated

Explanation

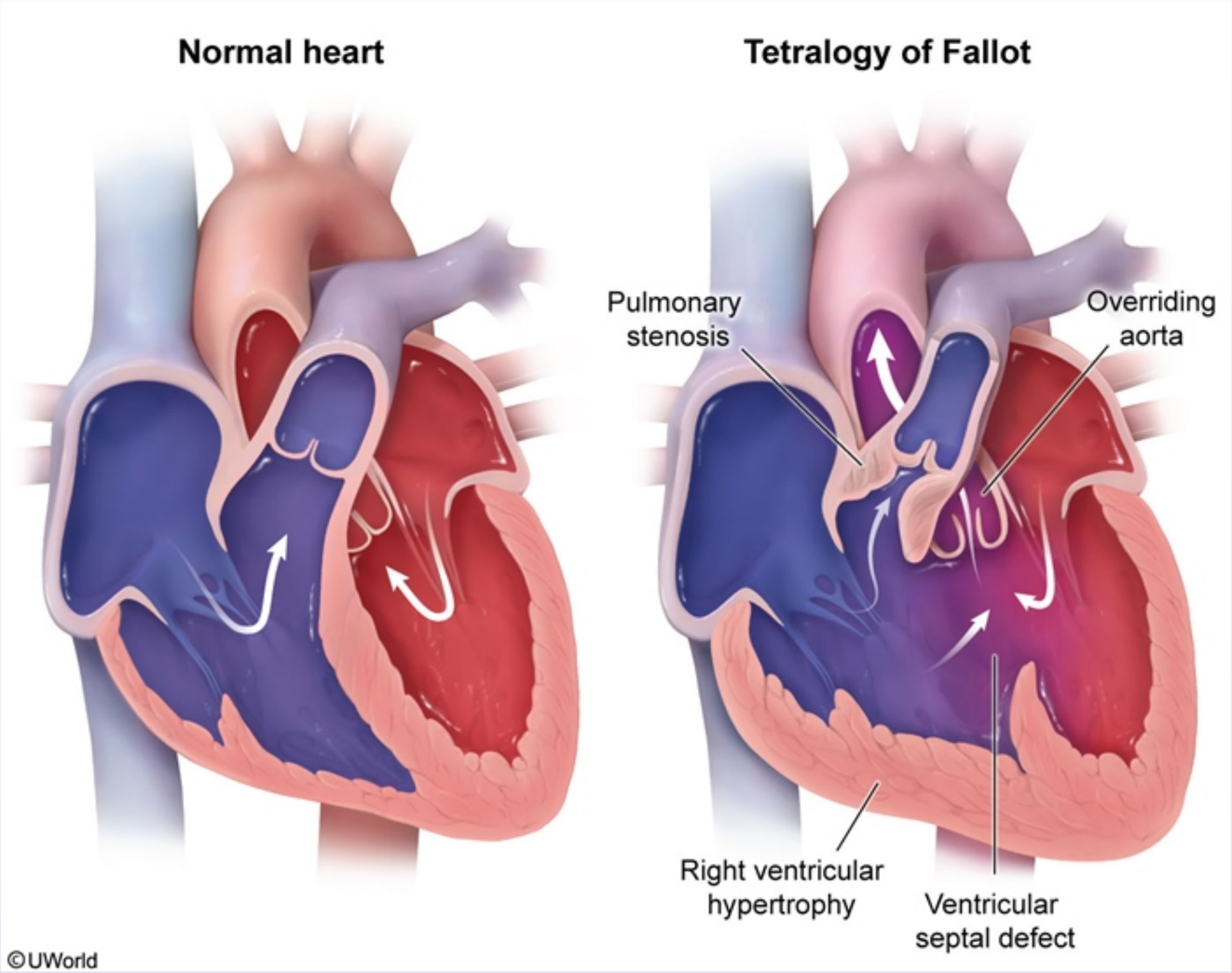

This patient's clinical presentation (**cyanotic spells** that improve with **squatting**, prominent right ventricular impulse, **systolic murmur**) is consistent with tetralogy of Fallot (TOF). Abnormal neural crest cell migration leads to anterior and cephalad deviation of the infundibular septum during embryologic development, resulting in a malaligned VSD and an overriding aorta. TOF is characterized by 4 distinct anatomic

This patient's clinical presentation (**cyanotic spells** that improve with **squatting**, prominent right ventricular impulse, **systolic murmur**) is consistent with tetralogy of Fallot (TOF). Abnormal neural crest cell migration leads to anterior and cephalad deviation of the infundibular septum during embryologic development, resulting in a malaligned VSD and an overriding aorta. TOF is characterized by 4 distinct anatomic abnormalities:

- Ventricular septal defect (VSD)
- Overriding aorta over the right and left ventricles
- Right ventricular outflow tract (RVOT) obstruction
- Right ventricular hypertrophy

Cyanosis occurs due to the presence of right-to-left shunt in patients with severe or worsening **RVOT obstruction**. The typical harsh, systolic ejection murmur over the mid-to-left upper sternal border is due to the presence of RVOT obstruction (subvalvular, pulmonary valve stenosis or supravalvular narrowing in the main pulmonary artery). Squatting increases the peripheral systemic vascular resistance (afterload) and decreases the degree of right-to-left shunting across the VSD, thereby improving cyanosis.

(Choice A) In anomalous pulmonary venous return, blood from both the pulmonary (oxygenated) and systemic (deoxygenated) venous systems flow into the right atrium, leading to right atrial and ventricular dilation. Patients also have obligatory right-to-left atrial shunting.

(Choice B) Aortic arch constriction results in coarctation of the aorta and is most commonly located just distal to the left subclavian artery (juxtaductal). Common manifestations include brachial-femoral pulse delay and blood pressure discrepancy between the upper and lower extremities.

(Choice D) Failed fusion of the superior and inferior endocardial cushions (eg, endocardial cushion defect) results in defects of the atrioventricular septum and valves (mitral and tricuspid valves). These typically manifest initially as atrial defects and/or VSDs with left-to-right shunting of blood. Over time, the increased right-sided blood flow leads to pulmonary hypertension with reversal of blood flow through the shunt and development of cyanosis (Eisenmenger syndrome). This patient has had cyanotic symptoms since birth that would not be expected with an isolated endocardial cushion defect.

(Choice E) Transposition of the great arteries results from linear, rather than spiral, development of the aorticopulmonary septum in utero.

Educational objective:

ejection murmur over the mid-to-left upper sternal border is due to the presence of RVOT obstruction (subvalvular, pulmonary valve stenosis or supravalvular narrowing in the main pulmonary artery). Squatting increases the peripheral systemic vascular resistance (afterload) and decreases the degree of right-to-left shunting across the VSD, thereby improving cyanosis.

(Choice A) In anomalous pulmonary venous return, blood from both the pulmonary (oxygenated) and systemic (deoxygenated) venous systems flow into the right atrium, leading to right atrial and ventricular dilation. Patients also have obligatory right-to-left atrial shunting.

(Choice B) Aortic arch constriction results in coarctation of the aorta and is most commonly located just distal to the left subclavian artery (juxtaductal). Common manifestations include brachial-femoral pulse delay and blood pressure discrepancy between the upper and lower extremities.

(Choice D) Failed fusion of the superior and inferior endocardial cushions (eg, endocardial cushion defect) results in defects of the atrioventricular septum and valves (mitral and tricuspid valves). These typically manifest initially as atrial defects and/or VSDs with left-to-right shunting of blood. Over time, the increased right-sided blood flow leads to pulmonary hypertension with reversal of blood flow through the shunt and development of cyanosis (Eisenmenger syndrome). This patient has had cyanotic symptoms since birth that would not be expected with an isolated endocardial cushion defect.

(Choice E) Transposition of the great arteries results from linear, rather than spiral, development of the aorticopulmonary septum in utero.

Educational objective:
Tetralogy of Fallot results from anterior and cephalad deviation of the infundibular septum during embryologic development, resulting in a malaligned ventricular septal defect (VSD) with an overriding aorta. As a result, the patient has right ventricular outflow obstruction (resulting in a systolic murmur) and squats to increase the peripheral systemic vascular resistance (afterload) and decrease right-to-left shunting across the VSD.

References

- Evaluation and management of heart murmurs in children.
- Tetralogy of Fallot.
- When 'blue babies' grow up: what you need to know about tetralogy of Fallot.

ejection murmur over the mid-to-left upper sternal border is due to the presence of RVOT obstruction (subvalvular, pulmonary valve stenosis or

Exhibit Display

Supracardiac total anomalous pulmonary venous return

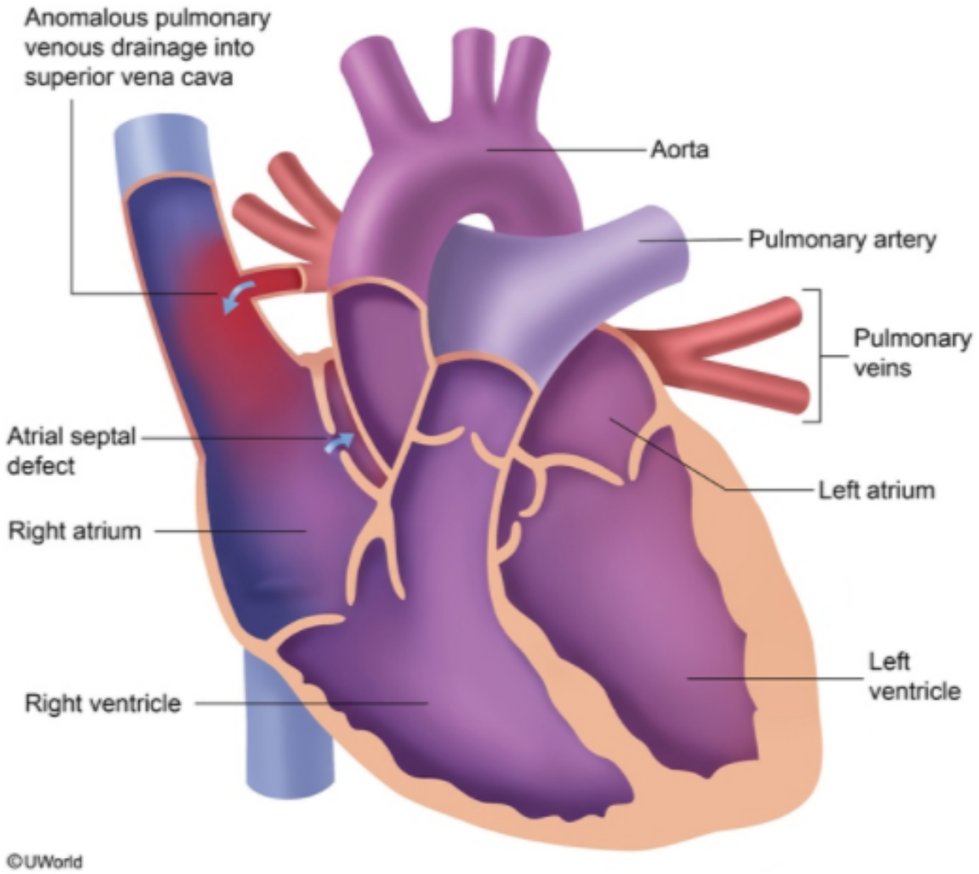

Zoom In | Zoom Out | Reset | Add To New Card | Existing Card

ejection murmur over the mid-to-left upper sternal border is due to the presence of RVOT obstruction (subvalvular, pulmonary valve stenosis or

Exhibit Display

Aortic coarctation
Patent ductus

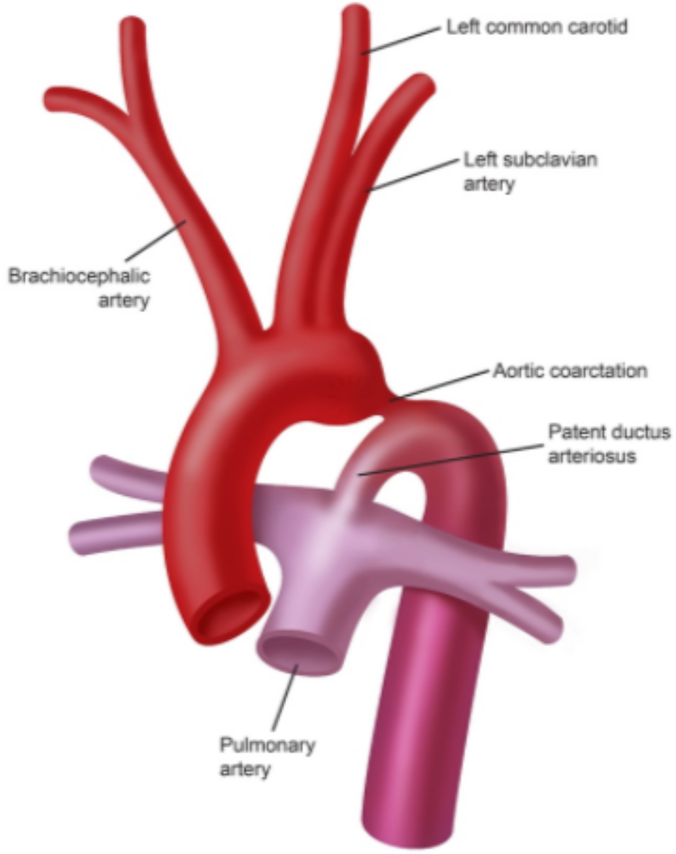

©UWorld

Zoom In | Zoom Out | Reset | Add To New Card | Existing Card

ejection murmur over the mid-to-left upper sternal border is due to the presence of RVOT obstruction (subvalvular, pulmonary valve stenosis or

Exhibit Display

Eisenmenger syndrome

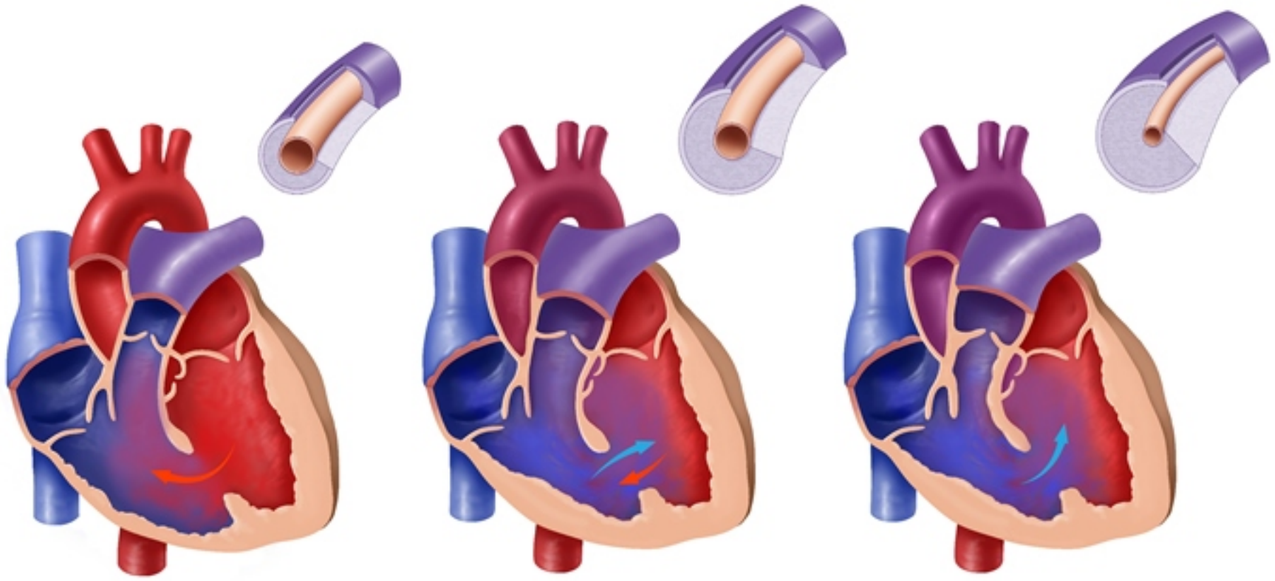

Atrial septal defect, ventricular septal defect, patent ductus arteriosus causes left-to-right shunt

Over time, pulmonary vascular resistance increases leading to bidirectional flow

Pulmonary vascular resistance continues to increase with eventual right-to-left shunt = **Eisenmenger syndrome**

©UWorld

Zoom In | Zoom Out | Reset | Add To New Card | Existing Card

Settings

1
2
3
4
5
6
7
8
9
10

Item 9 of 10
Question Id: 1705

Mark | Previous | Next | Full Screen | Tutorial | Lab Values | Notes | Calculator | Reverse Color | Text Zoom | Settings

ejection murmur over the mid-to-left upper sternal border is due to the presence of RVOT obstruction (subvalvular, pulmonary valve stenosis or

Exhibit Display

Zoom In | Zoom Out | Reset | Add To New Card | Existing Card

Block Time Remaining: 00:00:24
TUTOR

7 | Feedback | Suspend | End Block

ejection murmur over the mid-to-left upper sternal border is due to the presence of RVOT obstruction (subvalvular, pulmonary valve stenosis or

Exhibit Display

Transposition of the great vessels

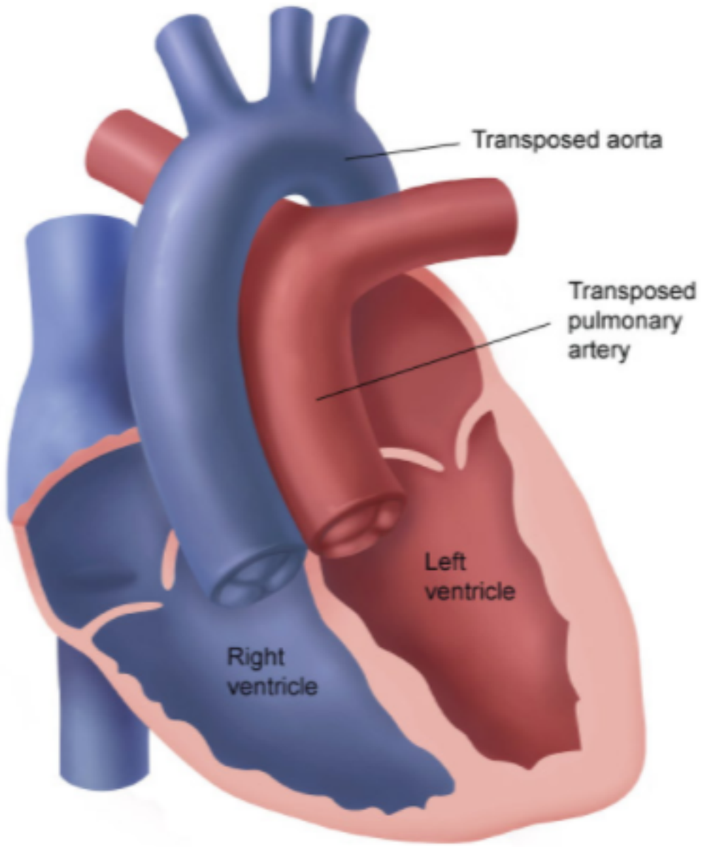

©UWorld

Zoom In | Zoom Out | Reset | Add To New Card | Existing Card

Settings

1
2
3
4
5
6
7
8
9
10

Item 10 of 10
Question Id: 202

Mark | Previous | Next | Full Screen | Tutorial | Lab Values | Notes | Calculator | Reverse Color | Text Zoom | Settings

A 37-year-old woman is brought to the emergency department after developing sudden-onset right arm weakness and difficulty speaking. She has no significant medical history but takes oral contraceptives. Examination shows decreased right upper extremity strength and expressive aphasia. Cardiac auscultation is normal. MRI of the brain reveals acute infarction in the left frontal lobe. Further evaluation to determine an etiology is performed. During echocardiogram, agitated normal saline is injected into a peripheral vein and bubbles are seen passing into the left side of the heart. Which of the following is the most likely cause of the observed finding in this patient?

A. Aplasia of the atrial septum secundum

B. Failure of the aorticopulmonary septum to develop

C. Incomplete closure of the interventricular foramen

D. Incomplete fusion of atrial septum primum and secundum

E. Persistent channel between aorta and pulmonary artery

Submit

Block Time Remaining: 00:00:25
TUTOR

4 | Feedback | Suspend | End Block

A 37-year-old woman is brought to the emergency department after developing sudden-onset right arm weakness and difficulty speaking. She has no significant medical history but takes oral contraceptives. Examination shows decreased right upper extremity strength and expressive aphasia. Cardiac auscultation is normal. MRI of the brain reveals acute infarction in the left frontal lobe. Further evaluation to determine an etiology is performed. During echocardiogram, agitated normal saline is injected into a peripheral vein and bubbles are seen passing into the left side of the heart. Which of the following is the most likely cause of the observed finding in this patient?

A. Aplasia of the atrial septum secundum (9%)

B. Failure of the aorticopulmonary septum to develop (3%)

C. Incomplete closure of the interventricular foramen (16%)

✓ D. Incomplete fusion of atrial septum primum and secundum (66%)

E. Persistent channel between aorta and pulmonary artery (4%)

Omitted
Correct answer
D

66%
Answered correctly

03 secs
Time Spent

03/19/2020
Last Updated

Explanation

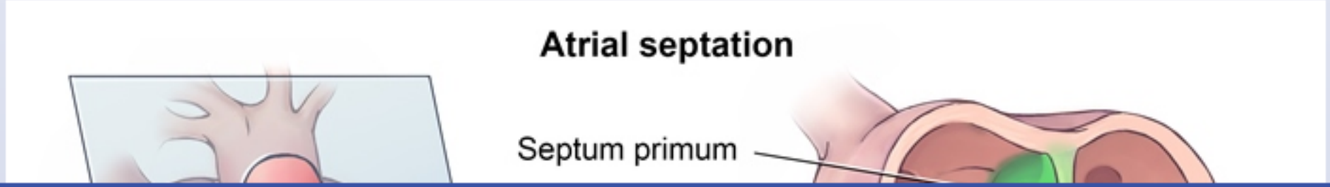

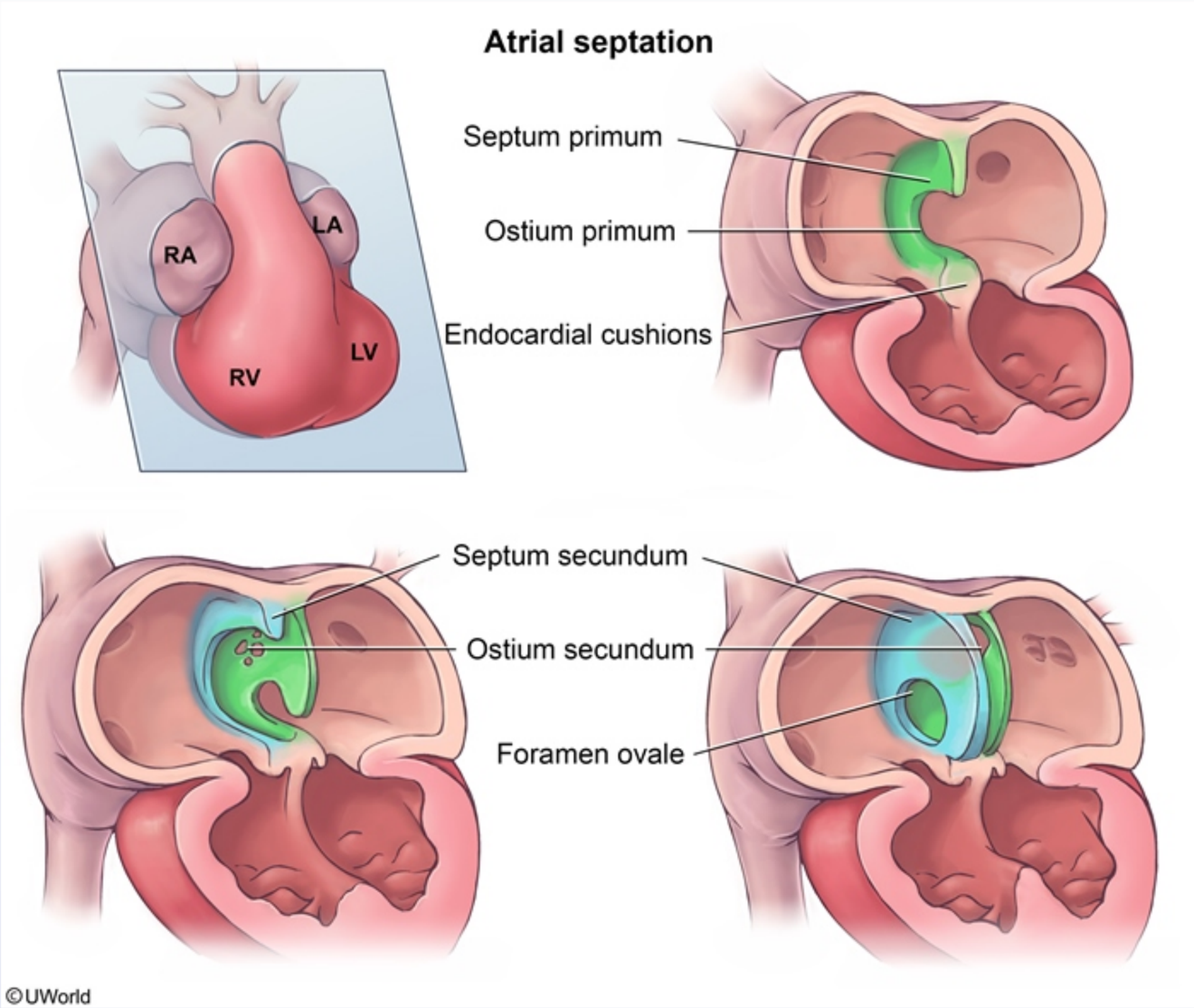

This young patient had a **cryptogenic stroke**, which is evaluated with echocardiography with a "bubble study" to identify right-to-left intracardiac

©UWorld

This young patient had a **cryptogenic stroke**, which is evaluated with echocardiography with a "bubble study" to identify right-to-left intracardiac shunts. This study is performed by injecting agitated normal saline intravenously and observing for microbubbles in the left heart. Shunt detection is improved by having the patient release a sustained Valsalva maneuver, which increases right atrial pressure. Cryptogenic stroke is frequently associated with atrial septal abnormalities such as **patent foramen ovale** (PFO) and atrial septal defect (ASD).

During fetal development, the foramen ovale shunts oxygenated fetal blood across from the right to the left atrium. After delivery, umbilical cord clamping and decreased pulmonary vascular resistance lower right atrial pressure and raise left atrial pressure. This pushes the **septum primum** against the **septum secundum**, closing the foramen ovale. Over time, fibrosis and tissue remodeling fuse the flap closed. **Incomplete fusion** occurs in approximately 25% of normal adults, resulting in a PFO.

PFO usually remains functionally closed and asymptomatic after birth as left atrial pressure is greater than right atrial pressure. However, conditions that raise right atrial pressure above left atrial pressure (eg, Valsalva release) produce a transient right-to-left shunt across the PFO. This is particularly concerning in patients with hypercoagulability (eg, oral contraceptive use) as they are at increased risk for venous thrombosis and **paradoxical brain embolism**. Chronically elevated right heart pressure (eg, Eisenmenger syndrome) is not necessary for paradoxical embolism.

(Choice A) ASD results from aplasia of the septum primum or septum secundum during development. Although ASD may lead to paradoxical embolism, it is much less common than PFO and characterized by fixed splitting of S2. Unrepaired ASDs may lead to heart failure, pulmonary hypertension, or Eisenmenger syndrome.

(Choice B) Incomplete development of the aorticopulmonary septum results in truncus arteriosus, which causes cyanosis in newborns and requires early surgical repair.

(Choice C) Incomplete closure of the interventricular foramen results in ventricular septal defect (VSD), which causes a holosystolic murmur at the lower left sternal border. Large VSDs can cause significant left-to-right shunting, leading to heart failure in infancy; however, VSDs infrequently lead to paradoxical embolism.

(Choice E) The ductus arteriosus functionally closes within 24 hours after delivery. Persistent patent ductus arteriosus causes a continuous murmur and may eventually result in heart failure, pulmonary hypertension, or Eisenmenger syndrome.

and **paradoxical brain embolism**. Chronically elevated right heart pressure (eg, Eisenmenger syndrome) is not necessary for paradoxical embolism.

(Choice A) ASD results from aplasia of the septum primum or septum secundum during development. Although ASD may lead to paradoxical embolism, it is much less common than PFO and characterized by fixed splitting of S2. Unrepaired ASDs may lead to heart failure, pulmonary hypertension, or Eisenmenger syndrome.

(Choice B) Incomplete development of the aorticopulmonary septum results in truncus arteriosus, which causes cyanosis in newborns and requires early surgical repair.

(Choice C) Incomplete closure of the interventricular foramen results in ventricular septal defect (VSD), which causes a holosystolic murmur at the lower left sternal border. Large VSDs can cause significant left-to-right shunting, leading to heart failure in infancy; however, VSDs infrequently lead to paradoxical embolism.

(Choice E) The ductus arteriosus functionally closes within 24 hours after delivery. Persistent patent ductus arteriosus causes a continuous murmur and may eventually result in heart failure, pulmonary hypertension, or Eisenmenger syndrome.

Educational objective:
The foramen ovale is patent in approximately 25% of normal adults. Although the foramen ovale usually remains functionally closed, transient increases of right atrial pressure above left atrial pressure can produce a right-to-left shunt, leading to paradoxical embolism of venous clots into the arterial circulation.

References

- Contemporary approach to paradoxical embolism.
- Patent foramen ovale.

Embryology	Cardiovascular System	Atrial septal defect
Subject	System	Topic

Copyright © UWorld. All rights reserved.

and **paradoxical brain embolism**. Chronically elevated right heart pressure (eg, Eisenmenger syndrome) is not necessary for paradoxical

Exhibit Display

Truncus arteriosus

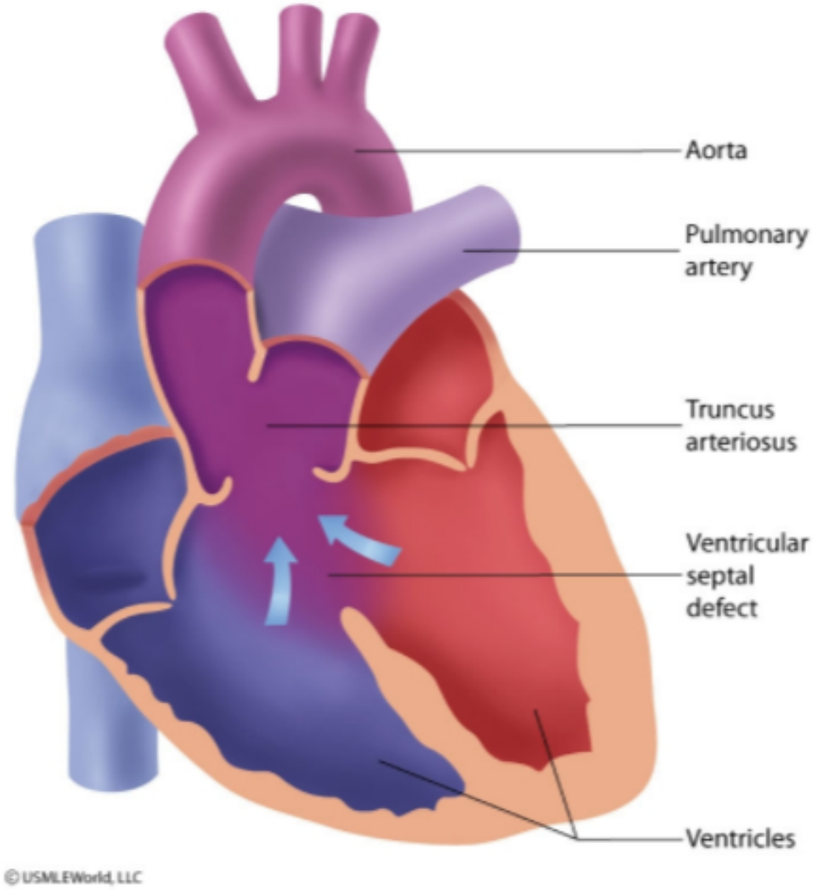

Zoom In | Zoom Out | Reset | Add To New Card | Existing Card

and **paradoxical brain embolism**. Chronically elevated right heart pressure (eg, Eisenmenger syndrome) is not necessary for paradoxical

Exhibit Display

Ventricular septal defect

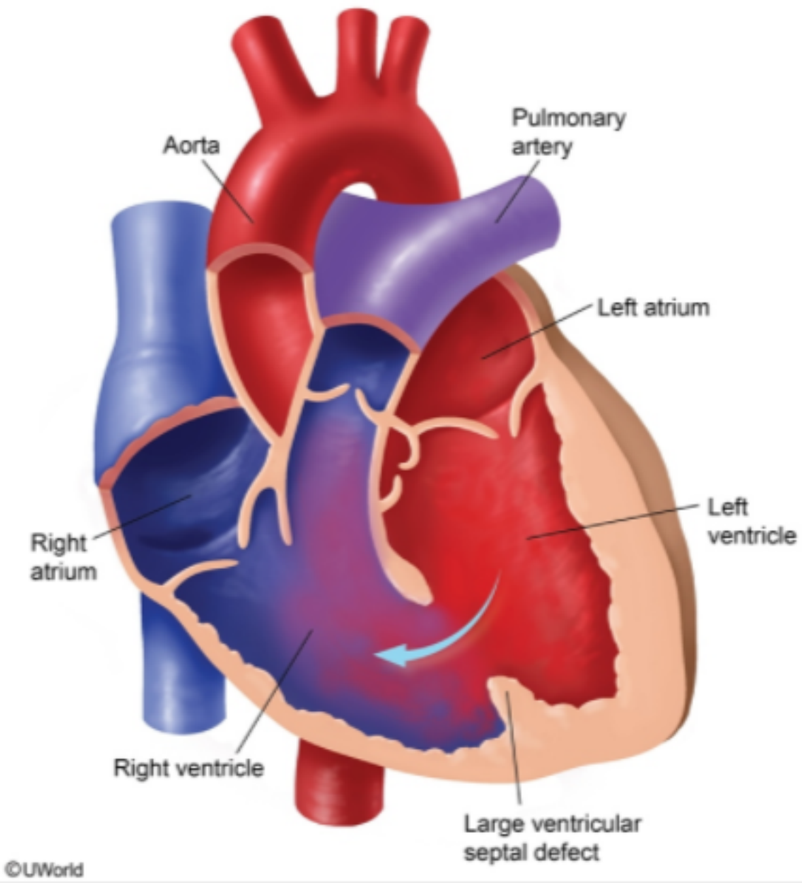

Zoom In | Zoom Out | Reset | Add To New Card | Existing Card

and **paradoxical brain embolism**. Chronically elevated right heart pressure (eg, Eisenmenger syndrome) is not necessary for paradoxical

Exhibit Display

Patent ductus arteriosus

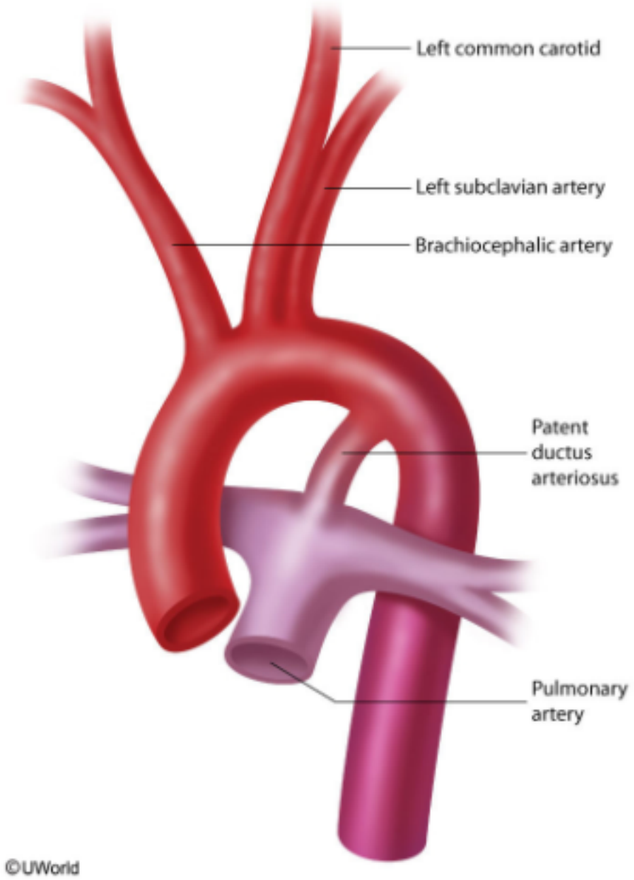

Zoom In | Zoom Out | Reset | Add To New Card | Existing Card